A 17-year-old boy is brought to the emergency department due to a lower extremity injury. The patient was playing football with his friends when he was tackled roughly and "felt something snap" in his right leg. He avoids bearing weight on the right foot. Examination shows a large contusion with point tenderness at the proximal lateral right leg. An x-ray of the leg is shown in the exhibit. Which of the following would most likely be found on physical examination?

A. Loss of inversion of the foot

B. Loss of plantar flexion of the foot

C. Loss of sensation at the dorsum of the foot

D. Loss of sensation at the medial aspect of the leg

E. Loss of sensation at the sole of the foot

Submit

A 17-year-old boy is brought to the emergency department due to a lower extremity injury. The patient was playing football with his friends when he was tackled roughly and "felt something snap" in his right leg. He avoids bearing weight on the right foot. Examination shows a large contusion with point tenderness at the proximal lateral right leg. An x-ray of the leg is shown in the exhibit. Which of the following would most likely be found on physical examination?

- A. Loss of inversion of the foot (7%)
- B. Loss of plantar flexion of the foot (12%)
- ✓ C. Loss of sensation at the dorsum of the foot (65%)
- D. Loss of sensation at the medial aspect of the leg (8%)
- E. Loss of sensation at the sole of the foot (5%)

Omitted
Correct answer
C

65%
Answered correctly

03 secs
Time Spent

02/03/2020
Last Updated

Explanation

Common peroneal nerve anatomy with fibular fracture

Common peroneal nerve anatomy with fibular fracture

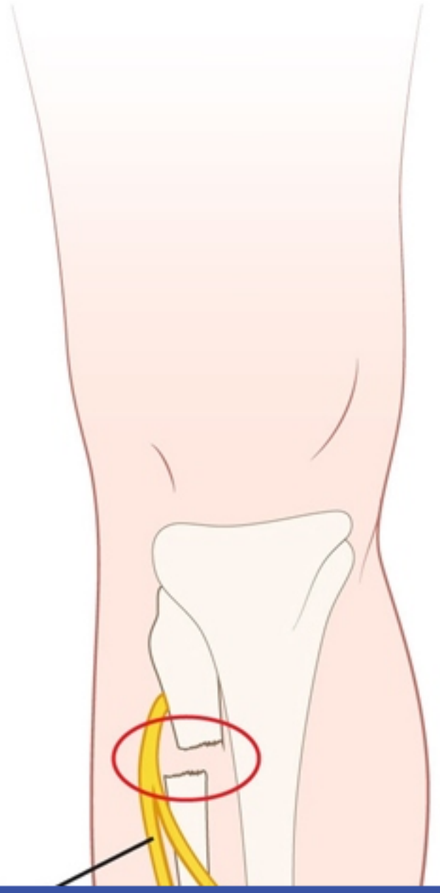

1
2
3
4
5
6
7
8
9
10
11
12
13
14
15
16
17
18
19
20
21
22
23
24
25
26
27
28
29
30
31

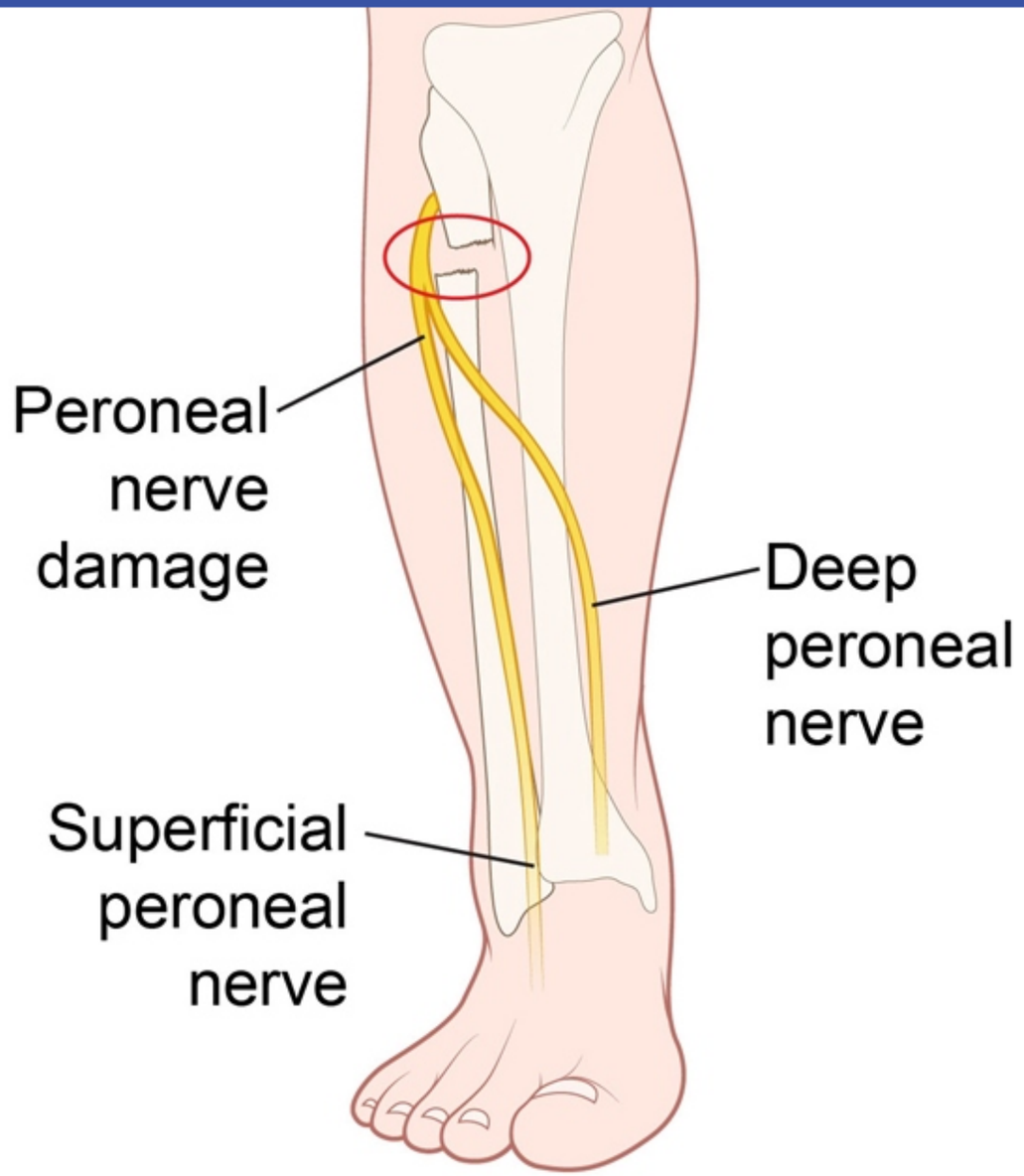

The sciatic nerve branches into the **common peroneal (fibular) nerve** and the tibial nerve posteriorly in the thigh just proximal to the popliteal fossa. After coursing around the neck of the fibula, the common peroneal nerve divides into superficial and deep branches. The superficial branch innervates the muscles of the lateral compartment of the leg, which function primarily to **evert** the foot. The deep peroneal nerve innervates the anterior compartment of the leg, whose muscles act mainly as **dorsiflexors** of the foot and toes. The superficial peroneal nerve provides sensory innervation to the dorsum of the foot. The deep peroneal nerve provides sensory innervation to the region between the first and second digits of the foot.

This patient has a fracture of the **neck of the fibula**. The common peroneal nerve is the most frequently injured nerve in the leg due to its superficial location as it courses laterally around the neck of the fibula. Injury to the common peroneal nerve from a proximal fibula fracture would cause **loss of dorsal foot sensation** as well as impaired dorsiflexion and eversion resulting in **foot drop**.

(Choice A) The tibialis posterior (innervated by tibial nerve) is the major muscle involved in foot inversion. The tibialis anterior (innervated by common peroneal nerve) is less important, and patients with peroneal nerve injuries usually have normal foot inversion.

(Choices B and E) The tibial nerve courses through the popliteal fossa and innervates the skin of the posterior calf, lateral foot, and sole; tissues of the knee joint; and muscles providing plantar flexion and inversion (eg, gastrocnemius, soleus, tibialis posterior). Injury to the tibial nerve would cause weakened plantar flexion and inversion of the foot as well as decreased sensation at the sole of the foot.

(Choice D) Loss of sensation at the medial aspect of the leg would result from a lesion of the saphenous nerve, the largest pure sensory branch of the femoral nerve.

Educational objective:
The common peroneal nerve is vulnerable to injury where it courses around the neck of the fibula. Fibular neck fractures can injure this nerve, causing weakness of dorsiflexion (deep peroneal nerve) and eversion (superficial peroneal nerve) of the foot as well as loss of sensation over the dorsum of the foot.

The sciatic nerve branches into the **common peroneal (fibular) nerve** and the tibial nerve posteriorly in the thigh just proximal to the popliteal fossa. After coursing around the neck of the fibula, the common peroneal nerve divides into superficial and deep branches. The superficial branch innervates the muscles of the lateral compartment of the leg, which function primarily to **evert** the foot. The deep peroneal nerve innervates the anterior compartment of the leg, whose muscles act mainly as **dorsiflexors** of the foot and toes. The superficial peroneal nerve provides sensory innervation to the dorsum of the foot. The deep peroneal nerve provides sensory innervation to the region between the first and second digits of the foot.

This patient has a fracture of the **neck of the fibula**. The common peroneal nerve is the most frequently injured nerve in the leg due to its superficial location as it courses laterally around the neck of the fibula. Injury to the common peroneal nerve from a proximal fibula fracture would cause **loss of dorsal foot sensation** as well as impaired dorsiflexion and eversion resulting in **foot drop**.

(Choice A) The tibialis posterior (innervated by tibial nerve) is the major muscle involved in foot inversion. The tibialis anterior (innervated by common peroneal nerve) is less important, and patients with peroneal nerve injuries usually have normal foot inversion.

(Choices B and E) The tibial nerve courses through the popliteal fossa and innervates the skin of the posterior calf, lateral foot, and sole; tissues of the knee joint; and muscles providing plantar flexion and inversion (eg, gastrocnemius, soleus, tibialis posterior). Injury to the tibial nerve would cause weakened plantar flexion and inversion of the foot as well as decreased sensation at the sole of the foot.

(Choice D) Loss of sensation at the medial aspect of the leg would result from a lesion of the saphenous nerve, the largest pure sensory branch of the femoral nerve.

Educational objective:
The common peroneal nerve is vulnerable to injury where it courses around the neck of the fibula. Fibular neck fractures can injure this nerve, causing weakness of dorsiflexion (deep peroneal nerve) and eversion (superficial peroneal nerve) of the foot as well as loss of sensation over the dorsum of the foot.

Anatomy	Rheumatology/Orthopedics & Sports	Peroneal neuropathy
Subject	System	Topic

Copyright © UWorld. All rights reserved.

The sciatic nerve branches into the **common peroneal (fibular) nerve** and the tibial nerve posteriorly in the thigh just proximal to the popliteal

Exhibit Display

Zoom In | Zoom Out | Reset | Add To New Card | Existing Card

The sciatic nerve branches into the **common peroneal (fibular) nerve** and the tibial nerve posteriorly in the thigh just proximal to the popliteal

Exhibit Display

Nerve	Motor function	Region of sensory loss with neuropathy
Tibial nerve	Foot plantar flexion & inversion, toe flexion	

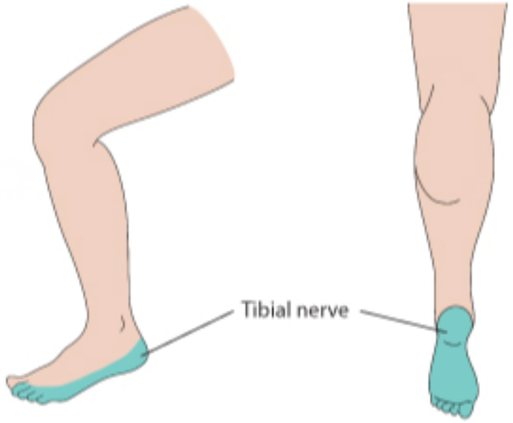

©UWorld

Zoom In | Zoom Out | Reset | Add To New Card | Existing Card

The sciatic nerve branches into the **common peroneal (fibular) nerve** and the tibial nerve posteriorly in the thigh just proximal to the popliteal

Exhibit Display

Anterior cutaneous nerves of leg

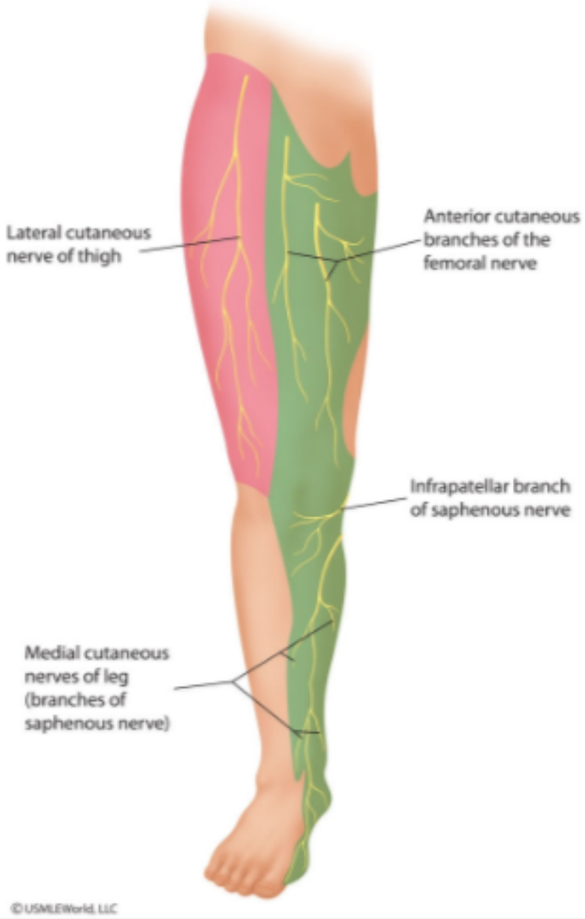

Zoom In | Zoom Out | Reset | Add To New Card | Existing Card

A 13-year-old boy is brought to the office due to right knee pain. Several weeks ago, he developed mild anterior knee pain that has gradually worsened and now causes him to limp. The pain has significantly limited his participation in basketball practice. It is relieved by rest and can be reproduced when the patient straightens out his right knee while seated in a chair. Further evaluation reveals an avulsion fracture affecting a developing secondary ossification center due to muscle overuse. Which of the following structures is most likely involved in this patient's disease process?

A. Anterior intercondylar area

B. Anteromedial tibia shaft

C. Fibular head

D. Medial condyle of tibia

E. Tibial tubercle

Submit

A 13-year-old boy is brought to the office due to right knee pain. Several weeks ago, he developed mild anterior knee pain that has gradually worsened and now causes him to limp. The pain has significantly limited his participation in basketball practice. It is relieved by rest and can be reproduced when the patient straightens out his right knee while seated in a chair. Further evaluation reveals an avulsion fracture affecting a developing secondary ossification center due to muscle overuse. Which of the following structures is most likely involved in this patient's disease process?

- A. Anterior intercondylar area (10%)
- B. Anteromedial tibia shaft (11%)
- C. Fibular head (8%)
- D. Medial condyle of tibia (11%)
- ✓ E. Tibial tubercle (57%)

Omitted
Correct answer
E

57%
Answered correctly

02 secs
Time Spent

02/09/2020
Last Updated

Explanation

Anterior knee anatomy

Anterior knee anatomy

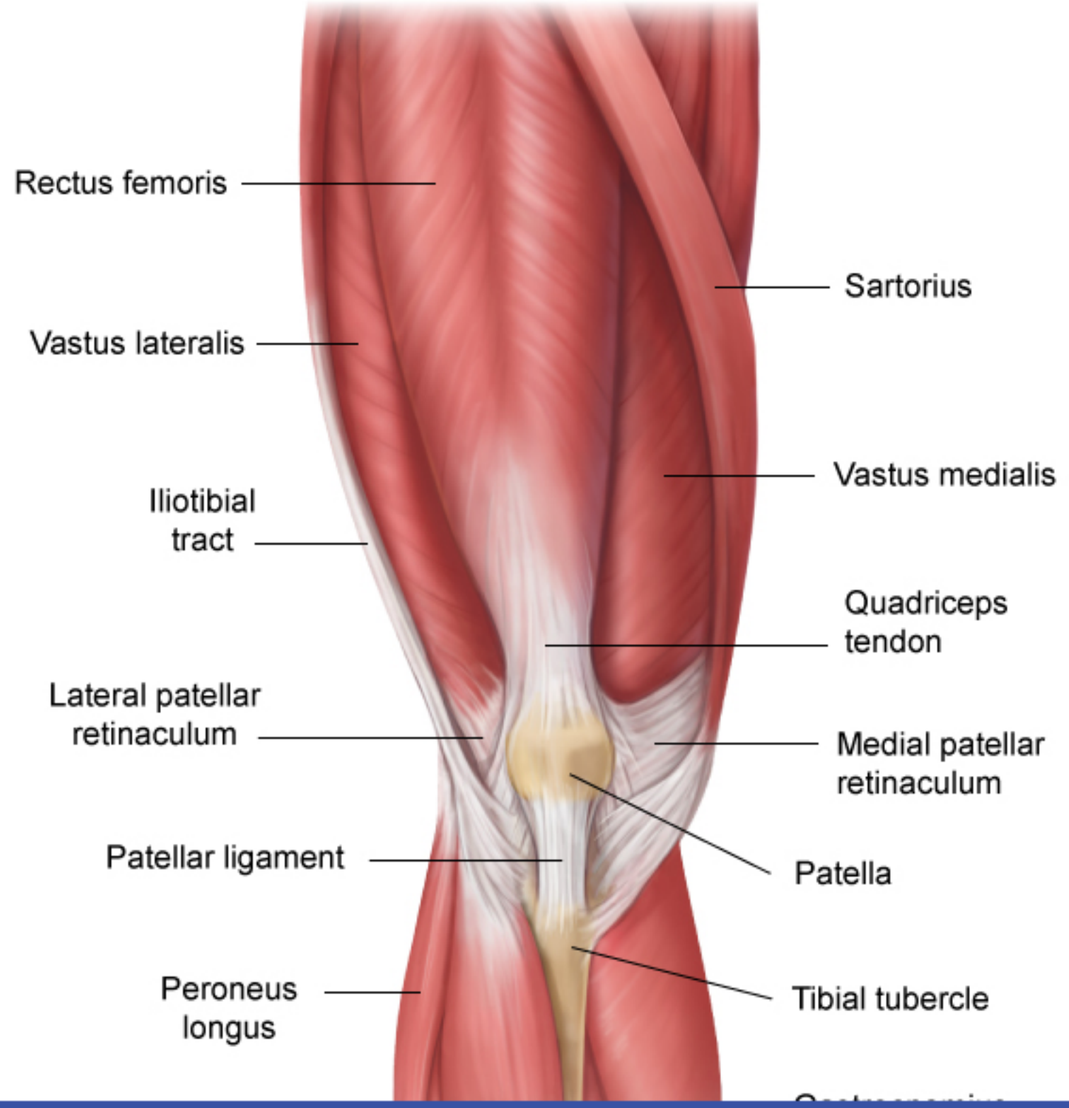

1
2
3
4
5
6
7
8
9
10
11
12
13
14
15
16
17
18
19
20
21
22
23
24
25
26
27
28
29
30
31

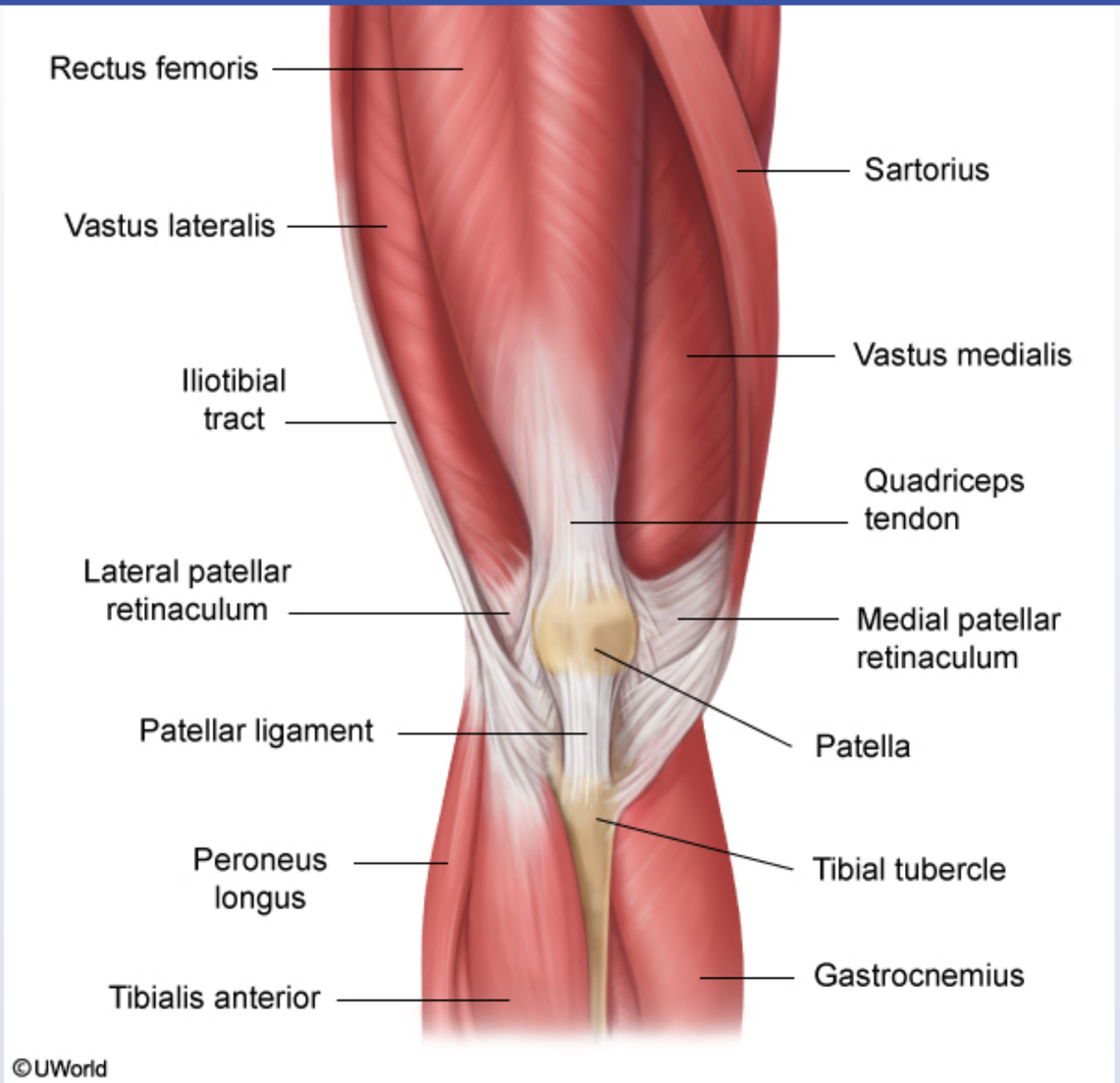

This patient likely has **Osgood-Schlatter disease** (OSD), a common cause of knee pain in **adolescent athletes** due to overuse of the quadriceps muscle group (ie, rectus femoris, vastus intermedius, vastus medialis, vastus lateralis). The quadriceps is responsible for leg extension at the

©UWorld

This patient likely has **Osgood-Schlatter disease** (OSD), a common cause of knee pain in **adolescent athletes** due to overuse of the quadriceps muscle group (ie, rectus femoris, vastus intermedius, vastus medialis, vastus lateralis). The quadriceps is responsible for leg extension at the knee and inserts into the **tibial tubercle** via the patellar ligament. The tubercle forms as a **secondary ossification center** (apophysis) of the tibia, and the cartilaginous nature of the developing tibial tuberosity in childhood makes it more prone to injury compared to the fully ossified bone in adults.

OSD most commonly occurs after a **growth spurt** due to increased tension in tendons and ligaments caused by the rapidly elongating bone. Repetitive quadriceps contraction (eg, sports activity) then results in chronic avulsion of the tibial tubercle. Clinical findings include tenderness and swelling at the tibial tubercle and pain that **worsens with knee extension** (eg, jumping). Imaging frequently shows an elevated and fragmented tibial tubercle.

(Choice A) The anterior intercondylar area (ie, fossa) is the space between the medial and lateral condyles of the tibia. The anterior cruciate ligament (ACL) attaches at this specific location and is crucial for knee stabilization. ACL injury typically results from sudden deceleration with direction change and presents as acute knee pain, swelling, and instability that prevents weight-bearing.

(Choice B) The sartorius muscle is the longest muscle in the body. It originates from the anterior superior iliac spine and inserts with the pes anserinus onto the anteromedial tibia shaft near the tibial tuberosity. Pes anserinus bursitis commonly occurs in runners and causes anteromedial knee pain.

(Choices C and D) The tendon of the biceps femoris (part of the hamstrings) inserts at the styloid process of the head of the fibula. The medial condyle of the tibia is the insertion site for the semimembranous muscle, the most medial of the hamstring muscles. The hamstring muscles are involved in knee flexion and hip extension.

Educational objective:
The quadriceps muscle group is connected to the patella, which is attached to the tibial tubercle by the patellar ligament. Repetitive quadriceps contraction (eg, jumping) in adolescents can result in Osgood-Schlatter disease, which is characterized by focal anterior knee pain and swelling due to chronic avulsion of the tibial tubercle.

References

- Precise risk factors for Osgood-Schlatter disease.

OSD most commonly occurs after a **growth spurt** due to increased tension in tendons and ligaments caused by the rapidly elongating bone. Repetitive quadriceps contraction (eg, sports activity) then results in chronic avulsion of the tibial tubercle. Clinical findings include tenderness and swelling at the tibial tubercle and pain that **worsens with knee extension** (eg, jumping). Imaging frequently shows an elevated and fragmented tibial tubercle.

(Choice A) The anterior intercondylar area (ie, fossa) is the space between the medial and lateral condyles of the tibia. The anterior cruciate ligament (ACL) attaches at this specific location and is crucial for knee stabilization. ACL injury typically results from sudden deceleration with direction change and presents as acute knee pain, swelling, and instability that prevents weight-bearing.

(Choice B) The sartorius muscle is the longest muscle in the body. It originates from the anterior superior iliac spine and inserts with the pes anserinus onto the anteromedial tibia shaft near the tibial tuberosity. Pes anserinus bursitis commonly occurs in runners and causes anteromedial knee pain.

(Choices C and D) The tendon of the biceps femoris (part of the hamstrings) inserts at the styloid process of the head of the fibula. The medial condyle of the tibia is the insertion site for the semimembranous muscle, the most medial of the hamstring muscles. The hamstring muscles are involved in knee flexion and hip extension.

Educational objective:
The quadriceps muscle group is connected to the patella, which is attached to the tibial tubercle by the patellar ligament. Repetitive quadriceps contraction (eg, jumping) in adolescents can result in Osgood-Schlatter disease, which is characterized by focal anterior knee pain and swelling due to chronic avulsion of the tibial tubercle.

References

- Precise risk factors for Osgood-Schlatter disease.
- Osgood Schlatter syndrome.

Anatomy	Rheumatology/Orthopedics & Sports	Osgood schlatter disease
Subject	System	Topic

Copyright © UWorld. All rights reserved.

©UWorld

Exhibit Display

Osgood-Schlatter disease

©UWorld

Zoom In | Zoom Out | Reset | Add To New Card | Existing Card

- Precise risk factors for Osgood-Schlatter disease.

©UWorld

Exhibit Display

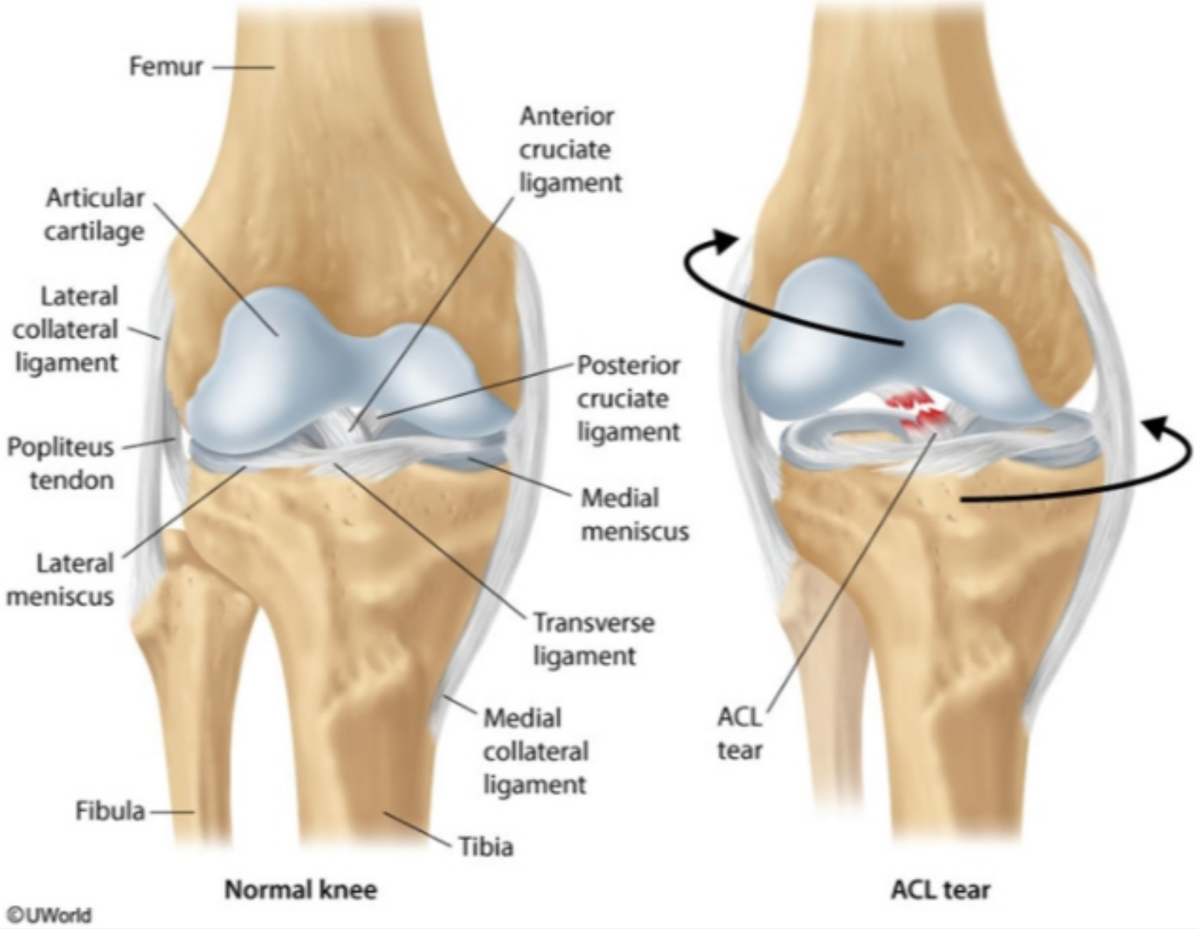

Zoom In | Zoom Out | Reset | Add To New Card | Existing Card

- Precise risk factors for Osgood-Schlatter disease.

©UWorld

Exhibit Display

Medial knee & pes anserinus

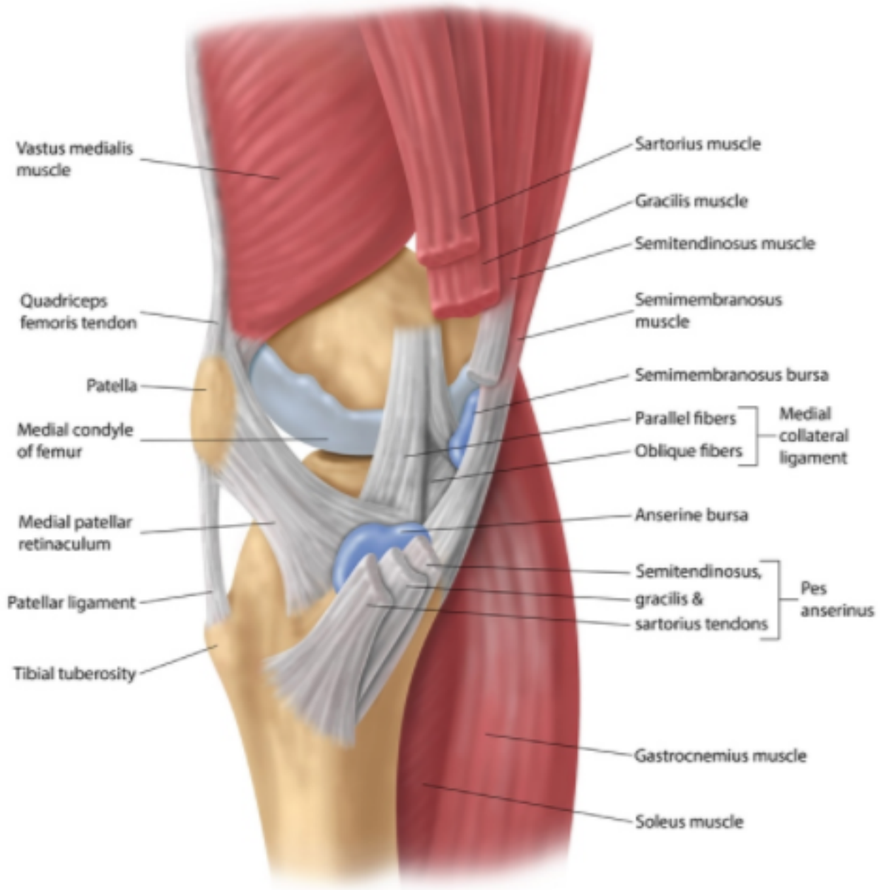

©UWorld

Zoom In | Zoom Out | Reset | Add To New Card | Existing Card

- Precise risk factors for Osgood-Schlatter disease.

OSD most commonly occurs after a **growth spurt** due to increased tension in tendons and ligaments caused by the rapidly elongating bone. Repetitive quadriceps contraction (eg, sports activity) then results in chronic avulsion of the tibial tubercle. Clinical findings include tenderness and swelling at the tibial tubercle and pain that **worsens with knee extension** (eg, jumping). Imaging frequently shows an elevated and fragmented tibial tubercle.

(Choice A) The anterior intercondylar area (ie, fossa) is the space between the medial and lateral condyles of the tibia. The anterior cruciate ligament (ACL) attaches at this specific location and is crucial for knee stabilization. ACL injury typically results from sudden deceleration with direction change and presents as acute knee pain, swelling, and instability that prevents weight-bearing.

(Choice B) The sartorius muscle is the longest muscle in the body. It originates from the anterior superior iliac spine and inserts with the pes anserinus onto the anteromedial tibia shaft near the tibial tuberosity. Pes anserinus bursitis commonly occurs in runners and causes anteromedial knee pain.

(Choices C and D) The tendon of the biceps femoris (part of the hamstrings) inserts at the styloid process of the head of the fibula. The medial condyle of the tibia is the insertion site for the semimembranous muscle, the most medial of the hamstring muscles. The hamstring muscles are involved in knee flexion and hip extension.

Educational objective:
The quadriceps muscle group is connected to the patella, which is attached to the tibial tubercle by the patellar ligament. Repetitive quadriceps contraction (eg, jumping) in adolescents can result in Osgood-Schlatter disease, which is characterized by focal anterior knee pain and swelling due to chronic avulsion of the tibial tubercle.

References

- Precise risk factors for Osgood-Schlatter disease.
- Osgood Schlatter syndrome.

Anatomy	Rheumatology/Orthopedics & Sports	Osgood schlatter disease
Subject	System	Topic

Copyright © UWorld. All rights reserved.

A 20-year-old college football quarterback is evaluated in the emergency department for acute right shoulder pain. One hour ago, the patient sustained a blow to the arm when tackled mid-throw during a championship game. On physical examination, there is flattening of the right deltoid muscle and insensitivity of the overlying skin to pinprick. Peripheral pulses in the upper extremities are intact. Which of the following injuries is most likely responsible for this patient's findings?

- A. Acromioclavicular joint subluxation
- B. Anterior dislocation of the humerus
- C. Clavicular fracture
- D. Fracture of the coracoid process
- E. Rotator cuff tear
- F. Spiral fracture of the midshaft humerus

Submit

A 20-year-old college football quarterback is evaluated in the emergency department for acute right shoulder pain. One hour ago, the patient sustained a blow to the arm when tackled mid-throw during a championship game. On physical examination, there is flattening of the right deltoid muscle and insensitivity of the overlying skin to pinprick. Peripheral pulses in the upper extremities are intact. Which of the following injuries is most likely responsible for this patient's findings?

- A. Acromioclavicular joint subluxation (10%)
- ✓ B. Anterior dislocation of the humerus (71%)
- C. Clavicular fracture (4%)
- D. Fracture of the coracoid process (4%)
- E. Rotator cuff tear (5%)
- F. Spiral fracture of the midshaft humerus (3%)

Omitted
Correct answer
B

71%
Answered correctly

02 secs
Time Spent

05/29/2020
Last Updated

Explanation

The glenohumeral joint is the most commonly dislocated joint in the body due to the shallow articulation between the humeral head and the glenoid fossa of the scapula. The shoulder may dislocate anteriorly, inferiorly, or posteriorly, but anterior dislocations are by far the most common. **Anterior dislocations** of the humerus classically follow a blow to an **externally rotated** and **abducted arm** (eg, throwing a football).

When the head of the humerus is displaced anteriorly, there is **flattening of the deltoid** prominence, protrusion of the acromion, and anterior axillary fullness (due to the humeral head's movement into this location). The axillary nerve is the nerve most commonly injured by anterior

The glenohumeral joint is the most commonly dislocated joint in the body due to the shallow articulation between the humeral head and the glenoid fossa of the scapula. The shoulder may dislocate anteriorly, inferiorly, or posteriorly, but anterior dislocations are by far the most common. **Anterior dislocations** of the humerus classically follow a blow to an **externally rotated** and **abducted arm** (eg, throwing a football).

When the head of the humerus is displaced anteriorly, there is **flattening of the deltoid** prominence, protrusion of the acromion, and anterior axillary fullness (due to the humeral head's movement into this location). The axillary nerve is the nerve most commonly injured by anterior shoulder dislocations. It innervates the **deltoid and teres minor** muscles and provides sensory innervation to the skin overlying the **lateral shoulder**.

(Choice A) Acromioclavicular joint subluxation typically results from a downward blow on the tip of the shoulder and produces swelling and upward displacement of the clavicle. It is not usually associated with specific nerve injuries/deficits.

(Choice C) Clavicular fractures usually occur following direct trauma to the clavicle. Most fractures are in the middle third of the clavicle and produce local swelling and tenderness. Associated neurovascular damage is rare.

(Choice D) Fracture of the coracoid process of the scapula is rare. Individuals who engage in shotgun- or rifle-related activities are most commonly affected.

(Choice E) Rotator cuff tears may occur during shoulder dislocation but do not cause nerve injury. The rotator cuff is made up of the subscapularis, supraspinatus, infraspinatus, and teres minor muscles/tendons.

(Choice F) A spiral fracture of the midshaft humerus may result from torsion produced during a fall on an outstretched hand. Patients present with swelling, bone crepitus, and ecchymoses of the arm. The radial nerve is commonly injured.

Educational objective:
Flattening of the deltoid muscle with acromial prominence after a shoulder injury suggests an anterior humerus dislocation. This injury most commonly results from a blow to an externally rotated and abducted arm. There is often associated axillary nerve injury, resulting in deltoid paralysis and loss of sensation over the lateral shoulder.

References

- Acute management of shoulder dislocations.
- Anterior shoulder dislocation

shoulder dislocations. It innervates the **deltoid and teres minor** muscles and provides sensory innervation to the skin overlying the **lateral shoulder**.

(Choice A) Acromioclavicular joint subluxation typically results from a downward blow on the tip of the shoulder and produces swelling and upward displacement of the clavicle. It is not usually associated with specific nerve injuries/deficits.

(Choice C) Clavicular fractures usually occur following direct trauma to the clavicle. Most fractures are in the middle third of the clavicle and produce local swelling and tenderness. Associated neurovascular damage is rare.

(Choice D) Fracture of the coracoid process of the scapula is rare. Individuals who engage in shotgun- or rifle-related activities are most commonly affected.

(Choice E) Rotator cuff tears may occur during shoulder dislocation but do not cause nerve injury. The rotator cuff is made up of the subscapularis, supraspinatus, infraspinatus, and teres minor muscles/tendons.

(Choice F) A spiral fracture of the midshaft humerus may result from torsion produced during a fall on an outstretched hand. Patients present with swelling, bone crepitus, and ecchymoses of the arm. The radial nerve is commonly injured.

Educational objective:
Flattening of the deltoid muscle with acromial prominence after a shoulder injury suggests an anterior humerus dislocation. This injury most commonly results from a blow to an externally rotated and abducted arm. There is often associated axillary nerve injury, resulting in deltoid paralysis and loss of sensation over the lateral shoulder.

References

- Acute management of shoulder dislocations.
- Anterior shoulder dislocation.

Anatomy	Rheumatology/Orthopedics & Sports	Shoulder dislocation
Subject	System	Topic

Copyright © UWorld. All rights reserved.

Exhibit Display

Important nerves in the arm

Nerve	Motor function	Region of sensory loss with neuropathy
Axillary nerve	Abduction of arm at shoulder beyond first 15 degrees	

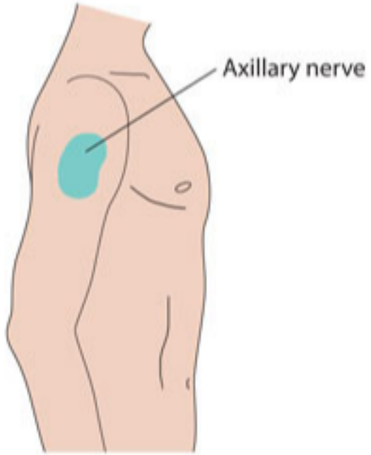

©UWorld

Zoom In | Zoom Out | Reset | Add To New Card | Existing Card

(Choice E) Rotator cuff tears may occur during shoulder dislocation but do not cause nerve injury. The rotator cuff is made up of the

A 53-year-old man comes to the office with a dull ache in his right shoulder. The pain is worse with movement and often interferes with his sleep. The patient cannot recall any traumatic events prior to the start of the pain but did experience increased discomfort after helping his daughter move into her college dorm room a week ago. His past medical history includes dyslipidemia and hypertension, for which he takes the appropriate medications. Physical examination reveals localized tenderness just below the acromion. The physician asks the patient to abduct his arms 90 degrees to the side and flex them 30 degrees forward with his thumbs pointing to the floor. She then applies downward force to his arms. This maneuver elicits pain in the patient's right shoulder and reveals right-sided weakness as compared to the left side. A tendon of which of the following muscles is most likely injured in this patient?

- A. Biceps brachii
- B. Deltoid
- C. Levator scapulae
- D. Serratus anterior
- E. Supraspinatus

Submit

A 53-year-old man comes to the office with a dull ache in his right shoulder. The pain is worse with movement and often interferes with his sleep. The patient cannot recall any traumatic events prior to the start of the pain but did experience increased discomfort after helping his daughter move into her college dorm room a week ago. His past medical history includes dyslipidemia and hypertension, for which he takes the appropriate medications. Physical examination reveals localized tenderness just below the acromion. The physician asks the patient to abduct his arms 90 degrees to the side and flex them 30 degrees forward with his thumbs pointing to the floor. She then applies downward force to his arms. This maneuver elicits pain in the patient's right shoulder and reveals right-sided weakness as compared to the left side. A tendon of which of the following muscles is most likely injured in this patient?

A. Biceps brachii (5%)
B. Deltoid (17%)
C. Levator scapulae (3%)
D. Serratus anterior (2%)
✓ E. Supraspinatus (69%)

Omitted
Correct answer
E

69%
Answered correctly

03 secs
Time Spent

04/18/2020
Last Updated

Explanation

Acromioclavicular joint

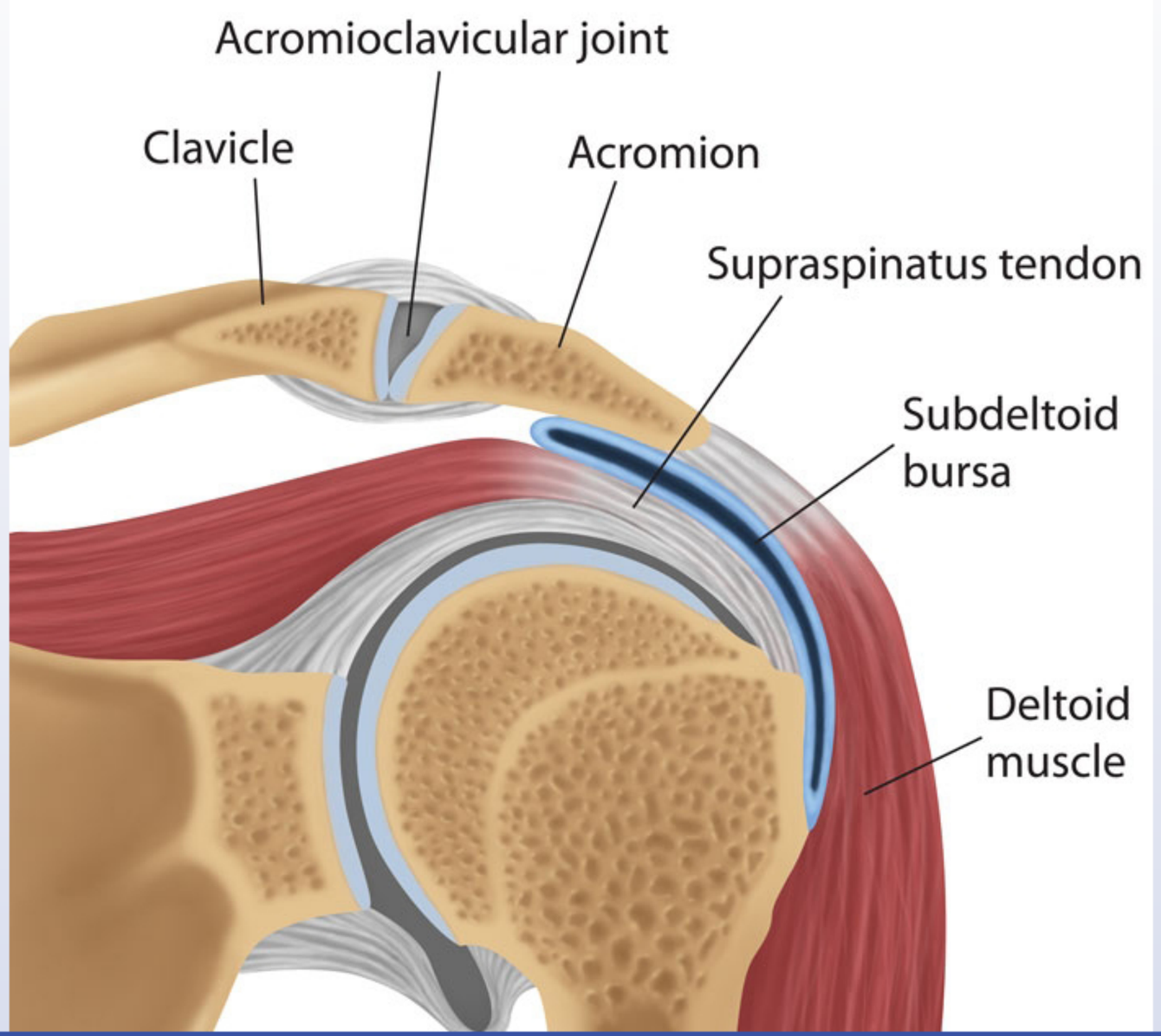
Acromioclavicular joint
Clavicle
Acromion
Supraspinatus tendon
Subdeltoid bursa
Deltoid muscle

The **rotator cuff** consists of the tendons of the **supraspinatus, infraspinatus, teres** minor, and **subscapularis** (**SITS**) and contributes to the stability and motion of the glenohumeral joint. During abduction of the humerus, the supraspinatus initiates movement through the first 10-15 degrees; subsequently, the deltoid provides the primary abductive force while the supraspinatus provides stability to the joint.

Of all the rotator cuff structures, the **supraspinatus tendon** is most commonly affected in rotator cuff syndrome. This tendon is vulnerable to chronic repeated trauma from **impingement** between the head of the humerus and the acromion during abduction. Inflammation and fibrosis can worsen the problem by increasing friction between the head of the humerus and the acromion, as well as causing inflammation of the subacromial bursa. On examination, the action of the supraspinatus can be isolated with the "empty-can" supraspinatus test: abduction of the humerus in parallel to the axis of the scapula (30 degrees forward flexion) while in full internal rotation (thumbs pointed to the floor).

(Choice A) The long head of the biceps brachii originates on the supraglenoid tubercle of the scapula and inserts on the radius. It primarily flexes and supinates the forearm, although it also contributes to shoulder flexion. Biceps tendonitis is characterized by tenderness at the bicipital groove (separates lesser and greater tubercles of the humerus).

(Choice B) The deltoid originates on the clavicle, the acromion, and the spine of the scapula; it inserts on the lateral humerus. Deltoid injuries are less common than supraspinatus injuries and usually manifest as sudden-onset shoulder pain after overloading the arm while in abduction.

(Choice C) The tendons of the levator scapulae insert on the superomedial border of the scapula and on the transverse processes of the C1 through C4 vertebrae. The levator scapulae does not contribute to the stability of the glenohumeral joint.

(Choice D) The serratus anterior originates on the lateral surfaces of the first 8 ribs and inserts on the scapula. Its primary action is to pull the scapula forward and rotate it to raise the glenoid. Injury to the long thoracic nerve causes paralysis of this muscle and "winging" of the scapula.

Educational objective:
The supraspinatus muscle assists in abduction of the arm and stabilization of the glenohumeral joint. The supraspinatus tendon is vulnerable to injury due to impingement between the acromion and the head of the humerus. Supraspinatus tendinopathy is the most common cause of rotator cuff syndrome.

References

- Chronic shoulder pain: part I. Evaluation and diagnosis.

Anatomy Rheumatology/Orthopedics & Sports Rotator cuff

1
2
3
4
5
6
7
8
9
10
11
12
13
14
15
16
17
18
19
20
21
22
23
24
25
26
27
28
29
30
31

A 26-year-old man comes to the emergency department due to fever, right flank pain, and difficulty walking for the past 3 days. A week ago, the patient was treated with cephalexin for bacterial folliculitis. He was diagnosed with type I diabetes mellitus 10 years ago and takes subcutaneous insulin. Temperature is 38.9° C (102° F). During the medical interview, the patient lies supine on the examination table with his right hip and knee flexed and the limb externally rotated. On physical examination, he resists passive extension of the limb due to worsening of the pain. This patient's pathological process most likely involves which of the following muscles?

A. Obturator externus

B. Psoas major

C. Quadratus lumborum

D. Rectus femoris

E. Transversus abdominis

Submit

1
2
3
4
5
6
7
8
9
10
11
12
13
14
15
16
17
18
19
20
21
22
23
24
25
26
27
28
29
30
31

A 26-year-old man comes to the emergency department due to fever, right flank pain, and difficulty walking for the past 3 days. A week ago, the patient was treated with cephalexin for bacterial folliculitis. He was diagnosed with type I diabetes mellitus 10 years ago and takes subcutaneous insulin. Temperature is 38.9° C (102° F). During the medical interview, the patient lies supine on the examination table with his right hip and knee flexed and the limb externally rotated. On physical examination, he resists passive extension of the limb due to worsening of the pain. This patient's pathological process most likely involves which of the following muscles?

A. Obturator externus (9%)
✓ B. Psoas major (68%)
C. Quadratus lumborum (8%)
D. Rectus femoris (12%)
E. Transversus abdominis (1%)

Omitted
Correct answer
B

68%
Answered correctly

02 secs
Time Spent

05/12/2020
Last Updated

Explanation

The iliopsoas muscle

The iliopsoas muscle

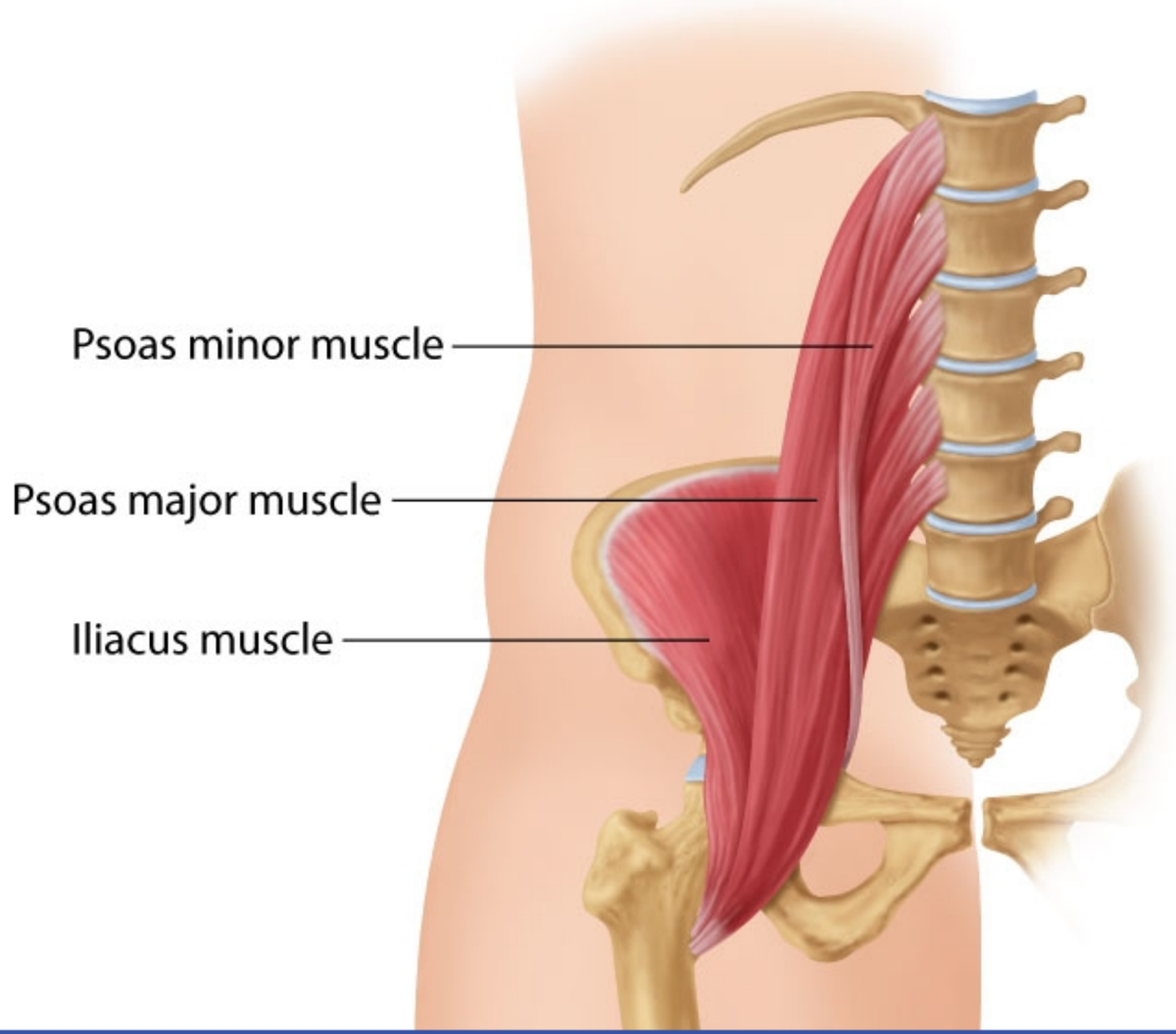

This patient most likely has a **psoas abscess**. The psoas muscle arises from the transverse processes and lateral aspects of the 12th thoracic through 5th lumbar vertebrae. It then courses downward across the pelvic brim anterior to the hip joint capsule and deep to the inguinal ligament to insert into the lesser trochanter of the femur via a tendon shared with the iliacus muscle. The iliacus and psoas muscles act as the major hip flexors.

Psoas abscesses can occur due to direct spread of infection from an adjacent structure (eg, vertebral bodies, appendix, hip joint) or from **hematogenous** or lymphatic **seeding** from a distant and sometimes unknown site (in this case, the patient's skin infection). Risk factors include diabetes mellitus, intravenous drug use, HIV infection, and other forms of immunosuppression.

Signs and symptoms of a psoas abscess include **fever**, back or **flank pain**, inguinal mass, and difficulty walking. **Pain is exacerbated** by movements that cause the psoas muscle to be stretched or extended (which causes irritation of the muscle fibers), such as **extension at the hip** (ie, psoas sign). As such, patients frequently position themselves to reduce discomfort by minimizing psoas stretching, particularly with hip flexion, external rotation, and lumbar lordosis.

The psoas sign can also occur in acute appendicitis when the appendix is retrocecal (ie, located behind the cecum), as the inflamed appendix lies upon the right psoas muscle, causing irritation.

(Choice A) The obturator externus runs from the obturator foramen of the pelvis to the trochanteric fossa of the femur. It acts to externally rotate the thigh.

(Choice C) The quadratus lumborum courses posterior to the psoas muscle. It connects the 12th rib and upper lumbar vertebra to the iliac crest. Contraction of this muscle assists in extension and lateral flexion of the vertebral column.

(Choice D) The rectus femoris is 1 of 4 quadriceps muscles that attach to the patella via the shared quadriceps tendon. It functions to extend the knee and flex the thigh. A patient with an abscess involving this muscle would most likely complain of thigh or knee pain and favor extension at the knee.

(Choice E) The transversus abdominis is the deepest of the 3 anterolaterally coursing abdominal wall muscles. It helps maintain posture and increases intraabdominal pressure during forced expiration and defecation.

Educational objective:

Psoas abscess presents with fever, back or flank pain, an inguinal mass, and difficulty walking. Inflammation of the psoas muscle leads to pain

1
2
3
4
5
6
7
8
9
10
11
12
13
14
15
16
17
18
19
20
21
22
23
24
25
26
27
28
29
30
31

Exhibit Display

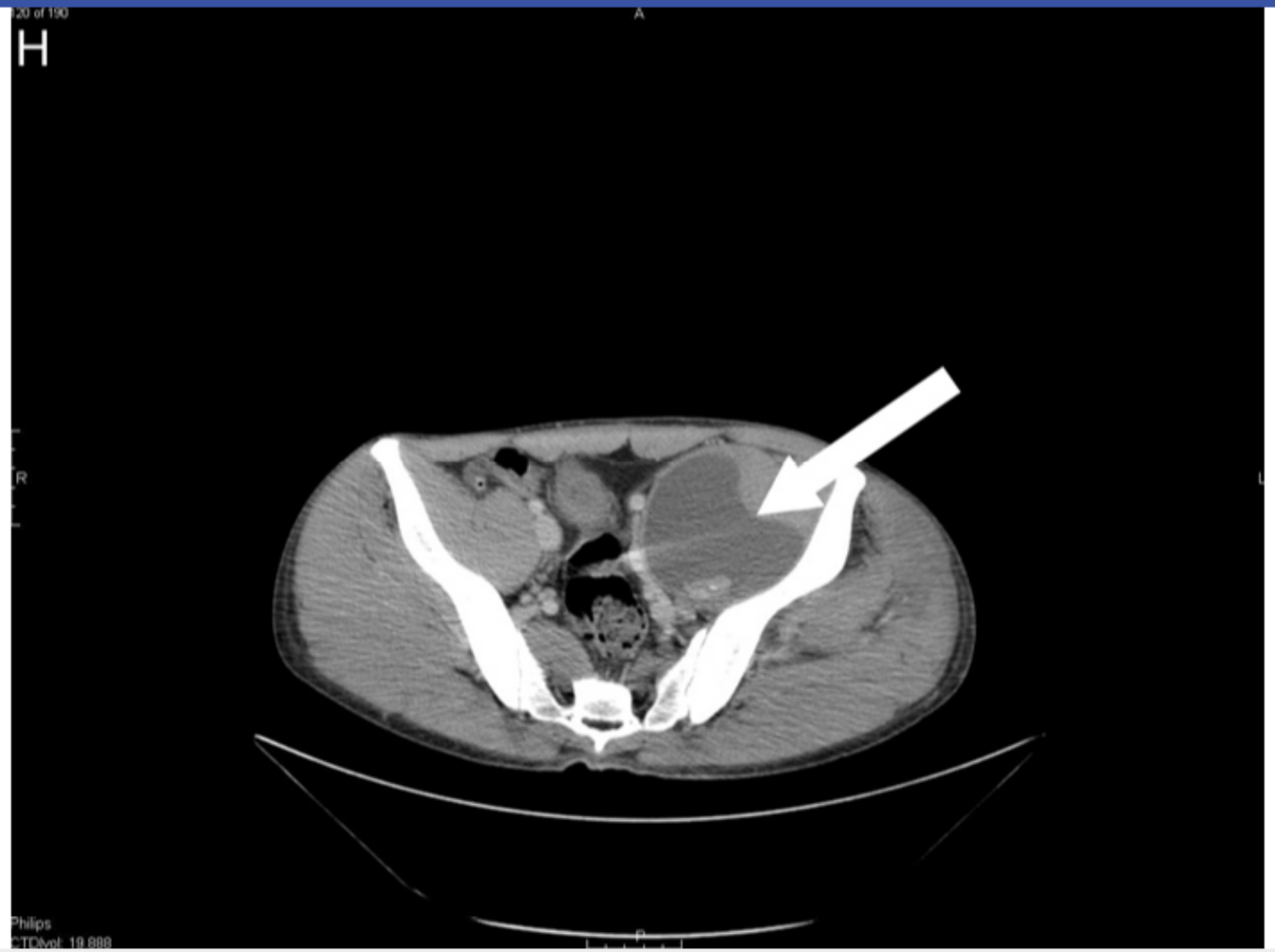

Zoom In | Zoom Out | Reset | Add To New Card | Existing Card

1
2
3
4
5
6
7
8
9
10
11
12
13
14
15
16
17
18
19
20
21
22
23
24
25
26
27
28
29
30
31

Exhibit Display

Muscles of the hip

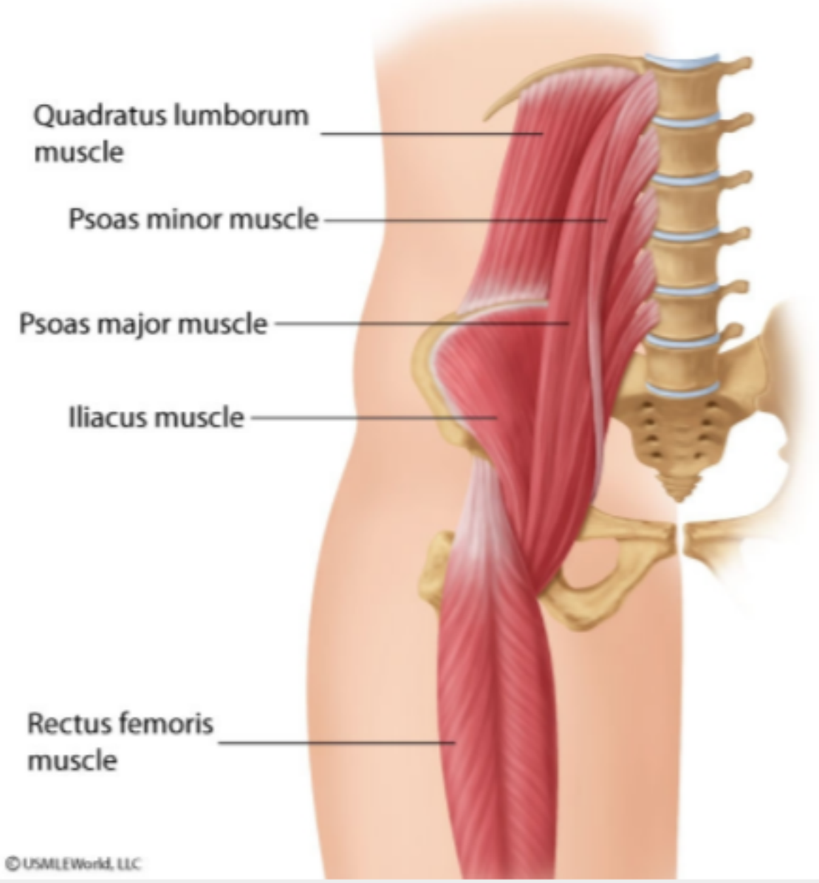

Zoom In | Zoom Out | Reset | Add To New Card | Existing Card

Exhibit Display

Abdominal wall musculature

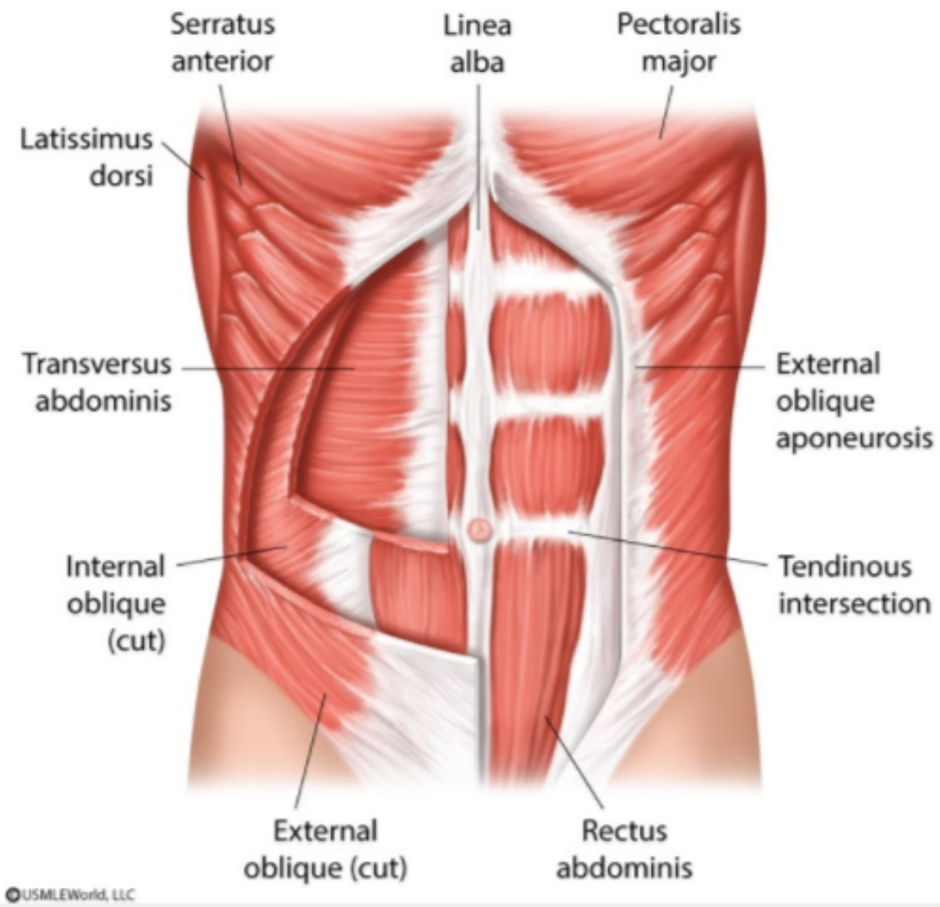

Zoom In | Zoom Out | Reset | Add To New Card | Existing Card

1
2
3
4
5
6
7
8
9
10
11
12
13
14
15
16
17
18
19
20
21
22
23
24
25
26
27
28
29
30
31

A 65-year-old man comes to the office due to right lower abdominal pain that radiates to his groin and difficulty walking for the past week. Climbing stairs has been particularly hard for him, and he has fallen several times due to knee buckling. Medical history is significant for diabetes mellitus, hypertension, and atrial fibrillation. The patient takes warfarin for chronic anticoagulation. On physical examination, the right patellar reflex is decreased compared to the left. Abdominal CT scan is shown below:

Which of the following additional findings is most likely to be seen in this patient?

A. Impaired adduction of the right thigh

B. Loss of sensation on the anterior aspect of the right thigh

1
2
3
4
5
6
7
8
9
10
11
12
13
14
15
16
17
18
19
20
21
22
23
24
25
26
27
28
29
30
31

Which of the following additional findings is most likely to be seen in this patient?

A. Impaired adduction of the right thigh

B. Loss of sensation on the anterior aspect of the right thigh

C. Loss of sensation on the dorsum of the right foot

D. Loss of sensation on the sole of the right foot

E. Weakened abduction of the right thigh

Submit

1
2
3
4
5
6
7
8
9
10
11
12
13
14
15
16
17
18
19
20
21
22
23
24
25
26
27
28
29
30
31

Which of the following additional findings is most likely to be seen in this patient?

A. Impaired adduction of the right thigh (15%)

✓ B. Loss of sensation on the anterior aspect of the right thigh (51%)

C. Loss of sensation on the dorsum of the right foot (10%)

D. Loss of sensation on the sole of the right foot (5%)

E. Weakened abduction of the right thigh (16%)

Omitted
Correct answer

51%
Answered correctly

05 secs
Time Spent

07/06/2020
Last Updated

1
2
3
4
5
6
7
8
9
10
11
12
13
14
15
16
17
18
19
20
21
22
23
24
25
26
27
28
29
30
31

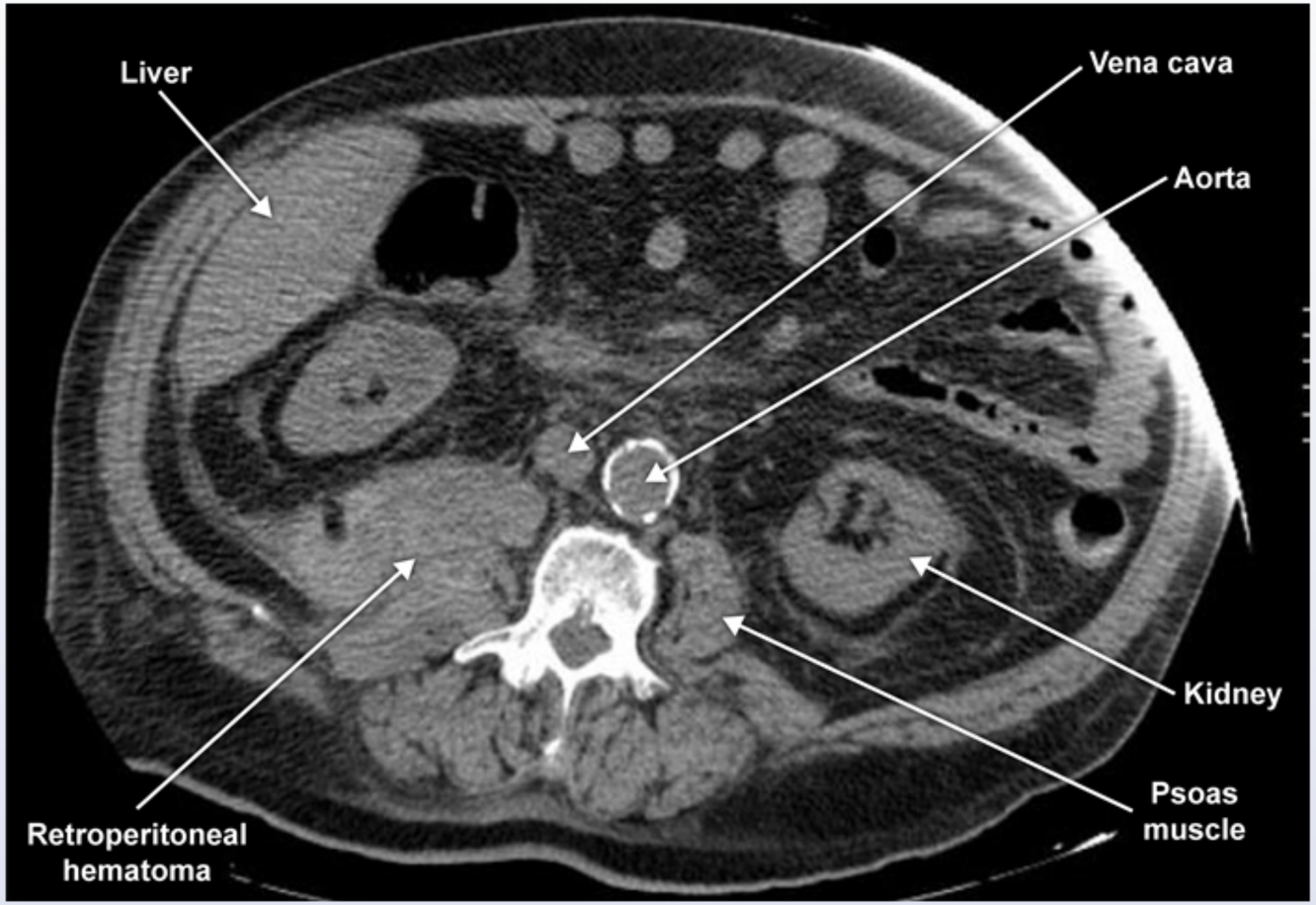

This patient's CT scan reveals a large fluid collection in the right retroperitoneum anterior to the psoas muscle. The fluid is isodense compared with muscle and displaces the right kidney. These findings are consistent with a spontaneous **retroperitoneal hematoma**, which occurs most often in patients receiving anticoagulation therapy (eg, warfarin). Affected patients often present with acute, severe pain in the groin, lower abdomen, or back; injury to the femoral nerve can also occur due to its proximity.

The **femoral nerve** descends through the psoas major muscle, emerges laterally between the psoas and iliacus muscle, and then runs beneath

This patient's CT scan reveals a large fluid collection in the right retroperitoneum anterior to the psoas muscle. The fluid is isodense compared with muscle and displaces the right kidney. These findings are consistent with a spontaneous **retroperitoneal hematoma**, which occurs most often in patients receiving anticoagulation therapy (eg, warfarin). Affected patients often present with acute, severe pain in the groin, lower abdomen, or back; injury to the femoral nerve can also occur due to its proximity.

The **femoral nerve** descends through the psoas major muscle, emerges laterally between the psoas and iliacus muscle, and then runs beneath the inguinal ligament into the thigh. Femoral nerve mononeuropathy can occur due to trauma (eg, pelvic fracture), **compression from a hematoma** or abscess, or injury during surgery/childbirth. Findings of femoral neuropathy include **quadriceps weakness** (eg, difficulty with stairs, falling due to knee buckling), **decreased patellar reflex**, and **sensory loss** over the **anterior and medial thigh** and medial leg.

(Choice A) Obturator nerve injury presents with weakness of thigh adduction and medial thigh sensory loss. It is most commonly seen as an iatrogenic complication of pelvic surgery.

(Choice C) Peroneal nerve injury often presents with loss of dorsal foot sensation and foot drop due to weakness of foot eversion, dorsiflexion, and toe extension. It is typically caused by compression of the nerve at the proximal fibula (eg, from leg casting).

(Choice D) Tibial nerve injury causes numbness at the sole and is typically associated with decreased inversion and plantarflexion of the foot and flexion of the toes. Common causes include knee trauma and tarsal tunnel syndrome.

(Choice E) Weakened abduction of the thigh occurs with superior gluteal nerve injury and results in a Trendelenburg gait. There are no associated sensory deficits.

Educational objective:
Femoral nerve mononeuropathy can occur due to trauma; compression from a retroperitoneal hematoma or abscess, or injury during surgery or childbirth. Findings include quadriceps weakness, decreased patellar reflex, and sensory loss over the anterior and medial thigh and medial leg.

Anatomy	Rheumatology/Orthopedics & Sports	Femoral neuropathy
Subject	System	Topic

Copyright © UWorld. All rights reserved.

Exhibit Display

Lower extremity nerve	Nerve roots	Cause of injury	Sensory deficit	Motor deficit
Obturator	L2-L4	Iatrogenic (eg, pelvic surgery)		Thigh adduction
Femoral	L2-L4	Pelvic fracture or mass involving iliopsoas/iliacus muscle (eg, hematoma or abscess)		Flexion of thigh, extension of leg
Common peroneal	L4-S2	Fibula neck fracture or nerve compression at fibular neck		Foot eversion, dorsiflexion, toe extension
Tibial	L4-S3	Trauma to the knee, tarsal tunnel syndrome		Foot inversion, plantar flexion & toe flexion
Superior gluteal	L4-S1	Iatrogenic (eg, posterior hip dislocation or buttocks injection)	None	Thigh abduction
Inferior gluteal	L5-S2		None	Thigh extension

©UWorld

Zoom In | Zoom Out | Reset | Add To New Card | Existing Card

1
2
3
4
5
6
7
8
9
10
11
12
13
14
15
16
17
18
19
20
21
22
23
24
25
26
27
28
29
30
31

Exhibit Display

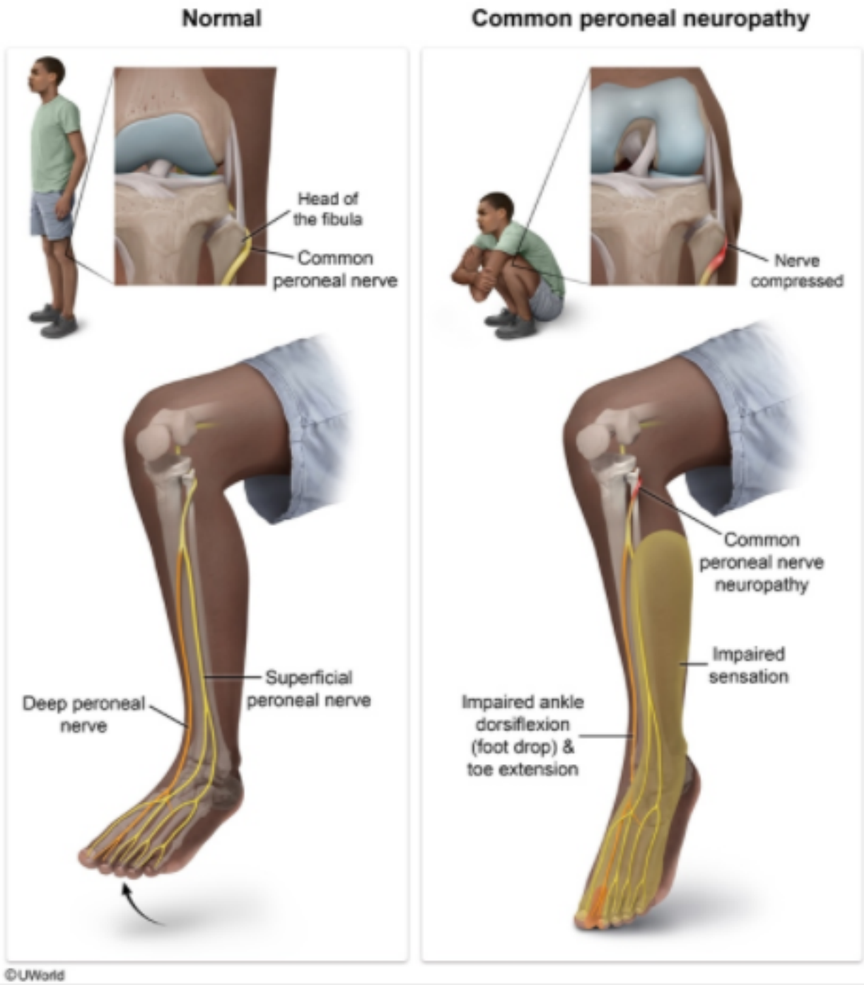

Zoom In | Zoom Out | Reset | Add To New Card | Existing Card

1
2
3
4
5
6
7
8
9
10
11
12
13
14
15
16
17
18
19
20
21
22
23
24
25
26
27
28
29
30
31

Exhibit Display

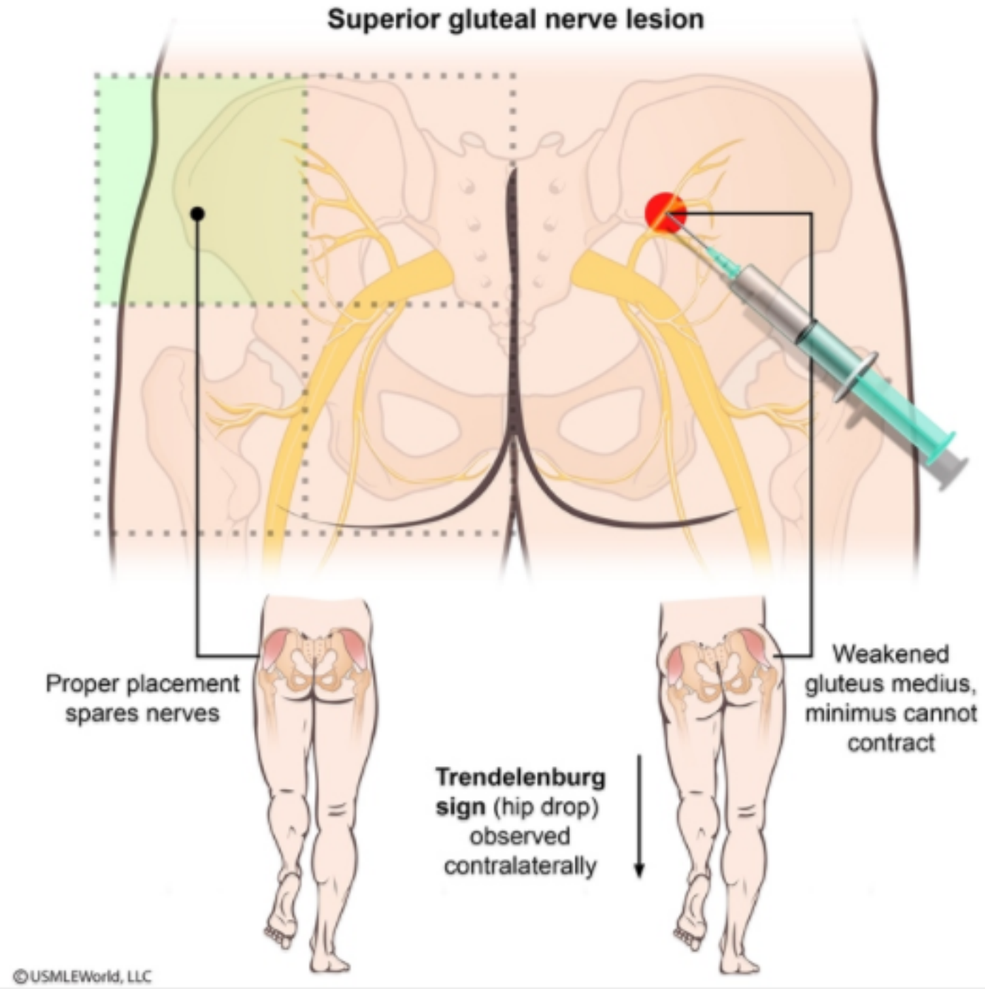

Zoom In | Zoom Out | Reset | Add To New Card | Existing Card

1
2
3
4
5
6
7
8
9
10
11
12
13
14
15
16
17
18
19
20
21
22
23
24
25
26
27
28
29
30
31

A 54-year-old man comes to the office due to aching pain in his left neck and shoulder area for the past several months. He has also had numbness and weakness of the left hand. The patient recalls no major trauma and has no prior medical problems. He tried chiropractic and massage therapies, but the symptoms persisted. Left upper extremity examination shows decreased sensation in the palm and index and middle fingers along with weakness of left wrist extension. The left biceps and brachioradialis deep tendon reflexes are normal, but the triceps reflex is diminished. Right upper extremity examination is normal. A lesion affecting which of the following labeled sections of the brachial plexus is the most likely cause of this patient's neurologic findings?

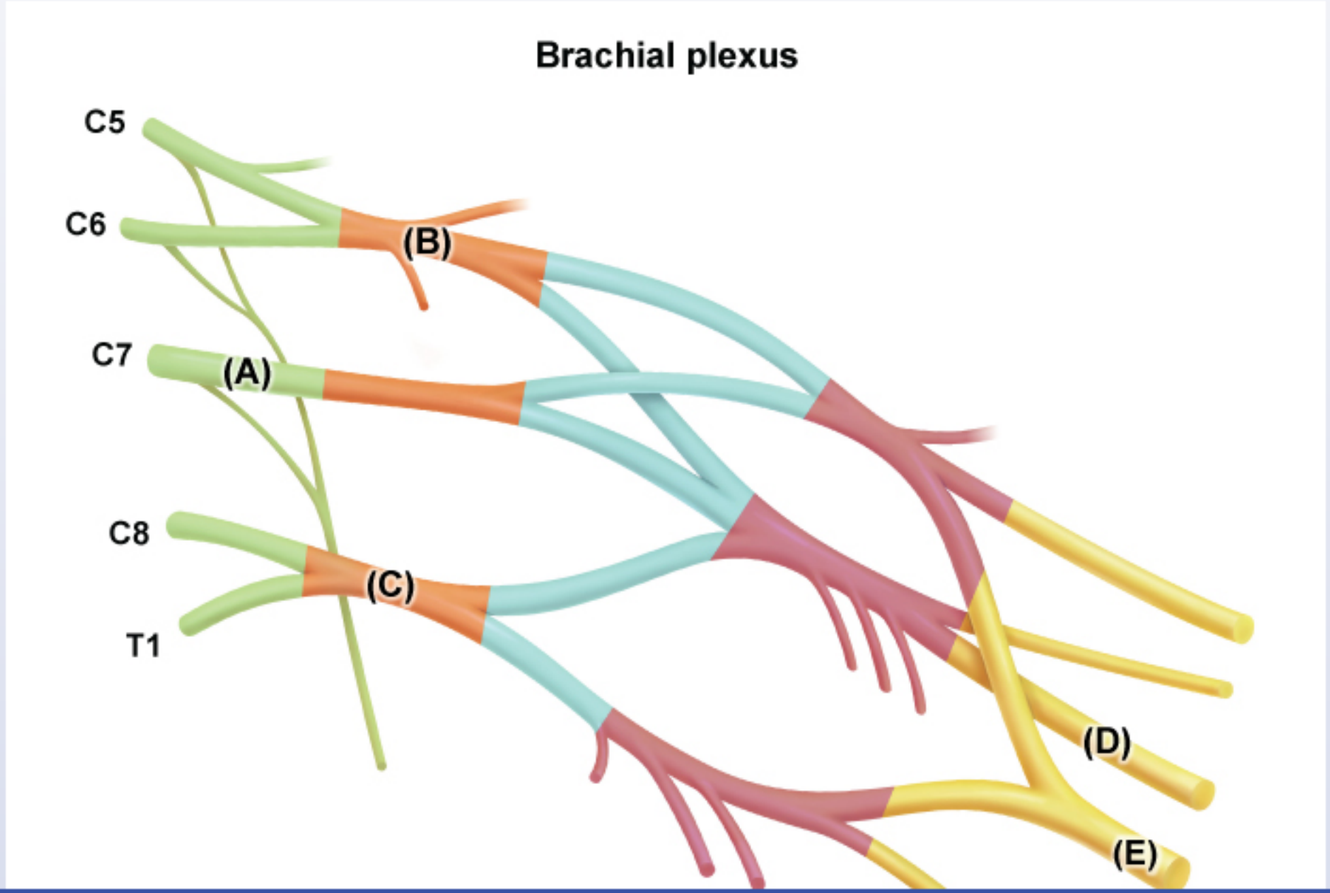

6
7
8
9
10
11
12
13
14
15
16
17
18
19
20
21
22
23
24
25
26
27
28
29
30
31
32
33
34
35
36

Exhibit Display

Brachial plexus

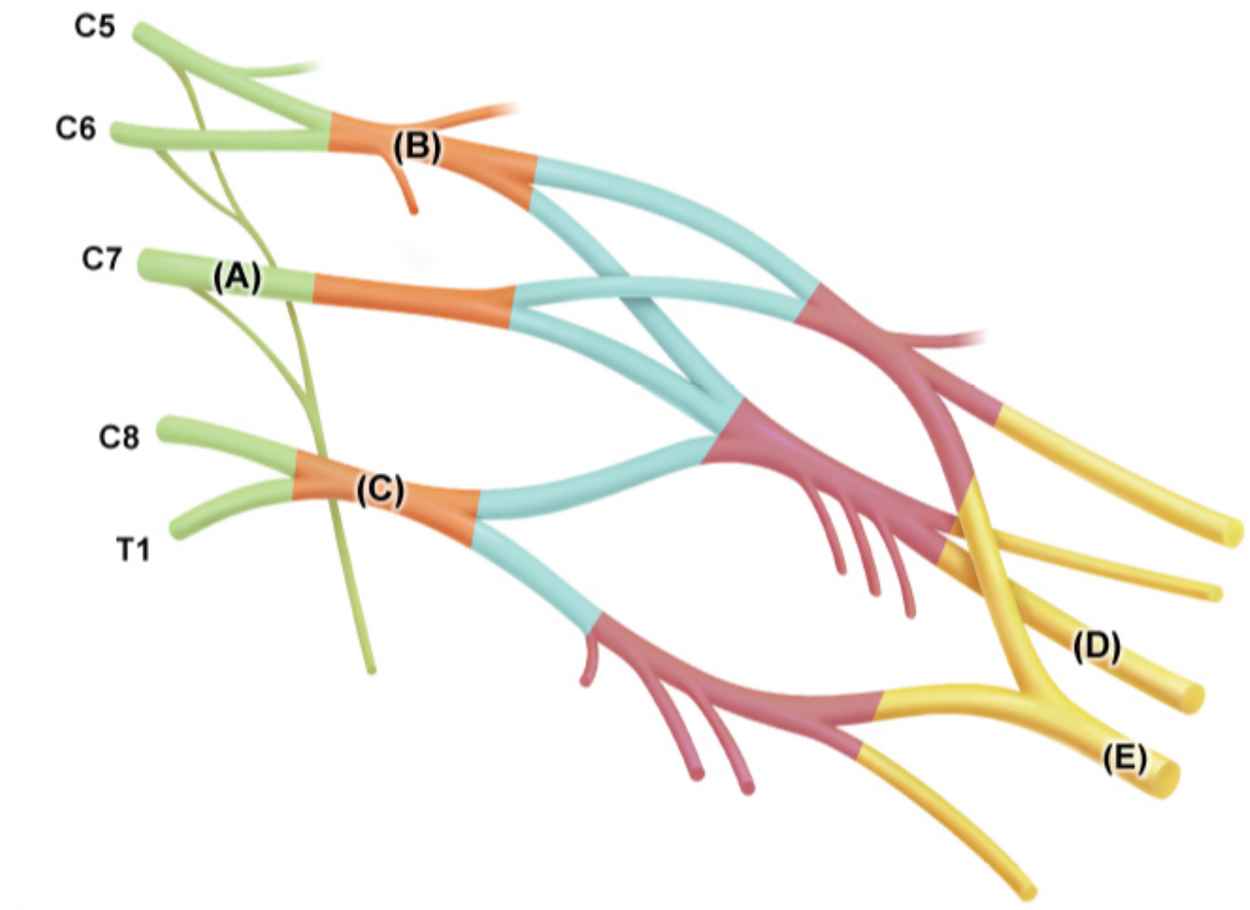

Zoom In | Zoom Out | Reset | Add To New Card | Existing Card

6
7
8
9
10
11
12
13
14
15
16
17
18
19
20
21
22
23
24
25
26
27
28
29
30
31
32
33
34
35
36

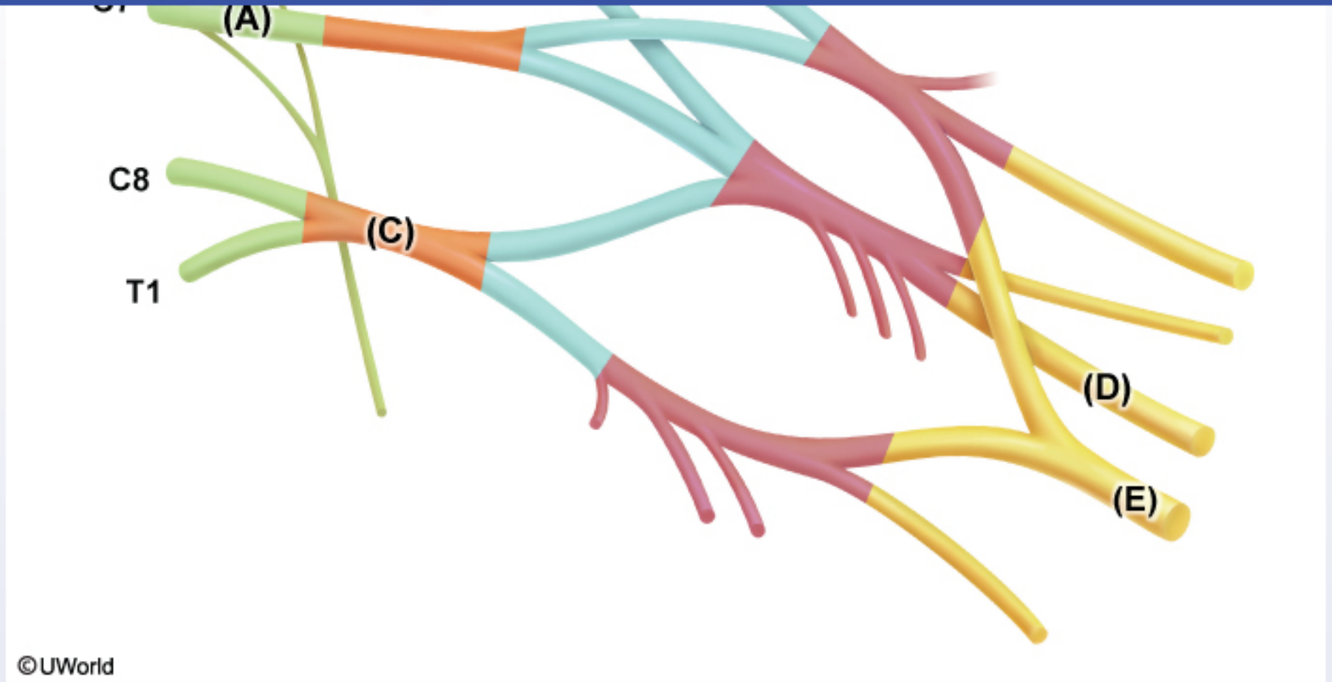

A. A
B. B
C. C
D. D
E. E

Submit

6
7
8
9
10
11
12
13
14
15
16
17
18
19
20
21
22
23
24
25
26
27
28
29
30
31
32
33
34
35
36

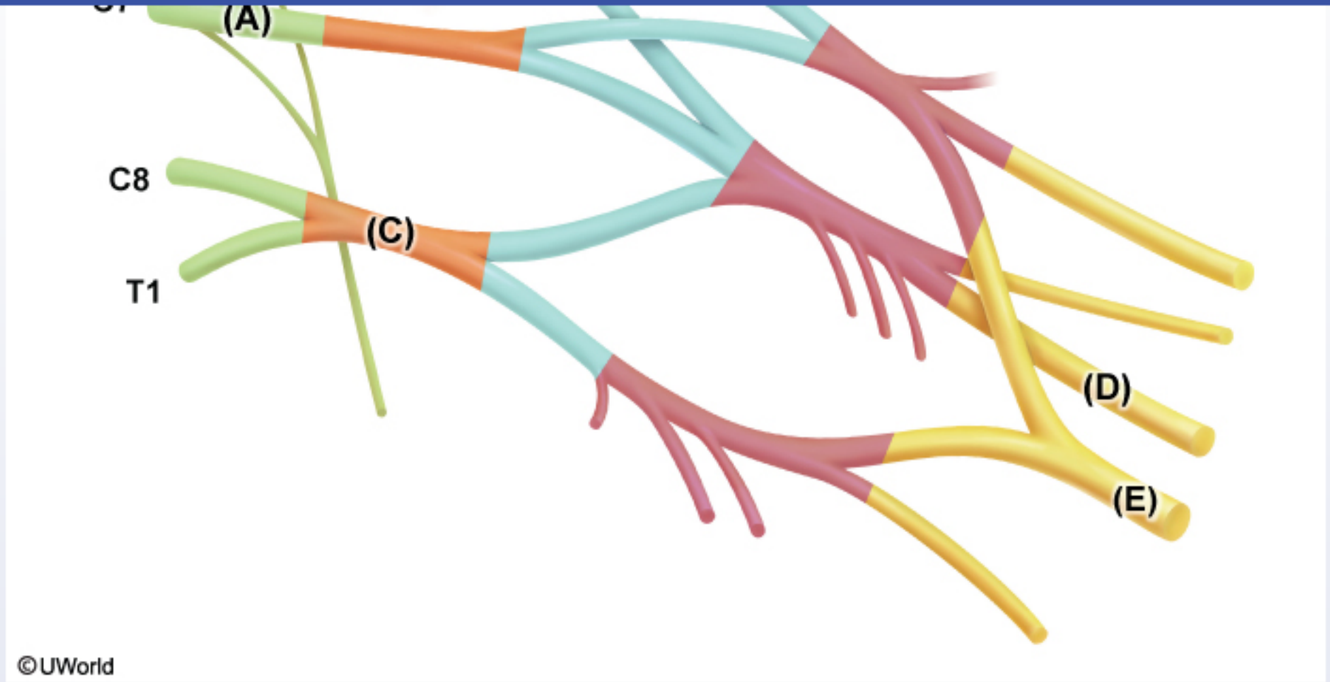

- A. A (38%)
- B. B (8%)
- C. C (14%)
- D. D (30%)
- E. E (8%)

Omitted
Correct answer

38%
Answered correctly

12 secs
Time Spent

06/05/2020
Last Updated

6
7
8
9
10
11
12
13
14
15
16
17
18
19
20
21
22
23
24
25
26
27
28
29
30
31
32
33
34
35
36

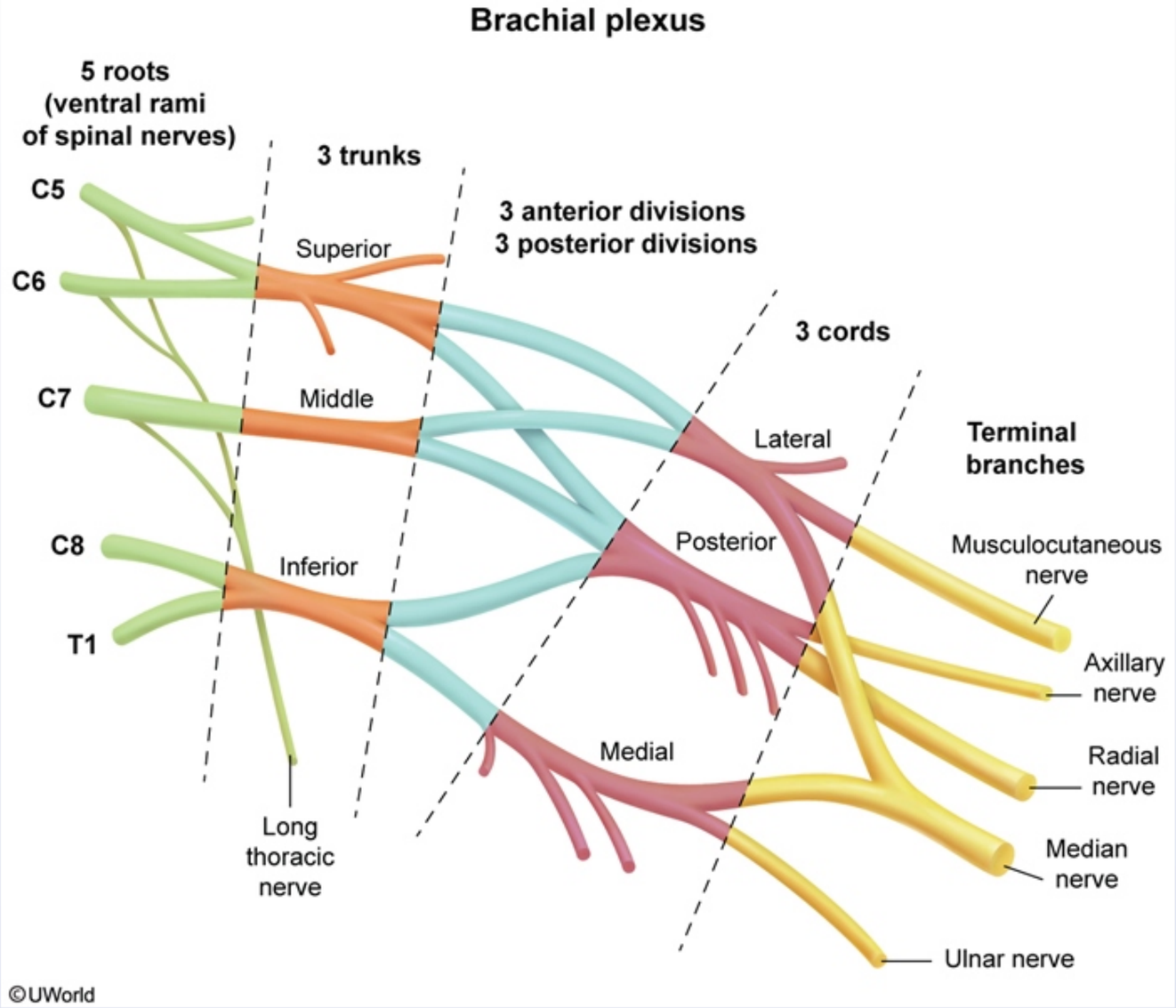

The C5 through T1 nerve roots form the brachial plexus trunks, divisions, cords, and ultimately terminal branches, which supply sensory and motor

The C5 through T1 nerve roots form the brachial plexus trunks, divisions, cords, and ultimately terminal branches, which supply sensory and motor innervation to the upper extremities. This patient has deficits involving both the **radial** (eg, triceps reflex, wrist extension) and **median** (sensation to palm and index and middle finger) nerves. This pattern of deficits across **multiple peripheral nerves** indicates a lesion **proximal** to the formation of the terminal branches.

In a patient without history of trauma or malignancy, chronic shoulder and **radicular arm pain** with sensorimotor deficits is most likely caused by compression of a nerve root due to **cervical spondylosis**. The C7 root is the most frequently affected nerve root in patients with cervical radiculopathy, resulting in deficits across the median and radial nerve distributions.

(Choices B and C) Damage to the superior or inferior trunk most often occurs as a result of trauma (eg, traction during delivery in infants; falls in adults). A superior trunk lesion (eg, Erb-Duchenne palsy) would result in loss of arm abduction, elbow flexion, and wrist extension (waiter's tip position: adducted arm with extended elbow and flexed wrist). An inferior trunk lesion (eg, Klumpke palsy) typically results in loss of wrist/metacarpophalangeal joint flexion and interphalangeal joint extension (claw hand position: extended wrist/metacarpophalangeal joints with flexed interphalangeal joints).

(Choices D and E) Damage to one of the terminal branches of the brachial plexus would result in a pattern of deficits restricted to the sensory and/or motor function of one nerve. The radial nerve can be injured by compression against the humerus (eg, Saturday night palsy) or by a humerus fracture, causing weakness in wrist extension (eg, wrist drop). Injury to the median nerve most commonly occurs at the wrist (eg, carpal tunnel syndrome) with resulting numbness, tingling, and pain in the palm and first 3 digits.

Educational objective:
Motor and sensory deficits across multiple peripheral upper extremity nerves (eg, radial and median) indicate a lesion in the brachial plexus proximal to the formation of the terminal branches. In the absence of history of trauma or malignancy, the most likely cause is nerve root compression due to cervical spondylosis (cervical radiculopathy).

References

- Diagnosis and treatment of cervical radiculopathy and myelopathy.

Anatomy	Rheumatology/Orthopedics & Sports	Radiculopathy
Subject	System	Topic

innervation to the upper extremities. This patient has deficits involving both the **radial** (eg, triceps reflex, wrist extension) and **median** (sensation to palm and index and middle finger) nerves. This pattern of deficits across **multiple peripheral nerves** indicates a lesion **proximal** to the formation of the terminal branches.

In a patient without history of trauma or malignancy, chronic shoulder and **radicular arm pain** with sensorimotor deficits is most likely caused by compression of a nerve root due to **cervical spondylosis**. The C7 root is the most frequently affected nerve root in patients with cervical radiculopathy, resulting in deficits across the median and radial nerve distributions.

(Choices B and C) Damage to the superior or inferior trunk most often occurs as a result of trauma (eg, traction during delivery in infants; falls in adults). A superior trunk lesion (eg, Erb-Duchenne palsy) would result in loss of arm abduction, elbow flexion, and wrist extension (waiter's tip position: adducted arm with extended elbow and flexed wrist). An inferior trunk lesion (eg, Klumpke palsy) typically results in loss of wrist/metacarpophalangeal joint flexion and interphalangeal joint extension (claw hand position: extended wrist/metacarpophalangeal joints with flexed interphalangeal joints).

(Choices D and E) Damage to one of the terminal branches of the brachial plexus would result in a pattern of deficits restricted to the sensory and/or motor function of one nerve. The radial nerve can be injured by compression against the humerus (eg, Saturday night palsy) or by a humerus fracture, causing weakness in wrist extension (eg, wrist drop). Injury to the median nerve most commonly occurs at the wrist (eg, carpal tunnel syndrome) with resulting numbness, tingling, and pain in the palm and first 3 digits.

Educational objective:
Motor and sensory deficits across multiple peripheral upper extremity nerves (eg, radial and median) indicate a lesion in the brachial plexus proximal to the formation of the terminal branches. In the absence of history of trauma or malignancy, the most likely cause is nerve root compression due to cervical spondylosis (cervical radiculopathy).

References

- Diagnosis and treatment of cervical radiculopathy and myelopathy.

Anatomy	Rheumatology/Orthopedics & Sports	Radiculopathy
Subject	System	Topic

Copyright © UWorld. All rights reserved.

6
7
8
9
10
11
12
13
14
15
16
17
18
19
20
21
22
23
24
25
26
27
28
29
30
31
32
33
34
35
36

nerve

Exhibit Display

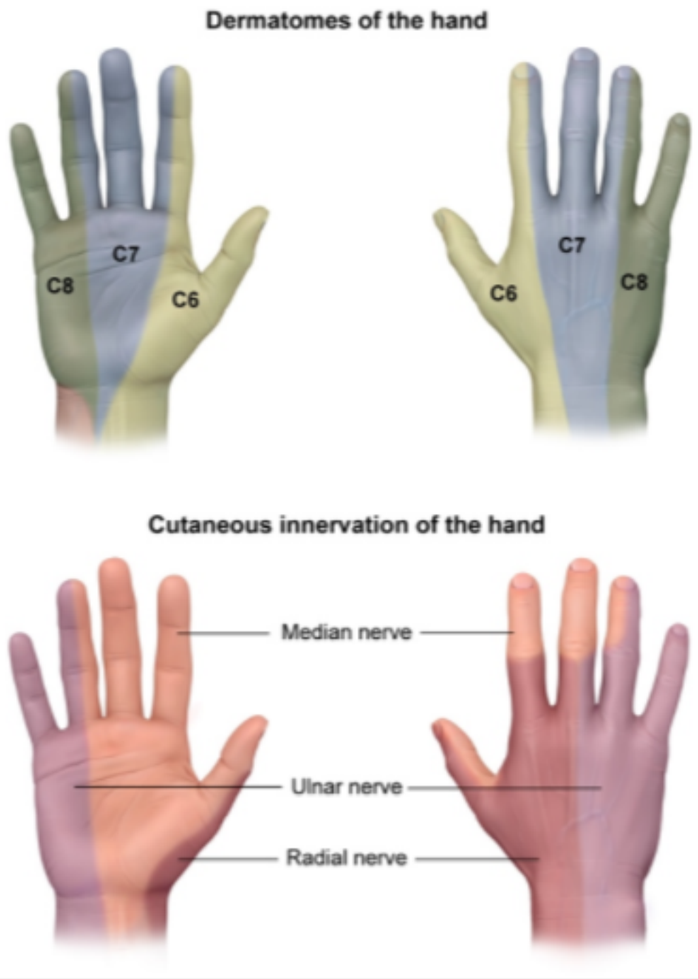

Zoom In | Zoom Out | Reset | Add To New Card | Existing Card

Educational objective:

6
7
8
9
10
11
12
13
14
15
16
17
18
19
20
21
22
23
24
25
26
27
28
29
30
31
32
33
34
35
36

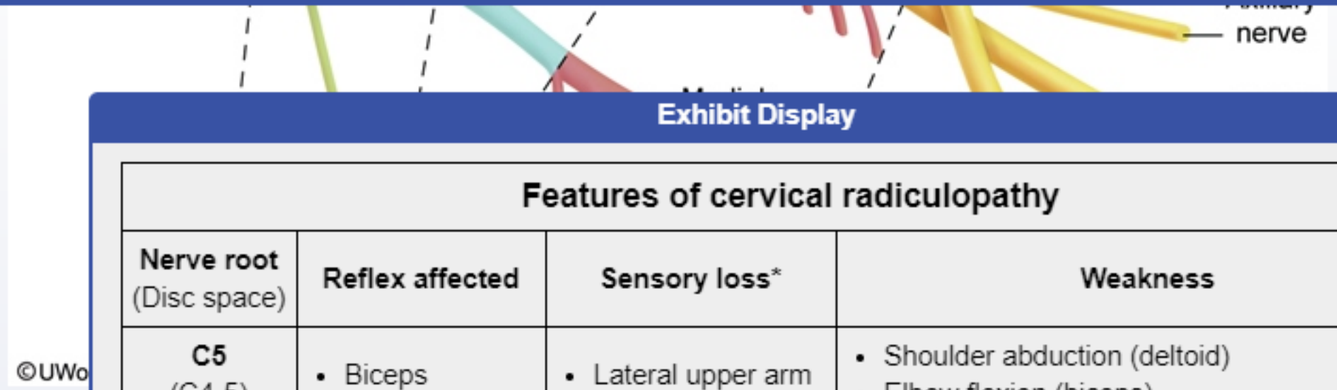

©UWo

The C5 through T1 nerve
innervation to the upper e
to palm and index and mi
formation of the terminal b

In a patient without history
compression of a nerve ro
radiculopathy, resulting in

(Choices B and C) Dama
adults). A superior trunk l
position: adducted arm wi
wrist/metacarpophalangea
flexed interphalangeal joi

(Choices D and E) Dama
and/or motor function of o
humerus fracture, causing
tunnel syndrome) with resulting numbness, tingling, and pain in the palm and first 3 digits.

Educational objective:

otor
on
y
s in
h
pal

Exhibit Display

Features of cervical radiculopathy

Nerve root (Disc space)	Reflex affected	Sensory loss*	Weakness
C5 (C4-5)	• Biceps	• Lateral upper arm	• Shoulder abduction (deltoid) • Elbow flexion (biceps)
C6 (C5-6)	• Biceps • Brachioradialis	• Thumb • Index finger	• Elbow flexion (biceps) • Forearm pronation/supination (brachioradialis) • Wrist extension
C7 (C6-7)	• Triceps	• Dorsal forearm • Middle finger	• Elbow extension (triceps) • Wrist flexion • Finger extension
C8 (C7-T1)	• Finger flexors**	• Ring & little fingers	• Finger flexion & extension • Thumb flexion & abduction
T1 (T1-2)	• Finger flexors**	• Medial forearm	• Finger abduction & adduction

*In addition to neck/shoulder pain, radicular pain typically has a similar distribution to sensory loss.
**Not typically evaluated clinically.

Add To New Card | Existing Card

6
7
8
9
10
11
12
13
14
15
16
17
18
19
20
21
22
23
24
25
26
27
28
29
30
31
32
33
34
35
36

nerve

Exhibit Display

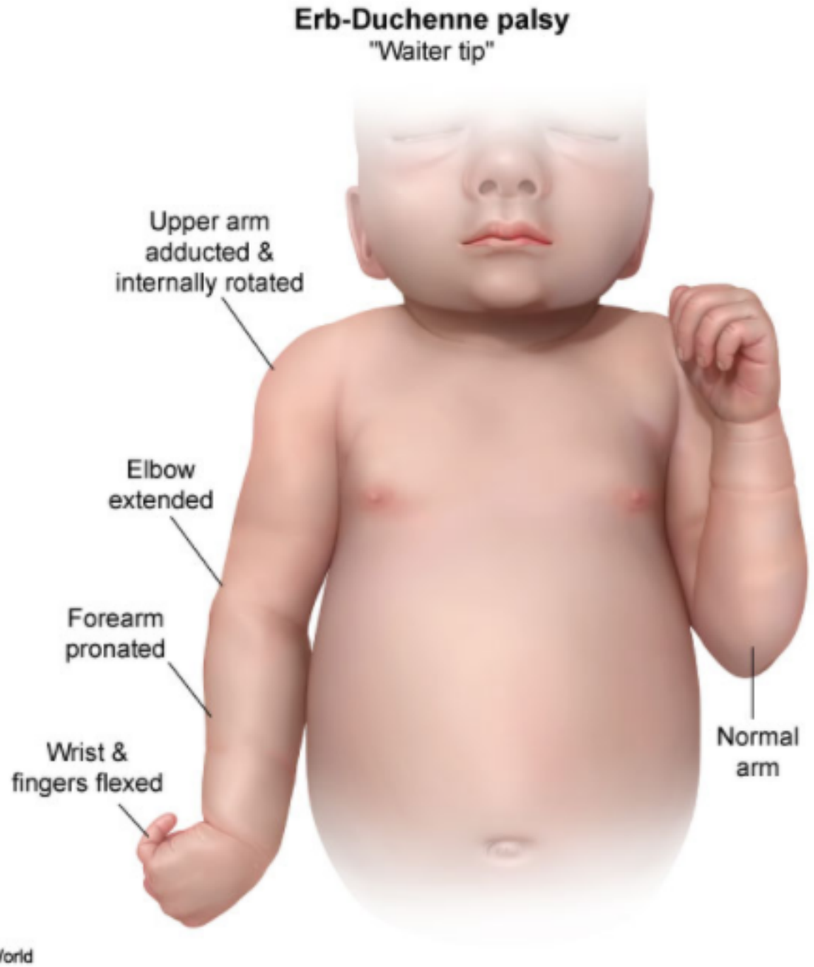

Zoom In | Zoom Out | Reset | Add To New Card | Existing Card

Educational objective:

6
7
8
9
10
11
12
13
14
15
16
17
18
19
20
21
22
23
24
25
26
27
28
29
30
31
32
33
34
35
36

nerve

Exhibit Display

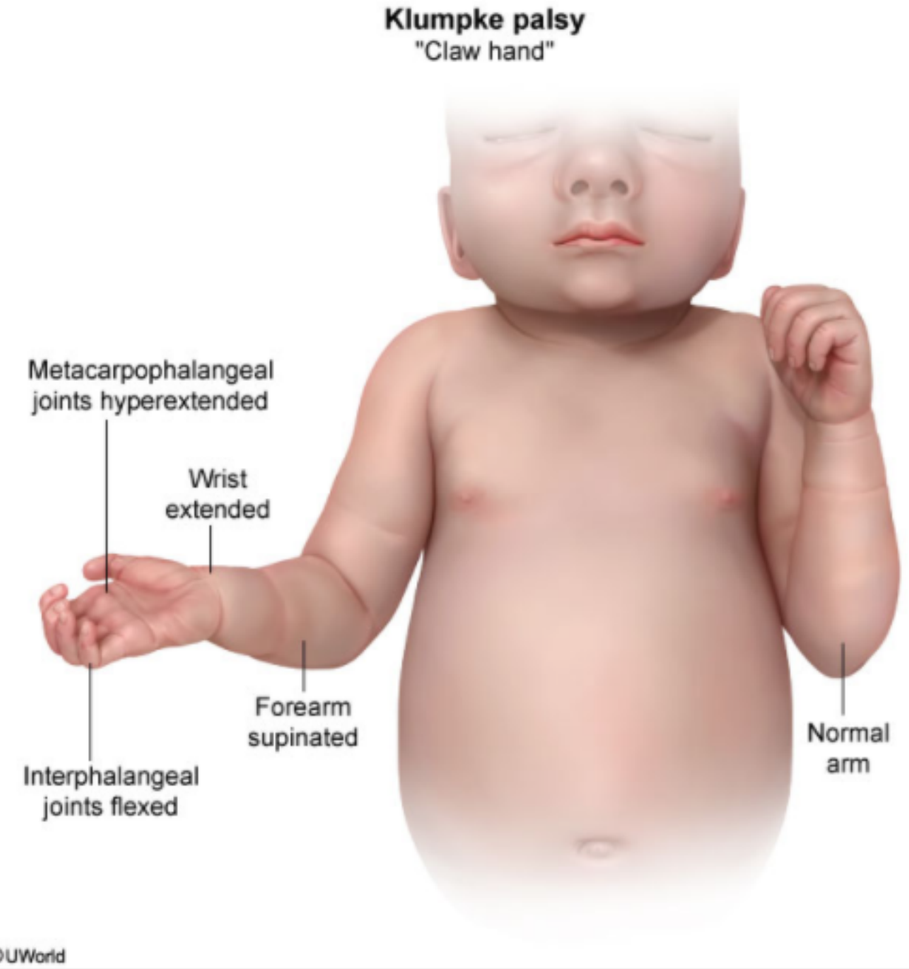

Zoom In | Zoom Out | Reset | Add To New Card | Existing Card

Educational objective:

to palm and index and middle finger) nerves. This pattern of deficits across **multiple peripheral nerves** indicates a lesion **proximal** to the formation of the terminal branches.

In a patient without history of trauma or malignancy, chronic shoulder and **radicular arm pain** with sensorimotor deficits is most likely caused by compression of a nerve root due to **cervical spondylosis**. The C7 root is the most frequently affected nerve root in patients with cervical radiculopathy, resulting in deficits across the median and radial nerve distributions.

(Choices B and C) Damage to the superior or inferior trunk most often occurs as a result of trauma (eg, traction during delivery in infants; falls in adults). A superior trunk lesion (eg, Erb-Duchenne palsy) would result in loss of arm abduction, elbow flexion, and wrist extension (waiter's tip position: adducted arm with extended elbow and flexed wrist). An inferior trunk lesion (eg, Klumpke palsy) typically results in loss of wrist/metacarpophalangeal joint flexion and interphalangeal joint extension (claw hand position: extended wrist/metacarpophalangeal joints with flexed interphalangeal joints).

(Choices D and E) Damage to one of the terminal branches of the brachial plexus would result in a pattern of deficits restricted to the sensory and/or motor function of one nerve. The radial nerve can be injured by compression against the humerus (eg, Saturday night palsy) or by a humerus fracture, causing weakness in wrist extension (eg, wrist drop). Injury to the median nerve most commonly occurs at the wrist (eg, carpal tunnel syndrome) with resulting numbness, tingling, and pain in the palm and first 3 digits.

Educational objective:
Motor and sensory deficits across multiple peripheral upper extremity nerves (eg, radial and median) indicate a lesion in the brachial plexus proximal to the formation of the terminal branches. In the absence of history of trauma or malignancy, the most likely cause is nerve root compression due to cervical spondylosis (cervical radiculopathy).

References

- Diagnosis and treatment of cervical radiculopathy and myelopathy.

Anatomy	Rheumatology/Orthopedics & Sports	Radiculopathy
Subject	System	Topic

Copyright © UWorld. All rights reserved.

A 19-year-old man is brought to the emergency department after he punched through a plate glass window with his right arm. Initially there was profuse bleeding, but it stopped after direct pressure was maintained by emergency medical personnel. A deep laceration is present at the proximal aspect of the right cubital fossa, just lateral to the medial epicondyle. Examination reveals absent sensation in the lateral palm and the palmar surfaces of the first 3½ fingers, inability to flex the proximal interphalangeal joints, and inability to pronate the forearm. Additional injury to which of the following structures was most likely responsible for this patient's bleeding?

- A. Anterior interosseous artery
- B. Brachial artery
- C. Deep brachial artery
- D. Radial artery
- E. Radial recurrent artery
- F. Ulnar artery

Submit

A 19-year-old man is brought to the emergency department after he punched through a plate glass window with his right arm. Initially there was profuse bleeding, but it stopped after direct pressure was maintained by emergency medical personnel. A deep laceration is present at the proximal aspect of the right cubital fossa, just lateral to the medial epicondyle. Examination reveals absent sensation in the lateral palm and the palmar surfaces of the first 3½ fingers, inability to flex the proximal interphalangeal joints, and inability to pronate the forearm. Additional injury to which of the following structures was most likely responsible for this patient's bleeding?

- A. Anterior interosseous artery (4%)
- ✓ B. Brachial artery (56%)
- C. Deep brachial artery (10%)
- D. Radial artery (15%)
- E. Radial recurrent artery (2%)
- F. Ulnar artery (11%)

Omitted
Correct answer
B

56%
Answered correctly

03 secs
Time Spent

06/24/2020
Last Updated

Explanation

Cubital fossa

Superior border

Contents of the cubital fossa

6
7
8
9
10
11
12
13
14
15
16
17
18
19
20
21
22
23
24
25
26
27
28
29
30
31
32
33
34
35
36

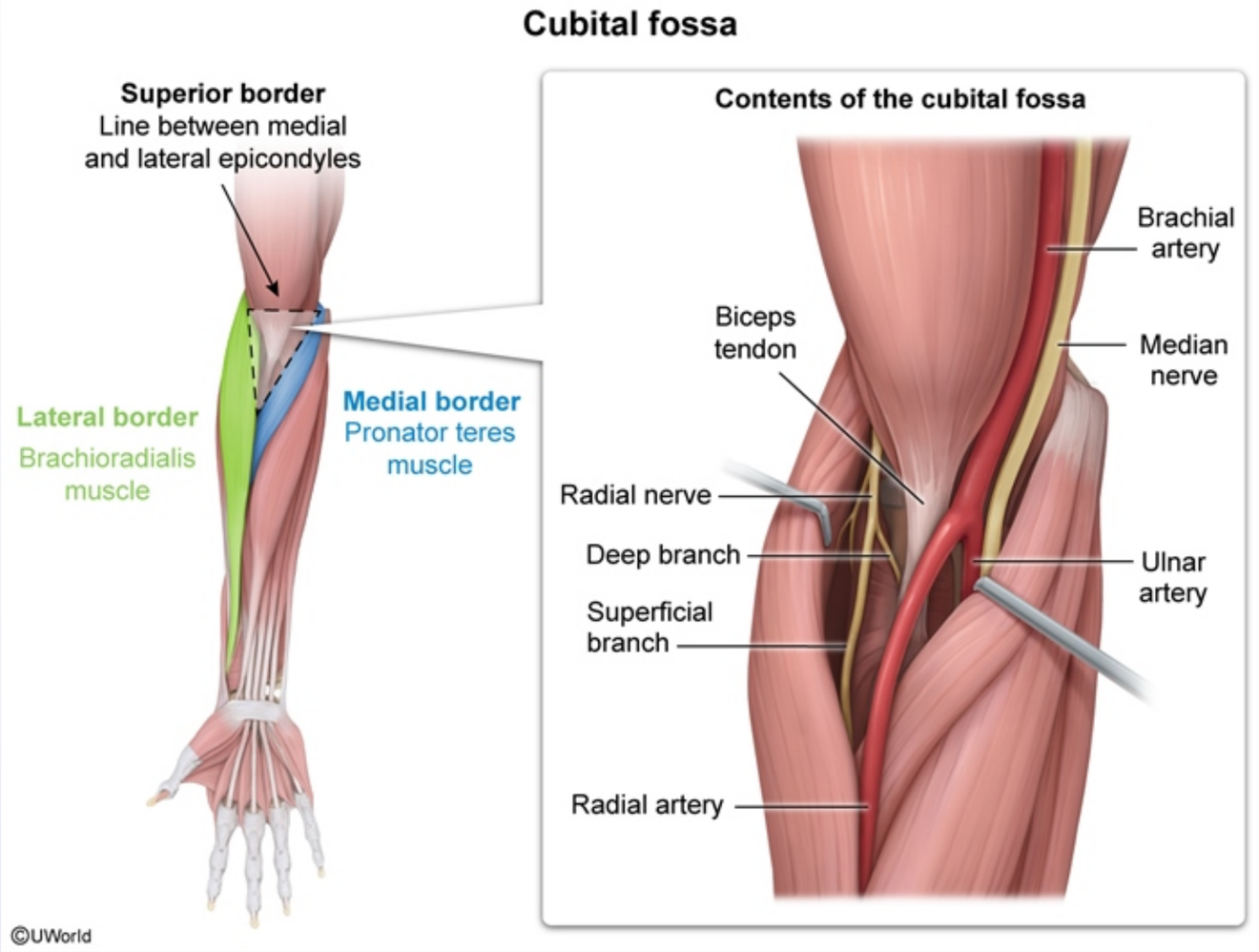

This patient's **cubital fossa laceration** has resulted in **median nerve injury**, leading to impairment of forearm pronation (pronator teres) and proximal interphalangeal joint flexion (flexor digitorum superficialis), along with sensory deficits in the median distribution. Because the **brachial artery is adjacent** to the median nerve at the cubital fossa, injury to the brachial artery was most likely responsible for this patient's bleeding.

The brachial artery is the continuation of the axillary artery as it extends past the inferior border of the teres major muscle. In the upper arm, the

This patient's **cubital fossa laceration** has resulted in **median nerve injury**, leading to impairment of forearm pronation (pronator teres) and proximal interphalangeal joint flexion (flexor digitorum superficialis), along with sensory deficits in the median distribution. Because the **brachial artery is adjacent** to the median nerve at the cubital fossa, injury to the brachial artery was most likely responsible for this patient's bleeding.

The brachial artery is the continuation of the axillary artery as it extends past the inferior border of the teres major muscle. In the upper arm, the brachial artery courses in the medial bicipital groove between the biceps brachii and triceps brachii muscles, giving off multiple branches (eg, deep brachial artery) and running alongside both the median and ulnar nerves. Proximal to the elbow, the median and ulnar nerves diverge; **only** the **median nerve accompanies** the **brachial artery** through the **cubital fossa** (lateral to the medial epicondyle) into the proximal anterior forearm, where the brachial artery splits into the radial and ulnar arteries. In contrast, the ulnar nerve travels posterior to the medial epicondyle.

(Choice A) The anterior interosseous artery runs alongside the anterior interosseous nerve, a branch of the median nerve that supplies most of the deep volar forearm muscles. The anterior interosseous nerve and artery originate in the forearm, distal to the cubital fossa.

(Choice C) The deep brachial artery is the first branch off the brachial artery in the upper arm. It courses posterior to the humerus and is vulnerable to injury with humeral shaft fractures.

(Choices D and E) Shortly after originating from the brachial artery in the forearm, the radial artery gives off the radial recurrent artery, which ascends in proximity to the radial nerve near the *lateral* epicondyle. The radial artery then accompanies the superficial branch of the radial nerve through most of the forearm. The absence of radial nerve deficits and laceration location (cubital fossa near *medial* epicondyle) make injury to these vessels unlikely.

(Choice F) The ulnar artery originates from the brachial artery in the forearm (distal to the medial epicondyle). It runs alongside the ulnar nerve through most of the forearm.

Educational objective:
The brachial artery runs alongside the median and ulnar nerves in the medial bicipital groove of the upper arm. Proximal to the elbow, the median and ulnar nerves diverge, and the brachial artery continues with the median nerve through the cubital fossa. Injury to the median nerve at the cubital fossa frequently injures the brachial artery.

References

- Relationship of the median and radial nerves at the elbow: application to avoid injury during venipuncture or other invasive procedures of the cubital fossa.

brachial artery) and running alongside both the median and ulnar nerves. Proximal to the elbow, the median and ulnar nerves diverge; **only** the **median nerve accompanies** the **brachial artery** through the **cubital fossa** (lateral to the medial epicondyle) into the proximal anterior forearm, where the brachial artery splits into the radial and ulnar arteries. In contrast, the ulnar nerve travels posterior to the medial epicondyle.

(Choice A) The anterior interosseous artery runs alongside the anterior interosseous nerve, a branch of the median nerve that supplies most of the deep volar forearm muscles. The anterior interosseous nerve and artery originate in the forearm, distal to the cubital fossa.

(Choice C) The deep brachial artery is the first branch off the brachial artery in the upper arm. It courses posterior to the humerus and is vulnerable to injury with humeral shaft fractures.

(Choices D and E) Shortly after originating from the brachial artery in the forearm, the radial artery gives off the radial recurrent artery, which ascends in proximity to the radial nerve near the *lateral* epicondyle. The radial artery then accompanies the superficial branch of the radial nerve through most of the forearm. The absence of radial nerve deficits and laceration location (cubital fossa near *medial* epicondyle) make injury to these vessels unlikely.

(Choice F) The ulnar artery originates from the brachial artery in the forearm (distal to the medial epicondyle). It runs alongside the ulnar nerve through most of the forearm.

Educational objective:
The brachial artery runs alongside the median and ulnar nerves in the medial bicipital groove of the upper arm. Proximal to the elbow, the median and ulnar nerves diverge, and the brachial artery continues with the median nerve through the cubital fossa. Injury to the median nerve at the cubital fossa frequently injures the brachial artery.

References

- Relationship of the median and radial nerves at the elbow: application to avoid injury during venipuncture or other invasive procedures of the cubital fossa.

Anatomy	Rheumatology/Orthopedics & Sports	Median nerve injury
Subject	System	Topic

Copyright © UWorld. All rights reserved.

6
7
8
9
10
11
12
13
14
15
16
17
18
19
20
21
22
23
24
25
26
27
28
29
30
31
32
33
34
35
36

muscle

Radial nerve

Exhibit Display

Arteries of the upper limb

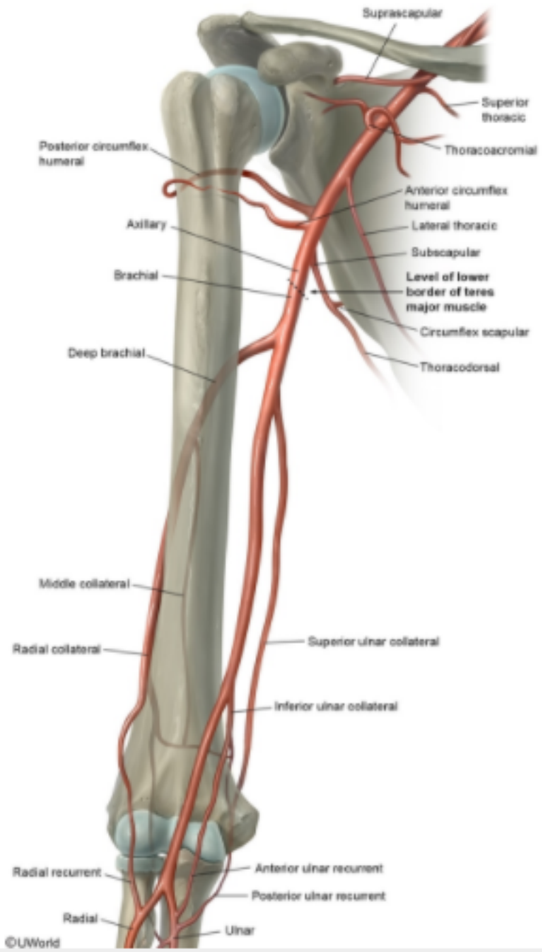

Zoom In Zoom Out Reset Add To Flash Card

6
7
8
9
10
11
12
13
14
15
16
17
18
19
20
21
22
23
24
25
26
27
28
29
30
31
32
33
34
35
36

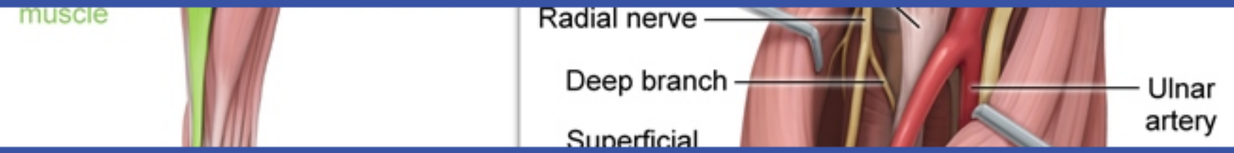

This patient's **cubita**
proximal interphalar
artery is adjacent t

The brachial artery i
brachial artery cours
brachial artery) and
median nerve acco
where the brachial a

(Choice A) The ant
the deep volar forea

(Choice C) The de
vulnerable to injury

(Choices D and E)
ascends in proximity

Exhibit Display

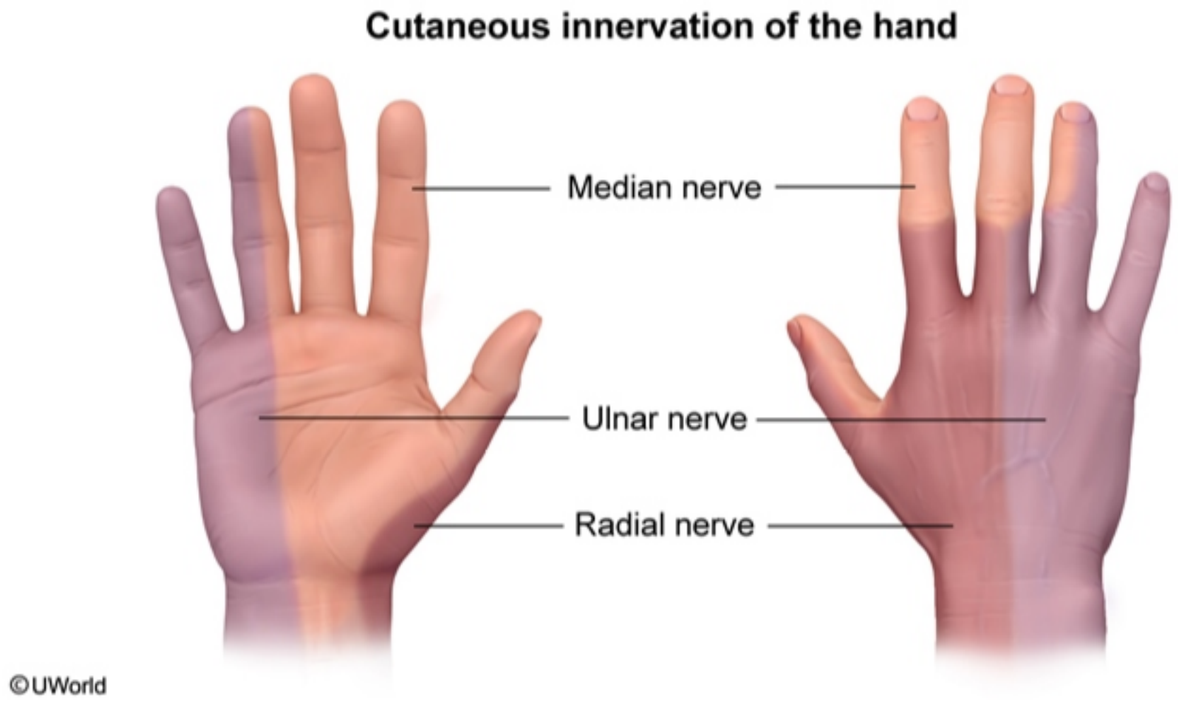

Zoom In
Zoom Out
Reset
Add To Flash Card

6
7
8
9
10
11
12
13
14
15
16
17
18
19
20
21
22
23
24
25
26
27
28
29
30
31
32
33
34
35
36

muscle

Radial nerve

Exhibit Display

Nerves and arteries of the upper extremity

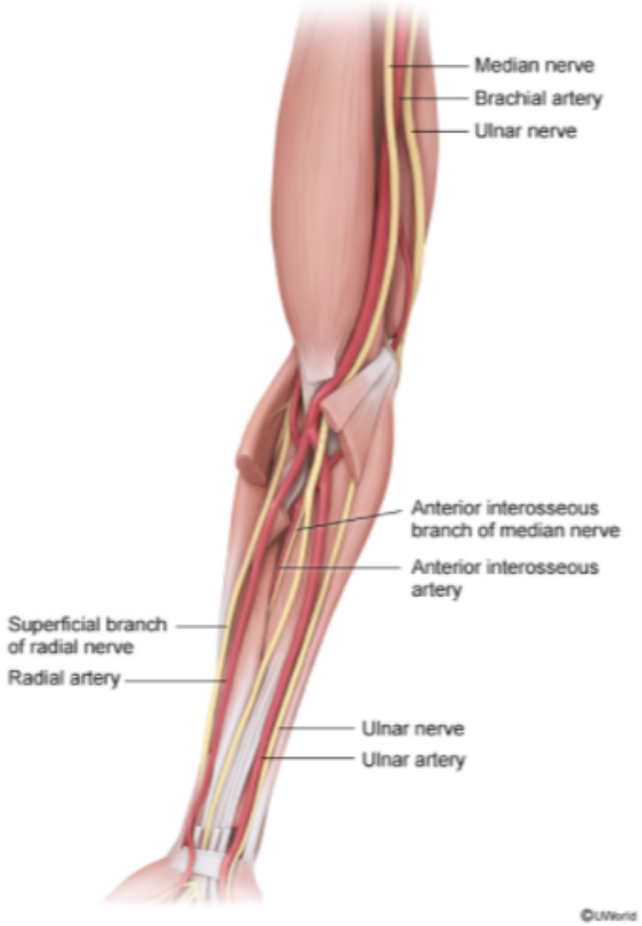

Zoom In
Zoom Out
Reset
Add To Flash Card

6
7
8
9
10
11
12
13
14
15
16
17
18
19
20
21
22
23
24
25
26
27
28
29
30
31
32
33
34
35
36

This patient's **cubital fossa laceration** has resulted in **median nerve injury**, leading to impairment of forearm pronation (pronator teres) and proximal interphalangeal joint flexion (flexor digitorum superficialis), along with sensory deficits in the median distribution. Because the **brachial**

Exhibit Display

Arteries of the upper limb

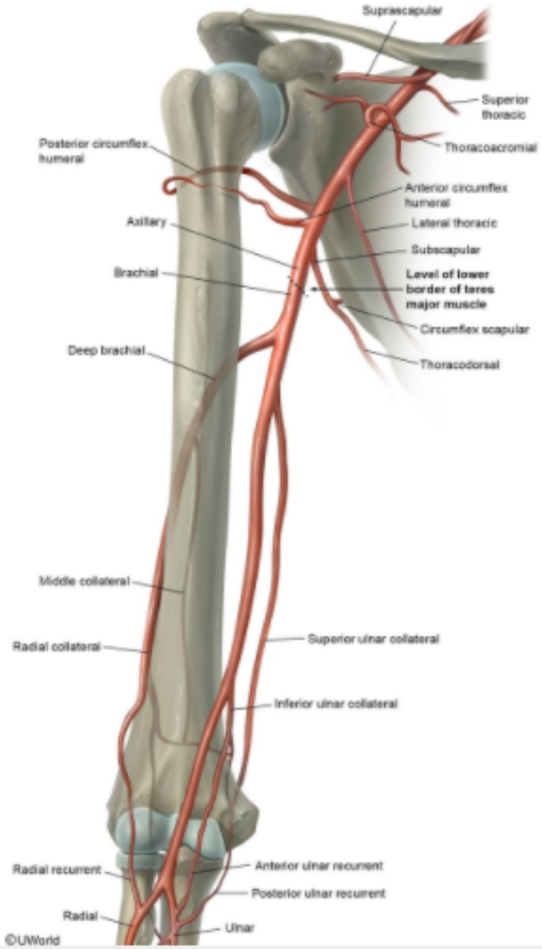

Zoom In Zoom Out Reset Add To Flash Card

cubital fossa.

6
7
8
9
10
11
12
13
14
15
16
17
18
19
20
21
22
23
24
25
26
27
28
29
30
31
32
33
34
35
36

This patient's **cubital fossa laceration** has resulted in **median nerve injury**, leading to impairment of forearm pronation (pronator teres) and proximal interphalangeal joint flexion (flexor digitorum superficialis), along with sensory deficits in the median distribution. Because the **brachial**

Exhibit Display

Arteries of the upper limb

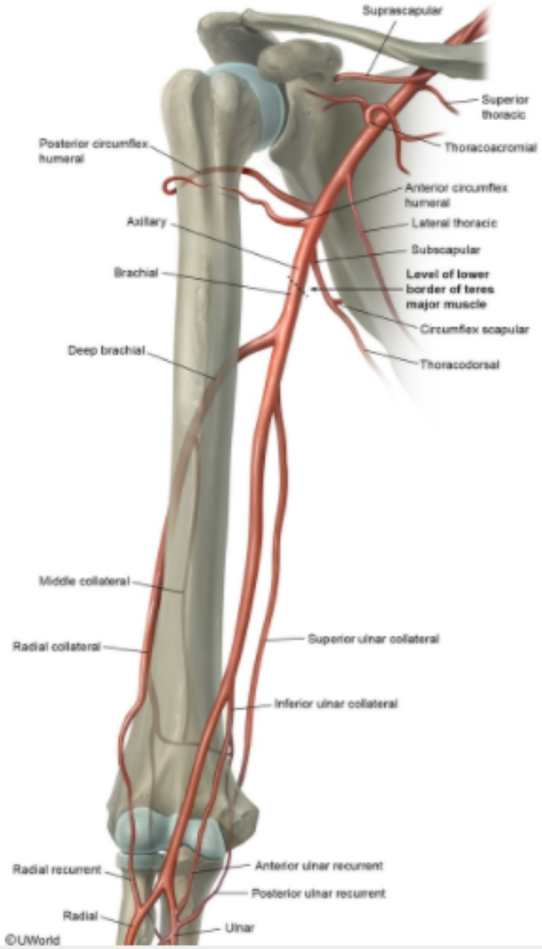

Zoom In Zoom Out Reset Add To Flash Card

cubital fossa.

This patient's **cubital fossa laceration** has resulted in **median nerve injury**, leading to impairment of forearm pronation (pronator teres) and proximal interphalangeal joint flexion (flexor digitorum superficialis), along with sensory deficits in the median distribution. Because the **brachial**

Exhibit Display

Nerves and arteries of the upper extremity

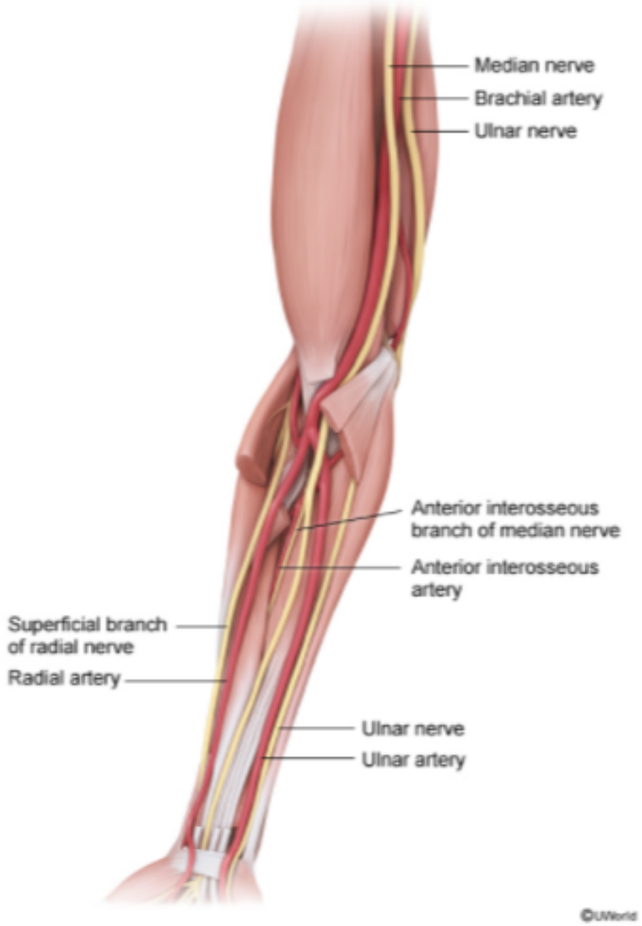

Zoom In
Zoom Out
Reset
Add To Flash Card

cubital fossa.

artery is adjacent to the median nerve at the cubital fossa, injury to the brachial artery was most likely responsible for this patient's bleeding.

Exhibit Display

Nerves and arteries of the upper extremity

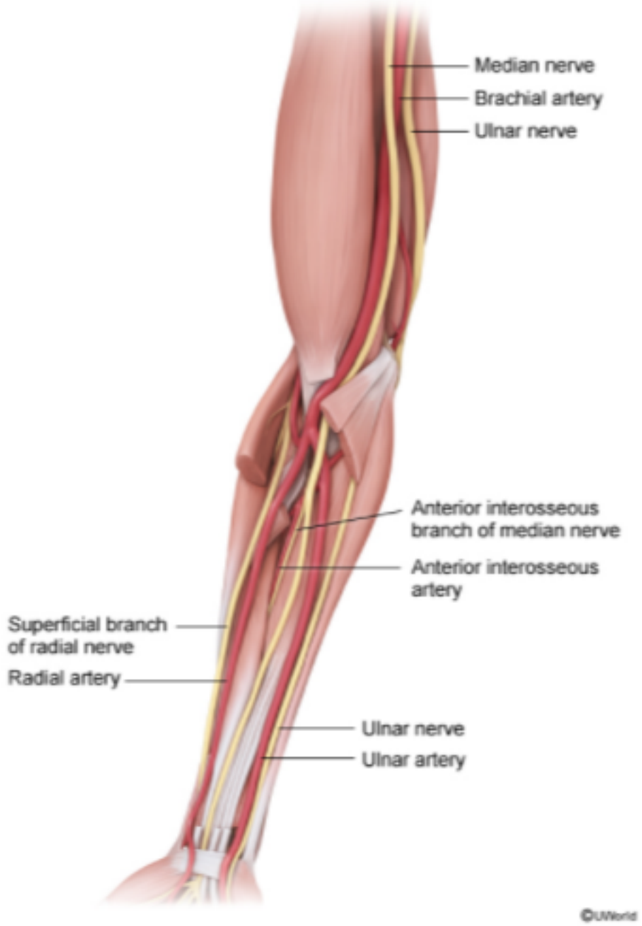

Zoom In Zoom Out Reset Add To Flash Card

Anatomy Rheumatology/Orthopedics & Sports Median nerve injury

6
7
8
9
10
11
12
13
14
15
16
17
18
19
20
21
22
23
24
25
26
27
28
29
30
31
32
33
34
35
36

A 12-year-old girl is brought to the emergency department following a sports injury involving the right lower extremity. The patient was playing soccer when she jumped and turned to the right to avoid being kicked by another player. She landed on her right foot with her foot internally rotated and her knee extended. Since the injury, the patient has been able to bear weight but says the knee feels unstable and she is afraid that it may give way, causing her to fall. Physical examination shows swelling of the right knee. Stability testing shows excessive anterior translation of the tibia relative to the femur. Which of the following ligaments is most likely injured?

A. Anterior cruciate
B. Fibular (lateral) collateral
C. Oblique popliteal
D. Patellar
E. Posterior cruciate
F. Tibial (medial) collateral

Submit

6
7
8
9
10
11
12
13
14
15
16
17
18
19
20
21
22
23
24
25
26
27
28
29
30
31
32
33
34
35
36

A 12-year-old girl is brought to the emergency department following a sports injury involving the right lower extremity. The patient was playing soccer when she jumped and turned to the right to avoid being kicked by another player. She landed on her right foot with her foot internally rotated and her knee extended. Since the injury, the patient has been able to bear weight but says the knee feels unstable and she is afraid that it may give way, causing her to fall. Physical examination shows swelling of the right knee. Stability testing shows excessive anterior translation of the tibia relative to the femur. Which of the following ligaments is most likely injured?

- ✓ A. Anterior cruciate (87%)
- B. Fibular (lateral) collateral (2%)
- C. Oblique popliteal (0%)
- D. Patellar (1%)
- E. Posterior cruciate (6%)
- F. Tibial (medial) collateral (1%)

Omitted
Correct answer
A

87%
Answered correctly

02 secs
Time Spent

01/12/2020
Last Updated

Explanation

6
7
8
9
10
11
12
13
14
15
16
17
18
19
20
21
22
23
24
25
26
27
28
29
30
31
32
33
34
35
36

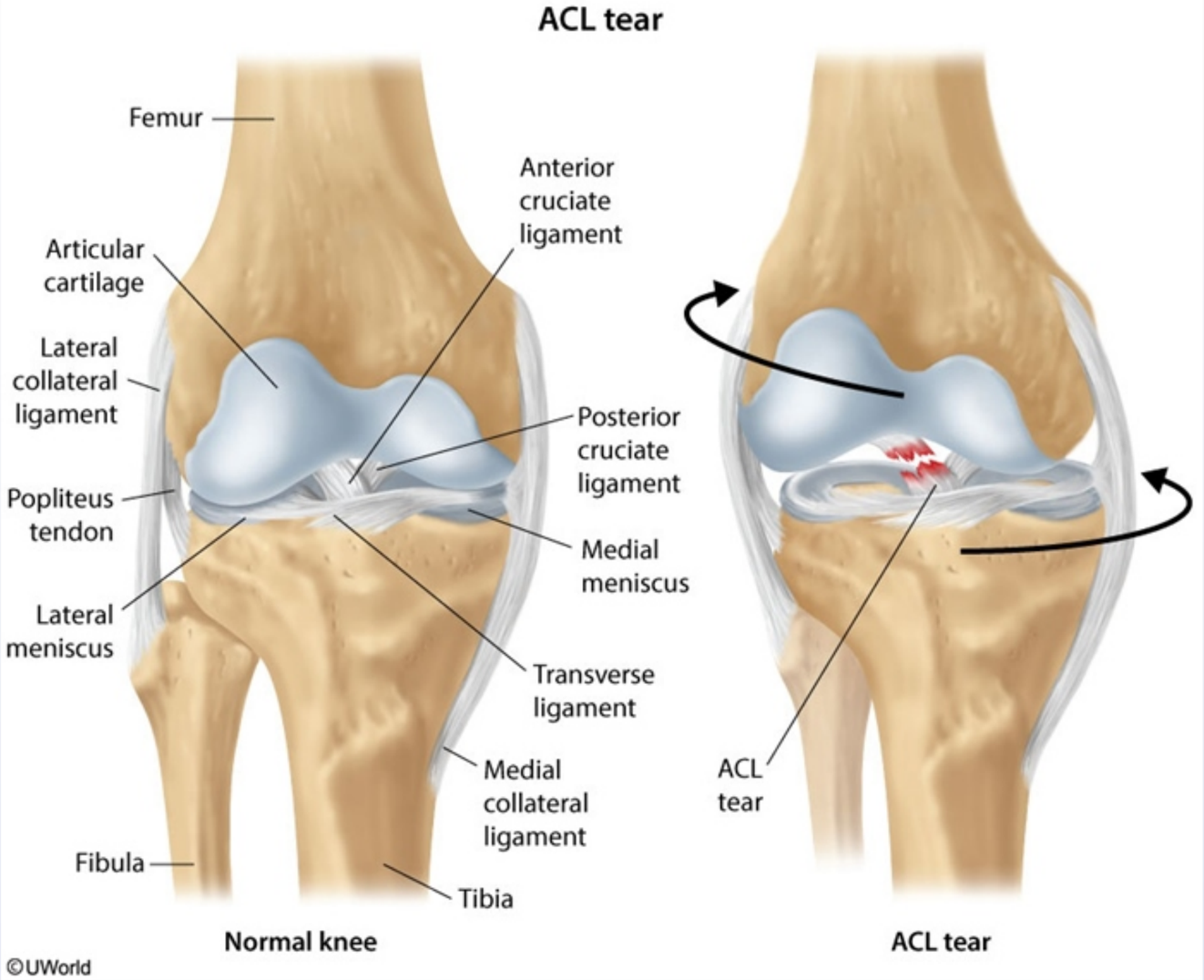

The **anterior cruciate ligament** (ACL) originates on the lateral femoral condyle and courses anteriorly and medially to insert on the anterior intercondylar area of the tibia. The primary function of the ACL is to **prevent anterior motion** of the tibia with respect to the femur, although it also plays a role in stabilizing the knee against rotatory and varus/valgus forces.

The **anterior cruciate ligament** (ACL) originates on the lateral femoral condyle and courses anteriorly and medially to insert on the anterior intercondylar area of the tibia. The primary function of the ACL is to **prevent anterior motion** of the tibia with respect to the femur, although it also plays a role in stabilizing the knee against rotatory and varus/valgus forces.

The ACL is most commonly ruptured in noncontact sports that involve sudden changes in direction or excessive internal rotation or lateral (valgus) bending forces when landing from a jump. The middle geniculate artery provides the primary blood supply to the ACL, and injuries are characterized by rapid-onset **hemarthrosis** and knee swelling. In addition to the effusion, examination typically shows **anterior laxity** of the tibia relative to the femur (eg, Lachman test, anterior drawer test).

(Choices B and F) The tibial (medial) collateral ligament is most commonly injured by impacts to the lateral knee. The fibular (lateral) collateral ligament is only rarely injured but may be injured by a forceful blow to the medial knee while the leg is extended. Injury to these ligaments is characterized by laxity of valgus or varus stress, respectively.

(Choice C) The oblique popliteal ligament is a wide, fibrous band that connects the posterior distal femur to the posterior proximal tibia. It has small openings for nerves, vessels, and muscle insertions. Injury would allow laxity of knee hyperextension.

(Choice D) The patellar ligament (tendon) is a very robust structure that represents the inferior projection of the quadriceps femoris tendon. Injury causes impaired knee extension.

(Choice E) The posterior cruciate ligament extends from the medial condyle of the femur to the posterior head of the tibia. Injury causes laxity of posterior movement of the tibia with respect to the femur (eg, posterior drawer test).

Educational objective:
The anterior cruciate ligament (ACL) can be damaged by sudden changes in direction or awkward landings (eg, excessive internal rotation or valgus stress) during sports activity. ACL tears are typically associated with rapid-onset hemarthrosis. Physical examination shows anterior laxity of the tibia relative to the femur (eg, Lachman test, anterior drawer test).

Anatomy	Rheumatology/Orthopedics & Sports	Knee trauma
Subject	System	Topic

Copyright © UWorld. All rights reserved.

6
7
8
9
10
11
12
13
14
15
16
17
18
19
20
21
22
23
24
25
26
27
28
29
30
31
32
33
34
35
36

The **anterior cruciate ligament** (ACL) originates on the lateral femoral condyle and courses anteriorly and medially to insert on the anterior

Exhibit Display

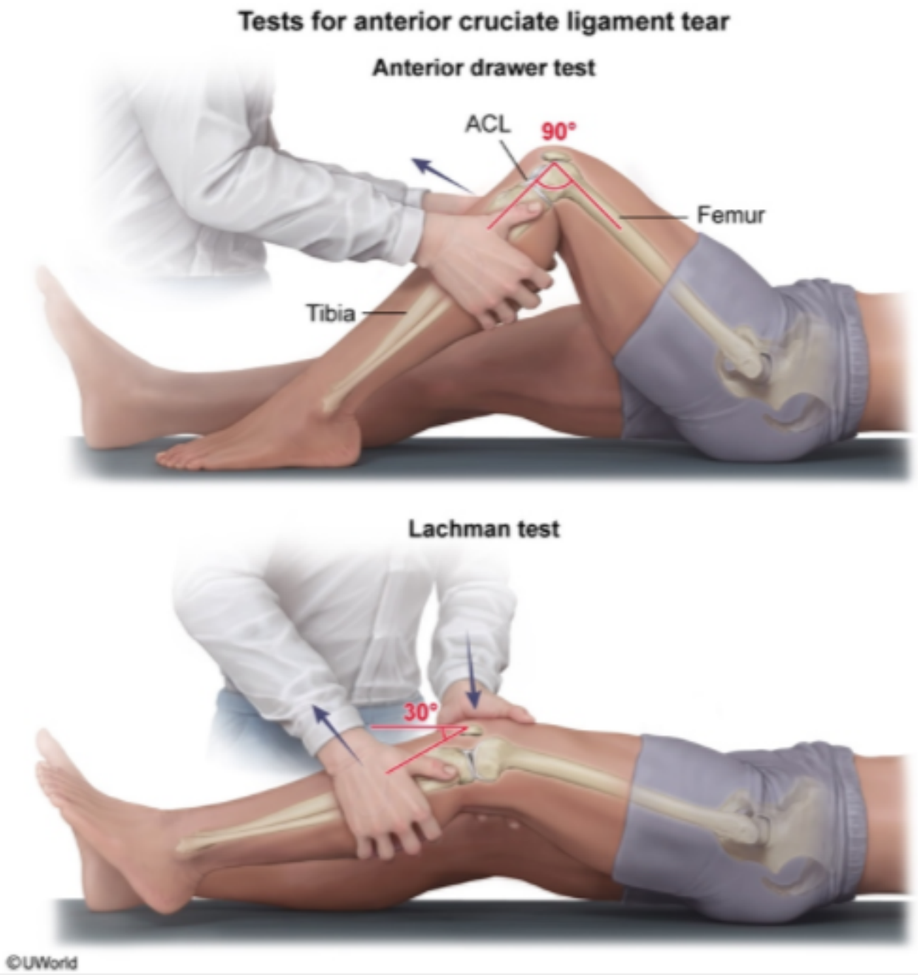

Zoom In | Zoom Out | Reset | Add To New Card | Existing Card

The **anterior cruciate ligament** (ACL) originates on the lateral femoral condyle and courses anteriorly and medially to insert on the anterior

Exhibit Display

Medial collateral ligament injury

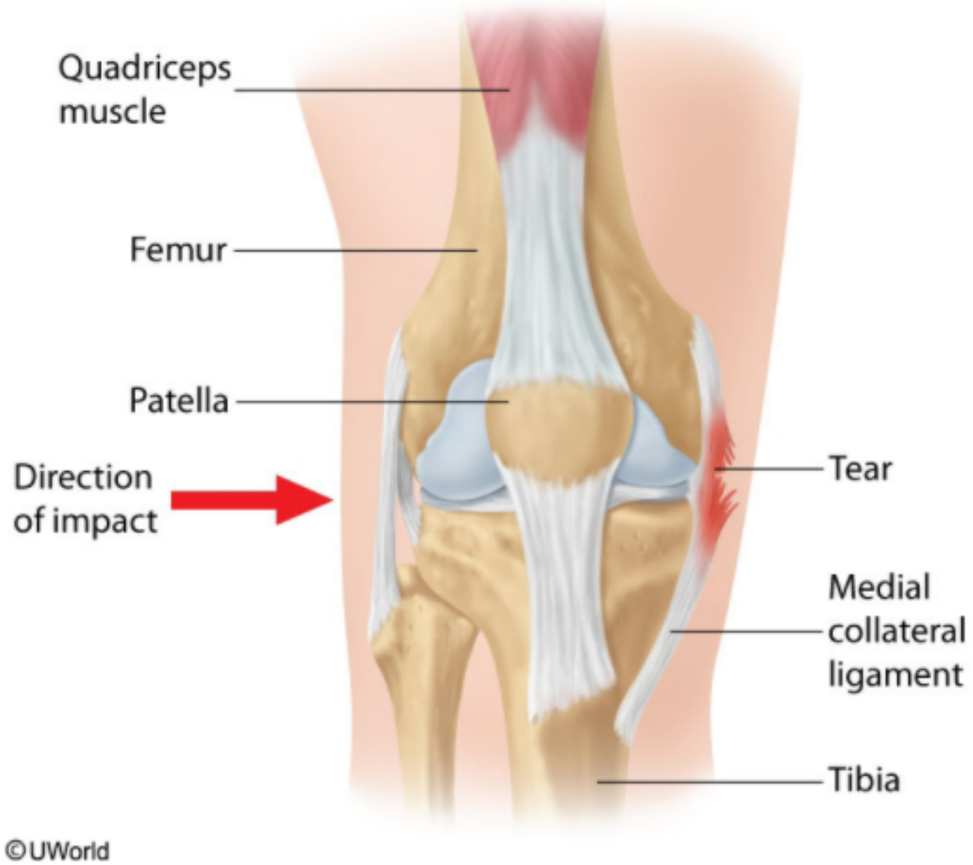

©UWorld

Zoom In | Zoom Out | Reset | Add To New Card | Existing Card

The **anterior cruciate ligament** (ACL) originates on the lateral femoral condyle and courses anteriorly and medially to insert on the anterior

Exhibit Display

Knee: posterior view

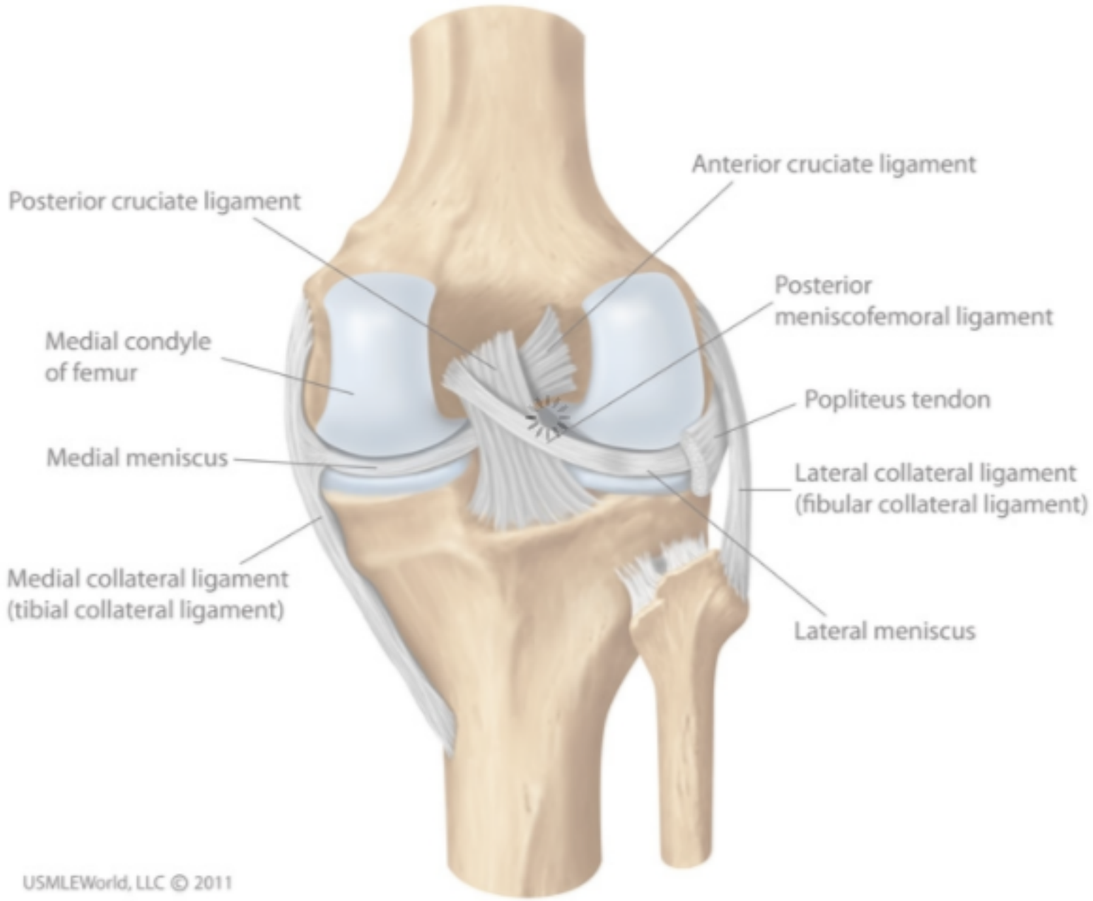

Zoom In | Zoom Out | Reset | Add To New Card | Existing Card

The **anterior cruciate ligament** (ACL) originates on the lateral femoral condyle and courses anteriorly and medially to insert on the anterior

Exhibit Display

Knee: posterior view

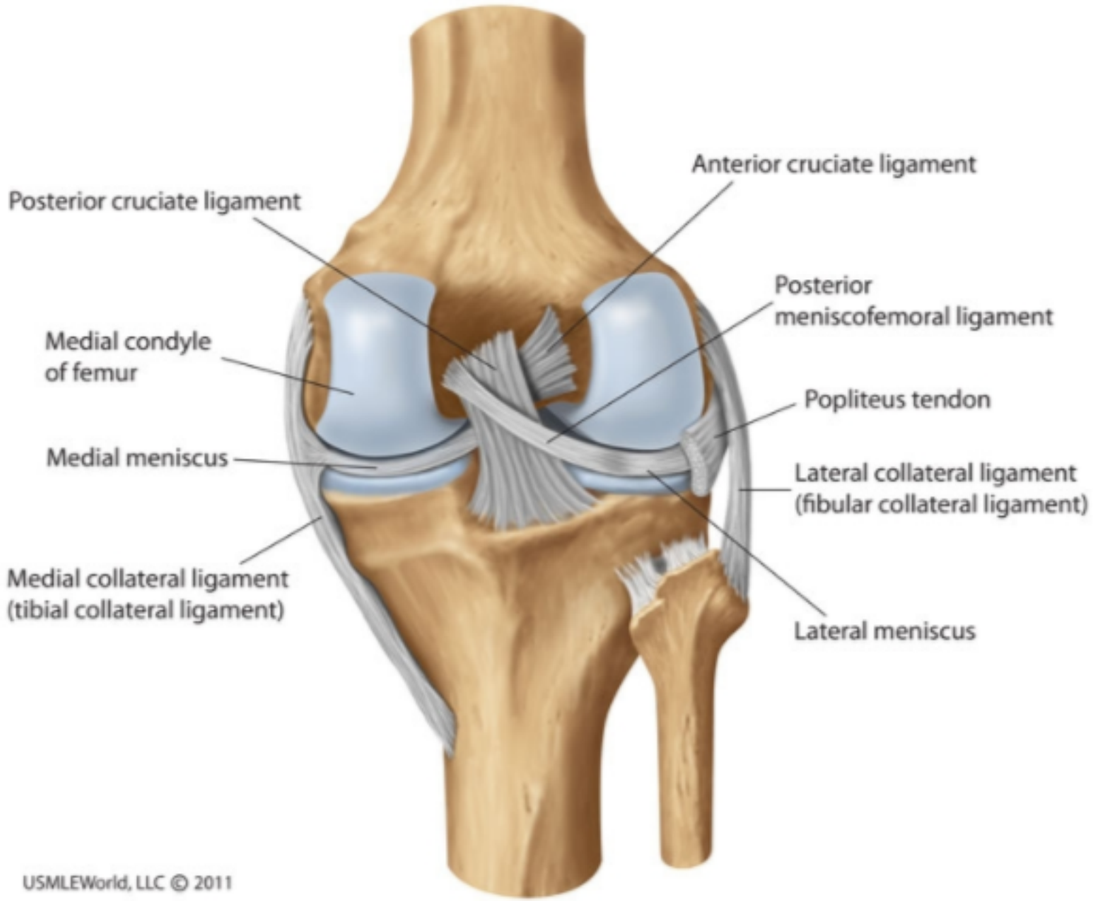

Zoom In | Zoom Out | Reset | Add To New Card | Existing Card

6
7
8
9
10
11
12
13
14
15
16
17
18
19
20
21
22
23
24
25
26
27
28
29
30
31
32
33
34
35
36

A 32-year-old male presents to the ER with sudden-onset heart palpitations. His blood pressure is 100/70 mmHg, and his heart rate is 160/min with regular rhythm. The physician instructs the patient to do the "Valsalva maneuver" to relieve these symptoms. Which of the following structures indicated on the pelvic CT image below is most important in performing the Valsalva maneuver?

A. A
B. B
C. C
D. D

6
7
8
9
10
11
12
13
14
15
16
17
18
19
20
21
22
23
24
25
26
27
28
29
30
31
32
33
34
35
36

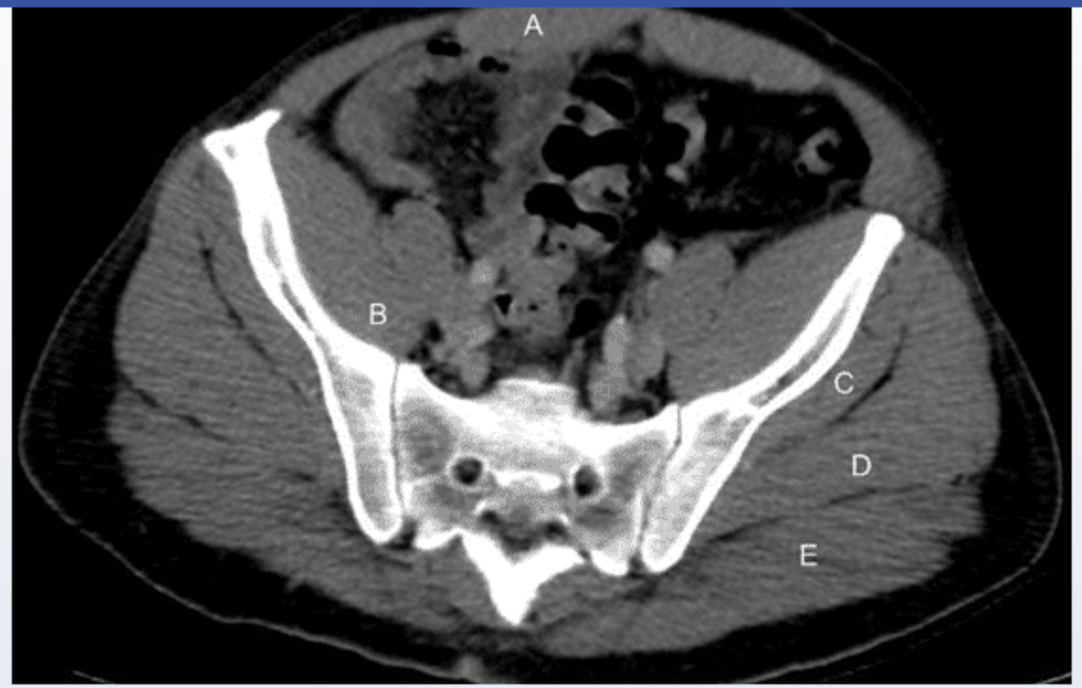

A. A

B. B

C. C

D. D

E. E

Submit

6
7
8
9
10
11
12
13
14
15
16
17
18
19
20
21
22
23
24
25
26
27
28
29
30
31
32
33
34
35
36

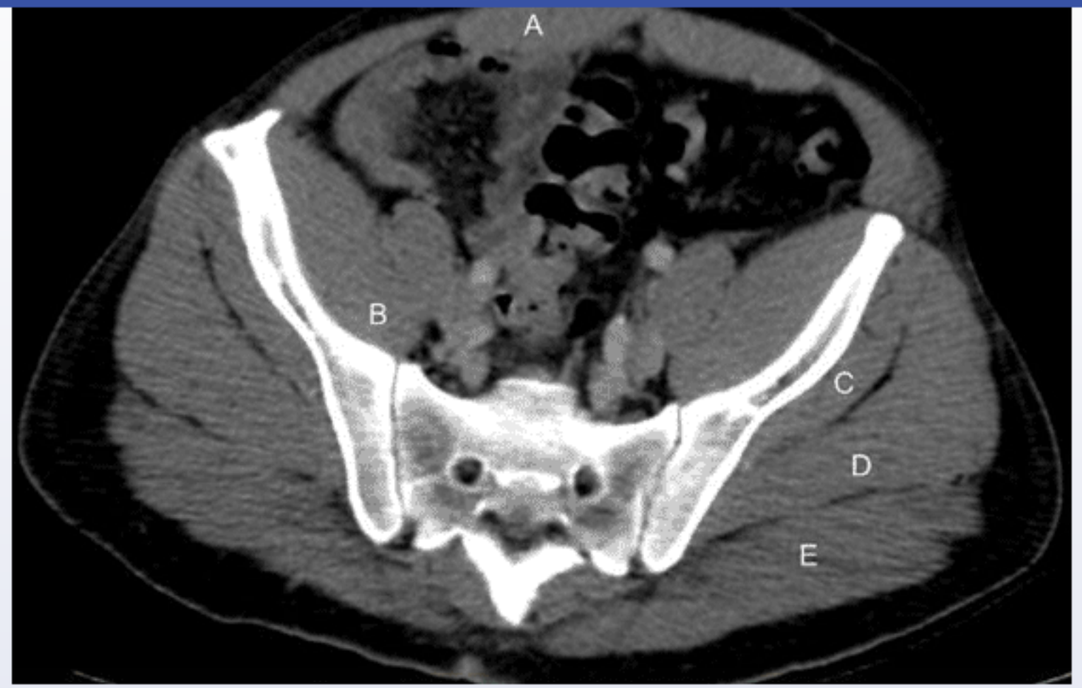

- ✓ A. A (75%)
- B. B (15%)
- C. C (2%)
- D. D (2%)
- E. E (3%)

Omitted
Correct answer

75%
Answered correctly

04 secs
Time Spent

02/03/2020
Last Updated

6
7
8
9
10
11
12
13
14
15
16
17
18
19
20
21
22
23
24
25
26
27
28
29
30
31
32
33
34
35
36

Explanation

The patient described in the question stem is experiencing paroxysmal supraventricular tachycardia. Treatment can be with vagal stimulation, such as carotid sinus massage or the Valsalva maneuver. Maneuvers that increase vagal tone increase the refractory period in the AV node and help prevent a reentrant circuit from conducting. If Valsalva measures fail, intravenous administration of adenosine is recommended.

The Valsalva maneuver is executed by forcibly exhaling against a closed glottis. This is done by taking a full inhalation, closing the glottis (i.e. holding one's breath), and subsequently bearing down-without exhaling-as one would during a bowel movement. The rectus muscles are recruited in this process, and they **(Choice A)** play the largest role in the development of the resultant elevated intraabdominal and intrathoracic pressure during this maneuver.

(Choice B) This structure is the iliacus muscle, a flexor of the hip that lies over the iliac fossa.

(Choice C) This structure is the gluteus minimus muscle. This muscle is innervated by the superior gluteal nerve and has the subtle, but important function of preventing the contralateral (non-weight-bearing) side of the pelvis from dipping when that leg is elevated off of the ground, as when one walks.

(Choice D) This structure is the gluteus medius muscle. This muscle has the same innervation and function as the gluteus minimus.

(Choice E) This structure is the gluteus maximus muscle. This muscle is innervated by the inferior gluteal nerve and is the major extensor of the thigh at the hip.

Educational Objective:
The Valsalva maneuver increases vagal tone and can be used to abolish paroxysmal supraventricular tachycardia. The rectus abdominis is the most important muscle in achieving the increased intraabdominal and intrathoracic pressure of the Valsalva maneuver.

Anatomy	Rheumatology/Orthopedics & Sports	Abdominal wall muscles
Subject	System	Topic

Copyright © UWorld. All rights reserved.

6
7
8
9
10
11
12
13
14
15
16
17
18
19
20
21
22
23
24
25
26
27
28
29
30
31
32
33
34
35
36

A 30-year-old man is evaluated for 6 months of persistent pain in his right buttock and posterior thigh. He is a construction worker and has difficulty lifting heavy objects or climbing stairs. He has no history of back injury and no associated back pain. Past medical history is unremarkable. The patient does not use tobacco and drinks only moderate quantities of alcohol. On examination, the patient develops pain with forced adduction of the flexed thigh and internal rotation of the extended thigh against resistance. Further evaluation reveals possible entrapment of the sciatic nerve in the greater sciatic foramen. Which of the following structures passes through the foramen and occupies most of its volume?

- A. Coccygeus muscle
- B. Gluteus minimus muscle
- C. Obturator internus muscle
- D. Piriformis muscle
- E. Sacrospinous ligament
- F. Sacrotuberous ligament

Submit

A 30-year-old man is evaluated for 6 months of persistent pain in his right buttock and posterior thigh. He is a construction worker and has difficulty lifting heavy objects or climbing stairs. He has no history of back injury and no associated back pain. Past medical history is unremarkable. The patient does not use tobacco and drinks only moderate quantities of alcohol. On examination, the patient develops pain with forced adduction of the flexed thigh and internal rotation of the extended thigh against resistance. Further evaluation reveals possible entrapment of the sciatic nerve in the greater sciatic foramen. Which of the following structures passes through the foramen and occupies most of its volume?

- A. Coccygeus muscle (1%)
- B. Gluteus minimus muscle (7%)
- C. Obturator internus muscle (24%)
- ✓ D. Piriformis muscle (56%)
- E. Sacrospinous ligament (5%)
- F. Sacrotuberous ligament (4%)

Omitted
Correct answer
D

56%
Answered correctly

02 secs
Time Spent

04/18/2020
Last Updated

Explanation

Greater sciatic foramen

6
7
8
9
10
11
12
13
14
15
16
17
18
19
20
21
22
23
24
25
26
27
28
29
30
31
32
33
34
35
36

Greater sciatic foramen

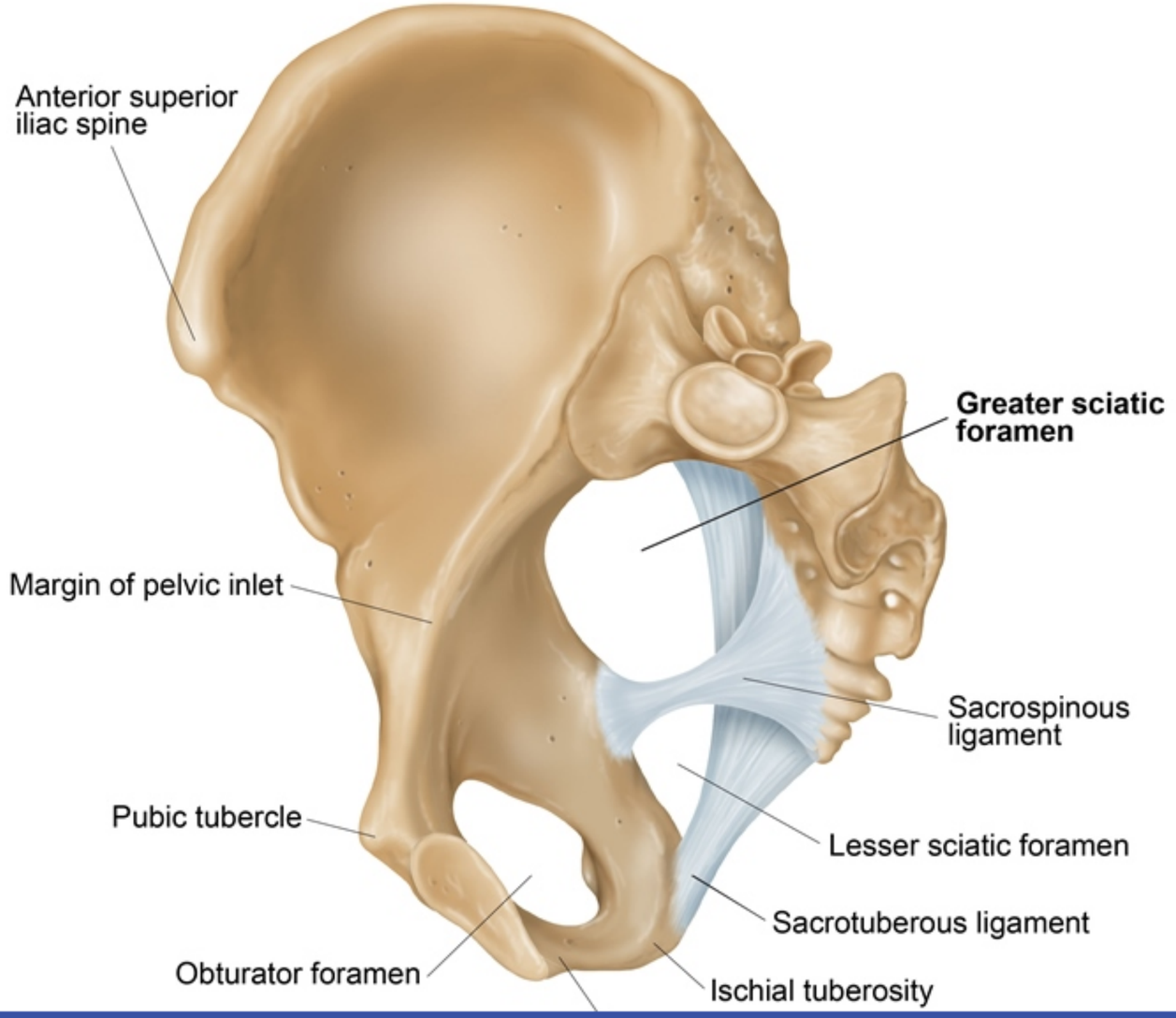

6
7
8
9
10
11
12
13
14
15
16
17
18
19
20
21
22
23
24
25
26
27
28
29
30
31
32
33
34
35
36

Ischiopubic ramus

©UWorld

The sciatic foramen is a pelvic opening serving as the major pathway for pelvic neurovascular structures to the lower limbs. It is divided into greater and lesser sciatic foramina by the sacrospinous ligament **(Choice E)**. The **greater sciatic foramen** is bordered anterolaterally by the greater sciatic notch of the ilium, inferiorly by the ischial spine and sacrospinous ligament, superiorly by the anterior sacroiliac ligament, and posteromedially by the sacrotuberous ligament **(Choice F)**.

The **piriformis** originates on the anterior aspect of the sacrum and occupies most of the space in the greater sciatic foramen. It inserts on the greater trochanter of the femur and acts to externally rotate the thigh when extended and abduct the thigh when flexed. Structures running above the piriformis include the superior gluteal vessels and superior gluteal nerve. Structures crossing below the piriformis include the inferior gluteal vessels, internal pudendal vessels, and multiple nerves (most notably the **sciatic** nerve). Muscle injury or hypertrophy can compress the sciatic nerve to cause sciatica-like symptoms (eg, pain, tingling, and numbness in the buttocks and along the nerve distribution) known as **piriformis syndrome**. The muscle can be tender with deep palpation or on stretching with adduction and internal rotation.

(Choice A) The coccygeus muscle is a pelvic floor muscle anterior to the sacrospinous ligament and combines with the levator ani to form the pelvic diaphragm.

(Choice B) The gluteus minimus is the smallest of the 3 gluteal muscles and is immediately beneath the gluteus medius. It works with the gluteus medius to stabilize the hip and abduct the thigh when the limb is extended.

(Choice C) The obturator internus is a fan-shaped muscle originating from the medial surface of the obturator membrane, ischium, and pubic rim. It exits the pelvis through the lesser sciatic foramen and inserts on the greater trochanter of the femur, where it functions similarly to the piriformis.

Educational objective:
The piriformis passes through the greater sciatic foramen and is involved with external hip rotation. Muscle injury or hypertrophy can compress the sciatic nerve in the foramen, causing piriformis syndrome.

References

- Piriformis syndrome: a cause of nondiscogenic sciatica.

6
7
8
9
10
11
12
13
14
15
16
17
18
19
20
21
22
23
24
25
26
27
28
29
30
31
32
33
34
35
36

A 21-year-old man is brought to the emergency department following an assault. He was attempting to escape and turned away just as his attacker lunged toward him from behind with a knife. The patient suffered a 4-cm-wide penetrating injury with significant associated blood loss. Following initial stabilization, he is transferred to the operating room. Surgical exploration reveals injury to a muscle that assists in internal rotation of the arm and is innervated by the thoracodorsal nerve. Which of the following muscles, as depicted in the cadaveric specimen, is most likely injured in this patient?

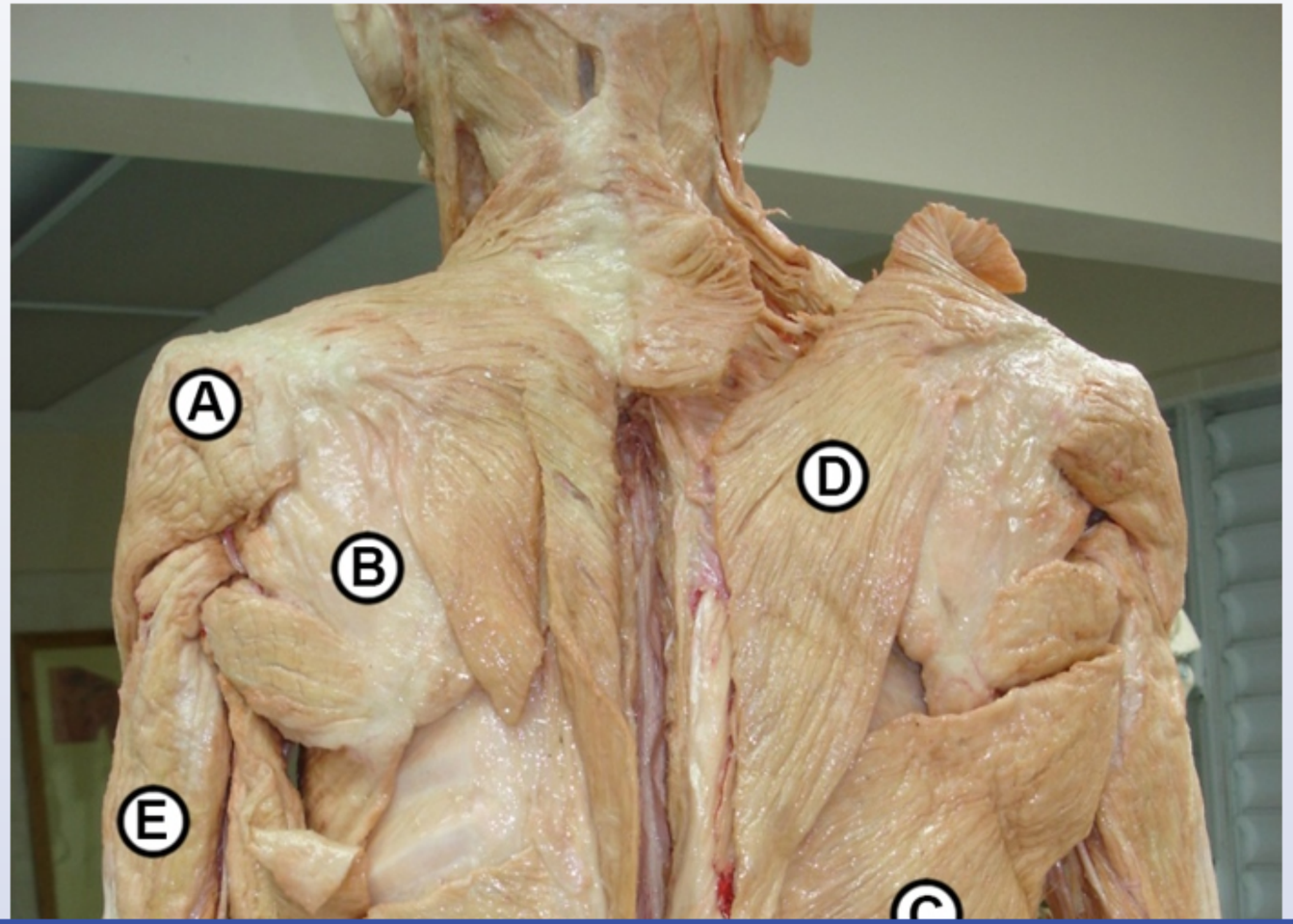

6
7
8
9
10
11
12
13
14
15
16
17
18
19
20
21
22
23
24
25
26
27
28
29
30
31
32
33
34
35
36

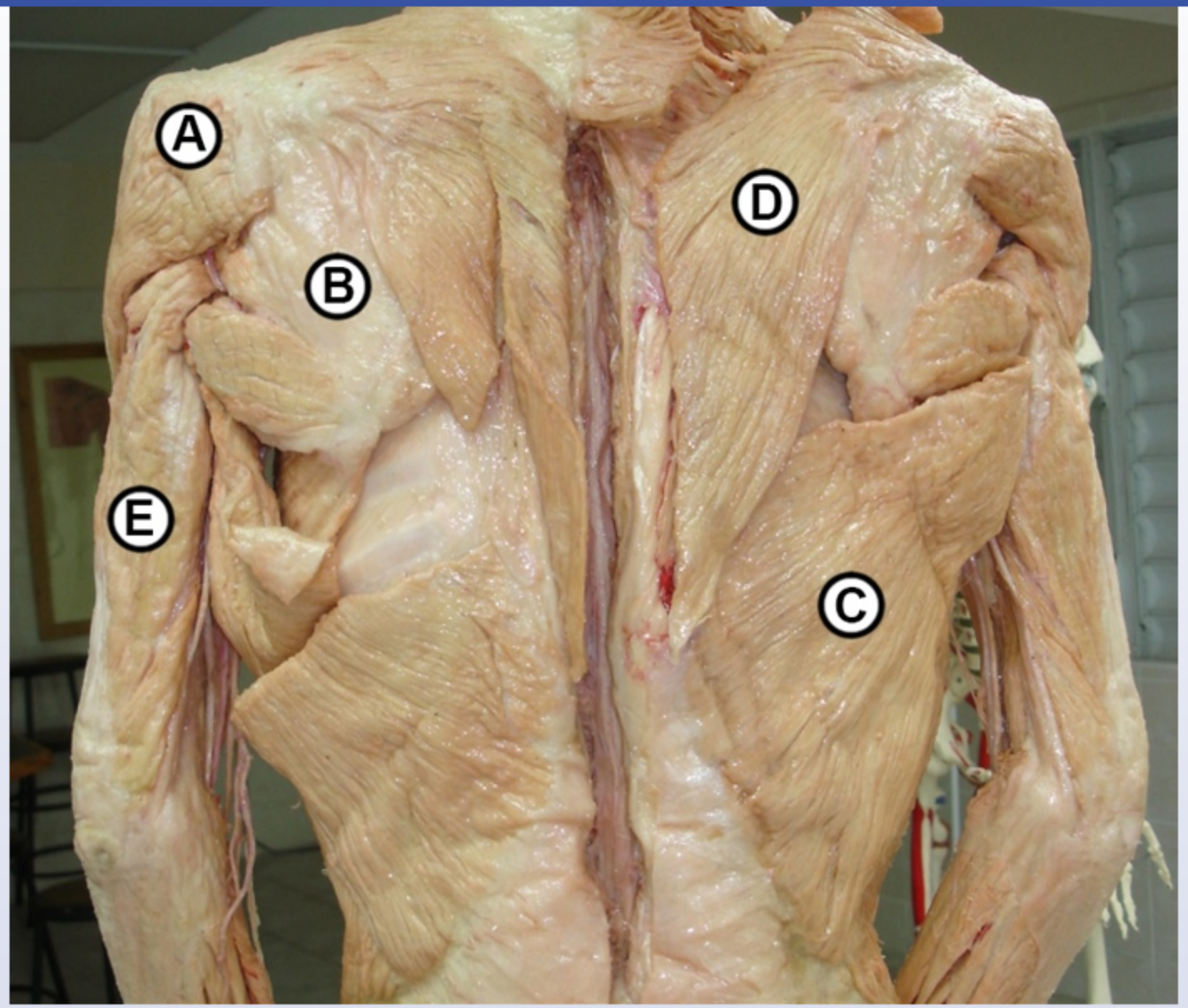

A. A

6
7
8
9
10
11
12
13
14
15
16
17
18
19
20
21
22
23
24
25
26
27
28
29
30
31
32
33
34
35
36

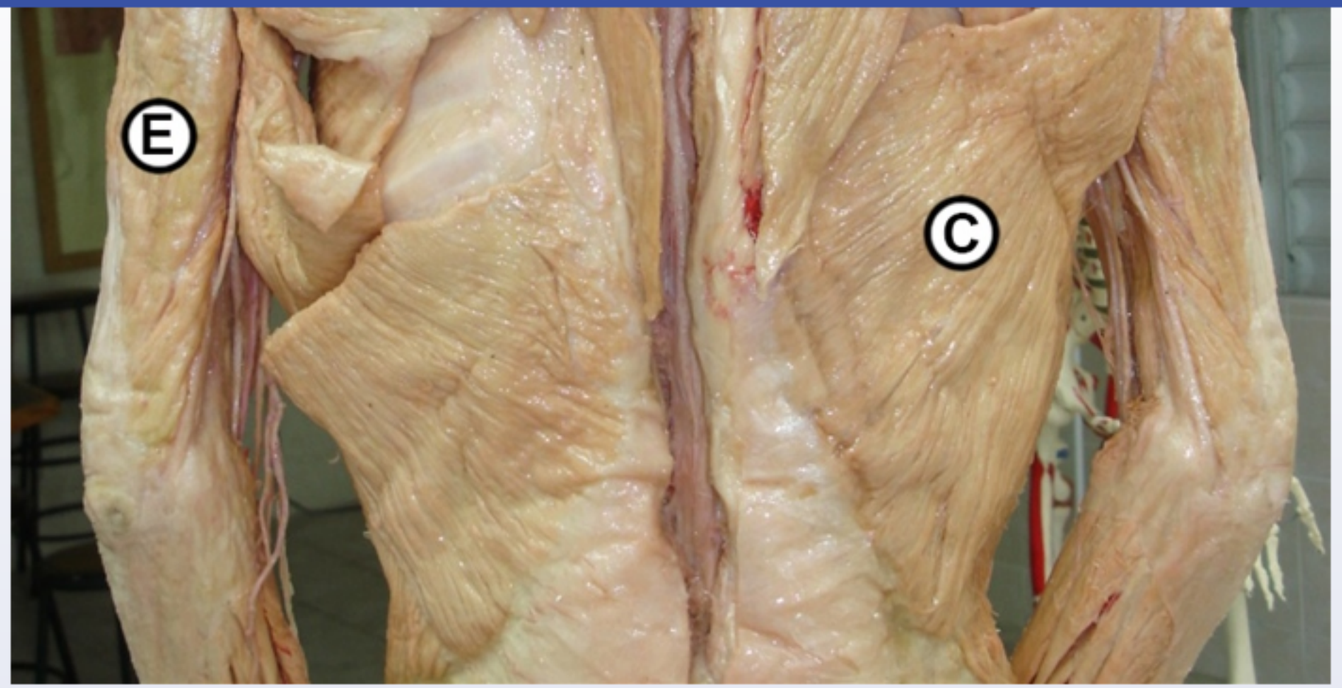

A. A

B. B

C. C

D. D

E. E

Submit

6
7
8
9
10
11
12
13
14
15
16
17
18
19
20
21
22
23
24
25
26
27
28
29
30
31
32
33
34
35
36

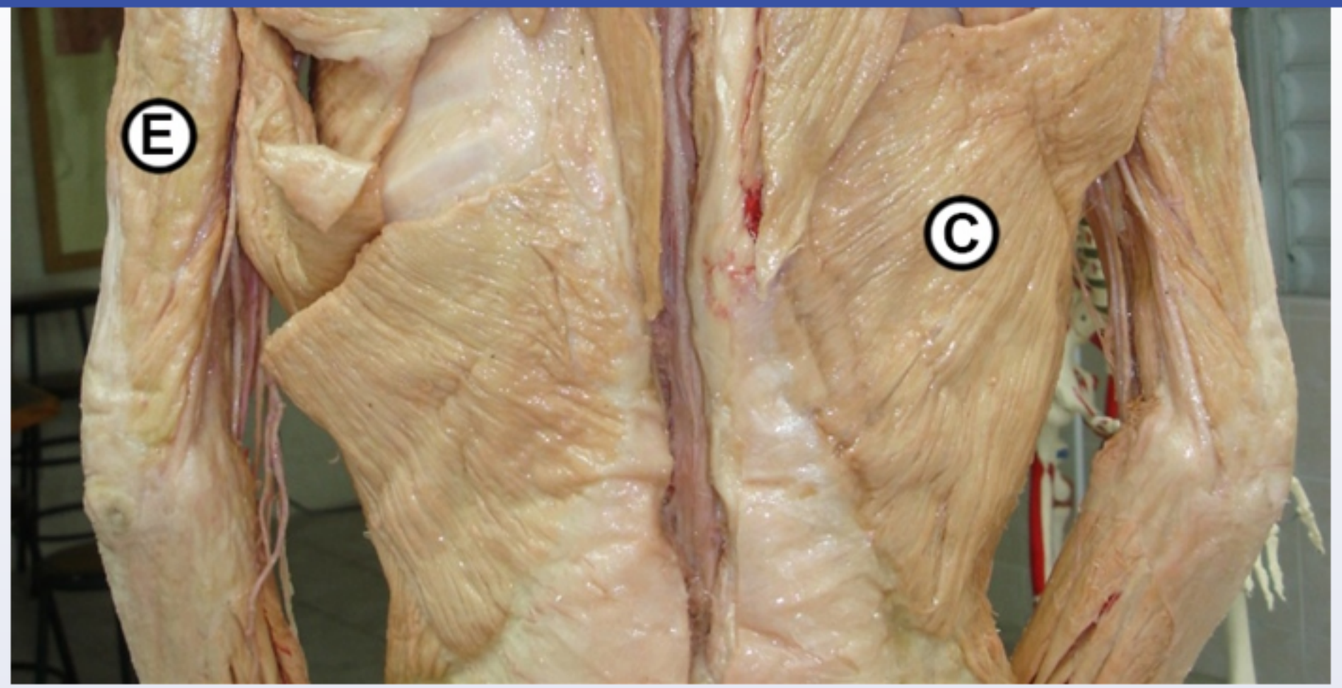

A. A (4%)

B. B (26%)

✓ C. C (56%)

D. D (11%)

E. E (0%)

Omitted
Correct answer

56%
Answered correctly

08 secs
Time Spent

03/30/2020
Last Updated

Explanation

The **latissimus dorsi** is a large thoracolumbar muscle that contributes to forceful movement of the humerus. It originates in a broad area spanning from the iliac crest and lumbar fascia to the spinous processes of T7-12 and lower ribs. It inserts at the bicipital groove of the humerus. The latissimus dorsi is innervated by the thoracodorsal nerve, with fibers originating from the C6-8 nerve roots. Primary functions include extension, adduction, and internal rotation of the humerus.

Due to its broad area and exposed location, the latissimus dorsi is vulnerable to injury from external trauma. It is also frequently injured in sports requiring forceful downward movement of the humerus, such as throwing, climbing, or swinging a tennis racket overhead.

(Choice A) The deltoid is innervated by the axillary nerve, and its primary action is abduction of the arm. It can be injured due to sudden or forceful loading of the arm while in abduction.

(Choice B) The infraspinatus is innervated by the suprascapular nerve and serves to externally rotate the arm. It is most commonly injured in association with the supraspinatus due to falls or overuse in older patients.

(Choice D) The trapezius is a large muscle in the upper back and neck that serves to elevate, rotate, and stabilize the scapula. It is primarily innervated by cranial nerve XI. The trapezius is frequently injured in rear-end ("whiplash") motor vehicle accidents.

(Choice E) The triceps is innervated by the radial nerve (C6-8, T1) and is the primary muscle involved in extension of the elbow.

Educational objective:
The latissimus dorsi is a large thoracolumbar muscle that originates from the iliac crest and lumbar fascia to the spinous processes of T7-12 and lower ribs, and inserts at the bicipital groove of the humerus. It is innervated by the thoracodorsal nerve. Primary functions include extension, adduction, and medial rotation of the humerus.

Anatomy	Rheumatology/Orthopedics & Sports	Brachial plexus
Subject	System	Topic

Copyright © UWorld. All rights reserved.

6
7
8
9
10
11
12
13
14
15
16
17
18
19
20
21
22
23
24
25
26
27
28
29
30
31
32
33
34
35
36

A 34-year-old man is evaluated in the emergency department due to difficulty walking. He was installing new shingles on his roof when he fell to the ground and sustained a puncture injury to his right leg. On physical examination, the right foot is dorsiflexed and everted. The patient is unable to stand on his tiptoes. Muscular strength at the knee and hip appear intact. Pedal and tibial pulses are +2 and symmetric. X-rays of his right leg are negative for fracture. This patient is most likely to have sensory loss over which of the following areas?

A. Anterior thigh
B. Dorsal foot
C. Medial foot
D. Medial leg
E. Plantar foot

Submit

6
7
8
9
10
11
12
13
14
15
16
17
18
19
20
21
22
23
24
25
26
27
28
29
30
31
32
33
34
35
36

A 34-year-old man is evaluated in the emergency department due to difficulty walking. He was installing new shingles on his roof when he fell to the ground and sustained a puncture injury to his right leg. On physical examination, the right foot is dorsiflexed and everted. The patient is unable to stand on his tiptoes. Muscular strength at the knee and hip appear intact. Pedal and tibial pulses are +2 and symmetric. X-rays of his right leg are negative for fracture. This patient is most likely to have sensory loss over which of the following areas?

- A. Anterior thigh (1%)
- B. Dorsal foot (16%)
- C. Medial foot (9%)
- D. Medial leg (9%)
- ✓ E. Plantar foot (62%)

Omitted
Correct answer
E

62%
Answered correctly

01 sec
Time Spent

02/08/2020
Last Updated

Explanation

Nerve	Motor function	Region of sensory loss with neuropathy
Tibial nerve	Foot plantar flexion & inversion, toe flexion	

6
7
8
9
10
11
12
13
14
15
16
17
18
19
20
21
22
23
24
25
26
27
28
29
30
31
32
33
34
35
36

Nerve	Motor function	Region of sensory loss with neuropathy
Tibial nerve	Foot plantar flexion & inversion, toe flexion	

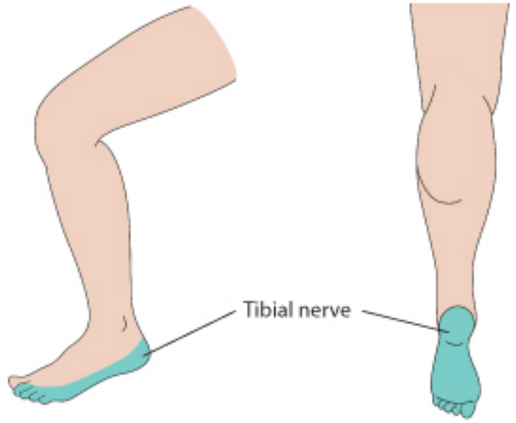

©UWorld

The **tibial nerve** is the large medial branch of the sciatic nerve and descends through the popliteal fossa together with the popliteal vein and artery. It then traverses the posterior compartment of the leg deep to the soleus muscle. After providing motor innervation to the posterior compartment muscles, the nerve enters the plantar aspect of the foot through the tarsal tunnel (between the flexor retinaculum and medial surfaces of the talus and calcaneus). Here, it divides into the medial and lateral plantar nerves, providing **sensory** innervation over the **sole** of the foot and motor innervation to the intrinsic foot muscles.

Injury to the nerve at the popliteal fossa (eg, deep penetrating trauma, knee surgery) can cause weakness on **foot plantarflexion** because the nerve innervates the gastrocnemius, soleus, and plantaris muscles. Weakness may also be evident on foot **inversion** (eg, tibialis posterior muscle) and **toe flexion** (eg, flexor digitorum longus and flexor hallucis longus muscles). Consequently, patients often present with the foot held in a calcaneovalgus position (eg, dorsiflexed and everted). In contrast, injury to the tibial nerve at the tarsal tunnel may cause sensory loss over the sole with intrinsic foot muscle weakness. However, plantarflexion and inversion remain intact as fibers innervating these muscles branch off more proximally.

(Choice A) The cutaneous branches of the femoral nerve innervate most of the skin over the anterior thigh.

(Choice B) The superficial peroneal nerve innervates the lateral leg and dorsum of the foot, except for the skin between the great toe and second

Injury to the nerve at the popliteal fossa (eg, deep penetrating trauma, knee surgery) can cause weakness on **foot plantarflexion** because the nerve innervates the gastrocnemius, soleus, and plantaris muscles. Weakness may also be evident on foot **inversion** (eg, tibialis posterior muscle) and **toe flexion** (eg, flexor digitorum longus and flexor hallucis longus muscles). Consequently, patients often present with the foot held in a calcaneovalgus position (eg, dorsiflexed and everted). In contrast, injury to the tibial nerve at the tarsal tunnel may cause sensory loss over the sole with intrinsic foot muscle weakness. However, plantarflexion and inversion remain intact as fibers innervating these muscles branch off more proximally.

(Choice A) The cutaneous branches of the femoral nerve innervate most of the skin over the anterior thigh.

(Choice B) The superficial peroneal nerve innervates the lateral leg and dorsum of the foot, except for the skin between the great toe and second toe, which is innervated by the deep peroneal nerve.

(Choice C) The medial aspect of the foot is innervated by the superficial peroneal nerve, a branch of the common peroneal nerve, and by the saphenous nerve.

(Choice D) Cutaneous branches of the saphenous nerve innervate the skin of the medial leg. The saphenous nerve is a branch of the femoral nerve and courses to the medial leg together with the great saphenous vein.

Educational objective:
The tibial nerve may be injured at the level of the popliteal fossa due to deep penetrating trauma or knee surgery. Patients typically have weakness on foot plantarflexion, foot inversion, and toe flexion, with sensory loss over the sole.

References

- Entrapment neuropathies of the lower extremity.
- Lower extremity nerve trauma.

Anatomy	Rheumatology/Orthopedics & Sports	Tibial nerve injury
Subject	System	Topic

Copyright © UWorld. All rights reserved.

Injury to the nerve at the popliteal fossa (eg, deep penetrating trauma, knee surgery) can cause weakness on **foot plantarflexion** because the

Exhibit Display

Important nerves in the leg

Nerve	Motor function	Region of sensory loss with neuropathy
Femoral nerve	Leg flexion at the hip, leg extension at the knee	

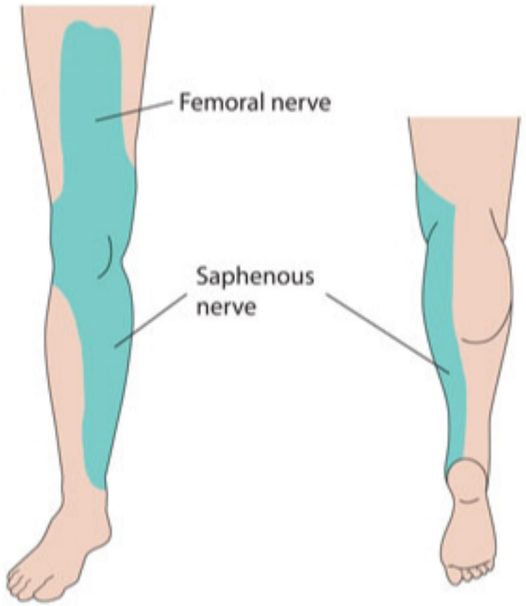

©UWorld

Zoom In | Zoom Out | Reset | Add To New Card | Existing Card

Injury to the nerve at the popliteal fossa (eg, deep penetrating trauma, knee surgery) can cause weakness on **foot plantarflexion** because the

Exhibit Display

Nerve	Motor function	Cutaneous innervation
Superficial peroneal nerve	Foot eversion	

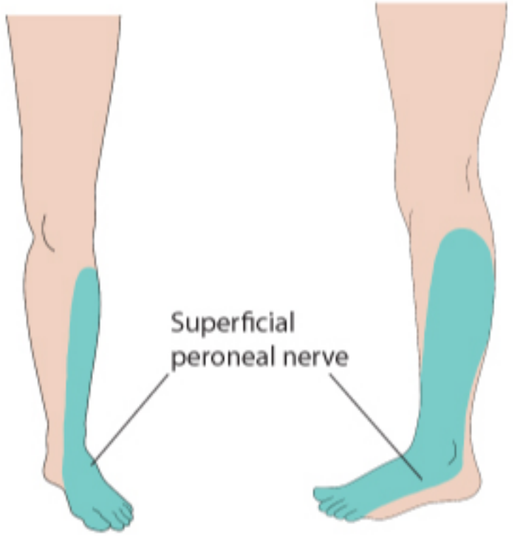

©UWorld

Zoom In | Zoom Out | Reset | Add To New Card | Existing Card

6
7
8
9
10
11
12
13
14
15
16
17
18
19
20
21
22
23
24
25
26
27
28
29
30
31
32
33
34
35
36

Injury to the nerve at the popliteal fossa (eg, deep penetrating trauma, knee surgery) can cause weakness on **foot plantarflexion** because the

Exhibit Display

Important nerves in the leg

Nerve	Motor function	Region of sensory loss with neuropathy
Deep peroneal nerve	Foot dorsiflexion, toe extension	

©UWorld

Zoom In | Zoom Out | Reset | Add To New Card | Existing Card

Injury to the nerve at the popliteal fossa (eg, deep penetrating trauma, knee surgery) can cause weakness on **foot plantarflexion** because the

Exhibit Display

Important nerves in the leg

Nerve	Motor function	Region of sensory loss with neuropathy
Deep peroneal nerve	Foot dorsiflexion, toe extension	

©UWorld

Zoom In | Zoom Out | Reset | Add To New Card | Existing Card

6
7
8
9
10
11
12
13
14
15
16
17
18
19
20
21
22
23
24
25
26
27
28
29
30
31
32
33
34
35
36

A 16-year-old boy comes to the emergency department due to right knee pain after a fall. His symptoms started after a ski accident in which he twisted the right lower leg outward relative to the thigh. He has no medical conditions and currently takes no medications. On examination, there is swelling and tenderness on the medial aspect of the right knee. Widening of the medial joint line can be felt when a gentle force is applied to the lateral knee with the lower leg kept stationary. Which of the following labelled structures is most likely injured in this patient?

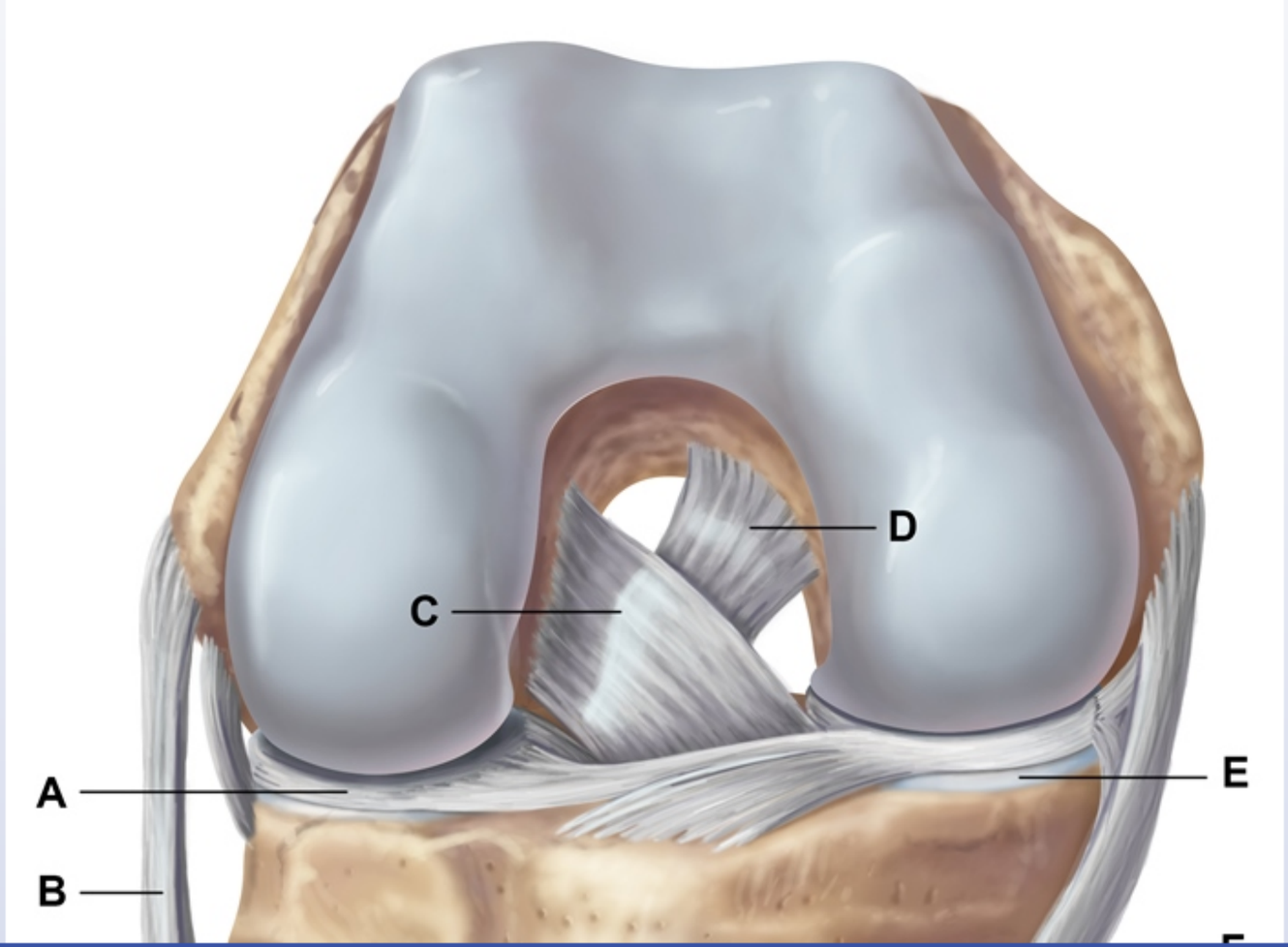

6
7
8
9
10
11
12
13
14
15
16
17
18
19
20
21
22
23
24
25
26
27
28
29
30
31
32
33
34
35
36

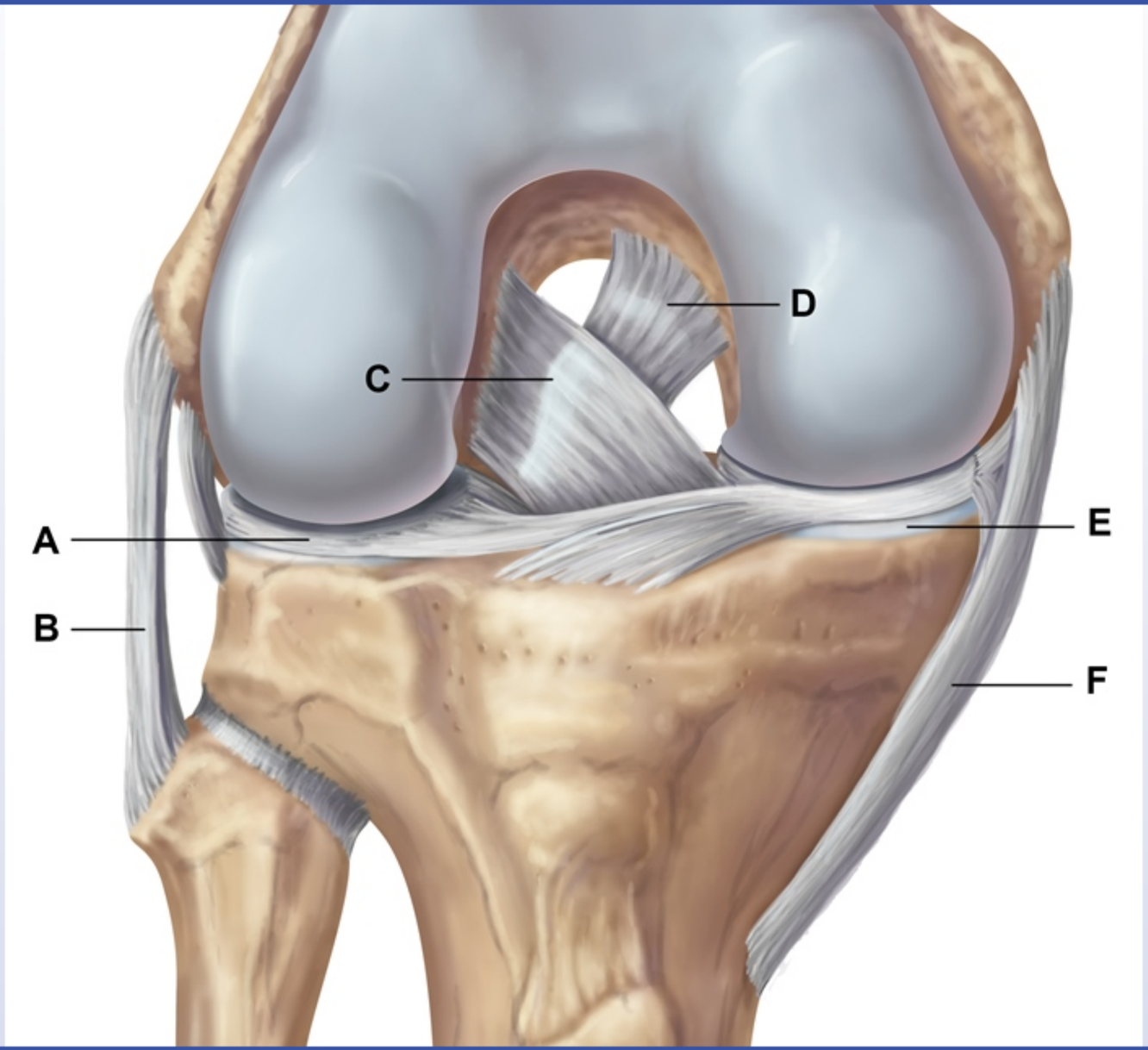

6
7
8
9
10
11
12
13
14
15
16
17
18
19
20
21
22
23
24
25
26
27
28
29
30
31
32
33
34
35
36

A. A

B. B

C. C

D. D

E. E

F. F

Submit

6
7
8
9
10
11
12
13
14
15
16
17
18
19
20
21
22
23
24
25
26
27
28
29
30
31
32
33
34
35
36

A. A (2%)

B. B (10%)

C. C (3%)

D. D (1%)

E. E (6%)

✓ F. F (75%)

Omitted
Correct answer

75%
Answered correctly

10 secs
Time Spent

05/30/2020
Last Updated

6
7
8
9
10
11
12
13
14
15
16
17
18
19
20
21
22
23
24
25
26
27
28
29
30
31
32
33
34
35
36

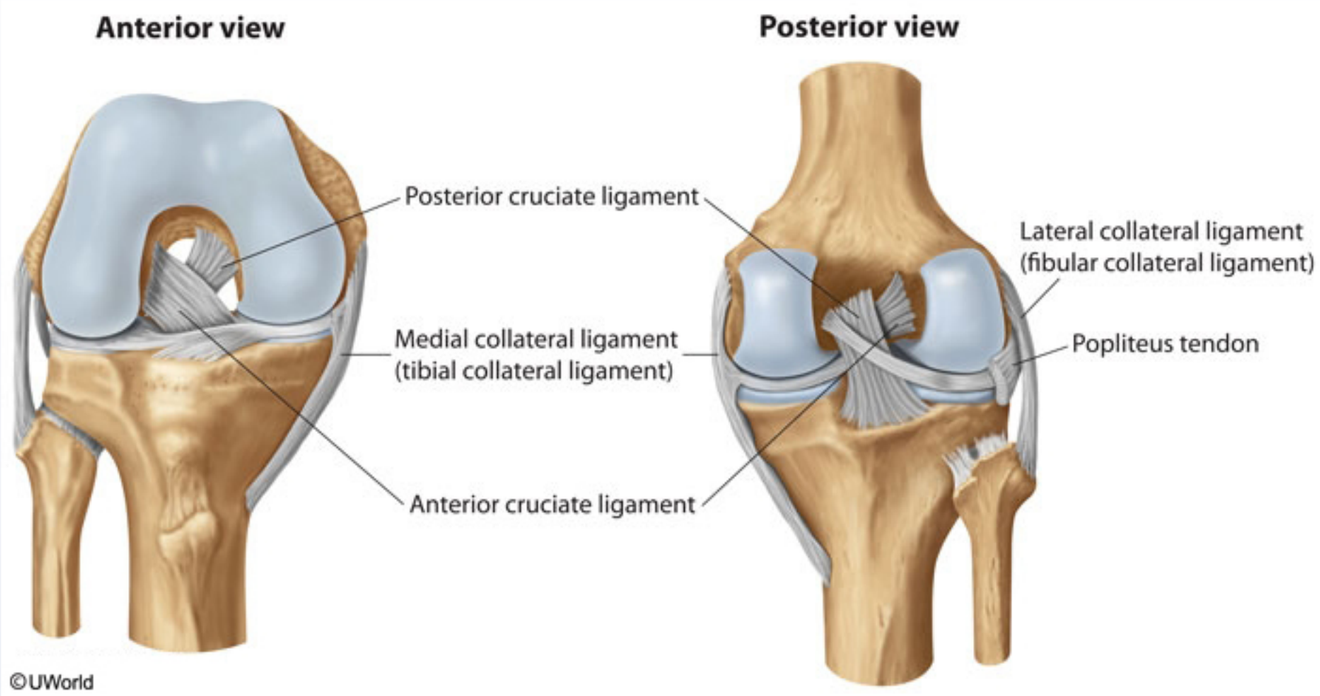

This patient has an injury to the **medial collateral ligament** (MCL). The MCL attaches proximally to the medial epicondyle of the femur and resists forces that push the knee medially. MCL injury typically occurs after a twisting injury or blow to the lateral knee while the foot is planted (**valgus stress injury**).

The valgus stress test is performed with the knee extended by placing one hand along the lateral thigh and pressing inward while the other hand is placed on the medial aspect of the ankle and pushed outward. Laxity of the knee and/or medial joint line widening indicates MCL injury.

(Choices A and E) The lateral (A) and medial (E) menisci reduce shock and help transfer force from the upper to the lower leg. Medial meniscal injury can occur with twisting movement of the knee and often accompanies MCL injury. Lateral meniscal injury is less common. Meniscal injury is diagnosed by joint line tenderness while the knee is flexed.

(Choice B) The lateral collateral ligament (LCL) resists excessive lateral movement of the knee. LCL injury is uncommon but would be

This patient has an injury to the **medial collateral ligament** (MCL). The MCL attaches proximally to the medial epicondyle of the femur and resists forces that push the knee medially. MCL injury typically occurs after a twisting injury or blow to the lateral knee while the foot is planted (**valgus stress injury**).

The valgus stress test is performed with the knee extended by placing one hand along the lateral thigh and pressing inward while the other hand is placed on the medial aspect of the ankle and pushed outward. Laxity of the knee and/or medial joint line widening indicates MCL injury.

(Choices A and E) The lateral (A) and medial (E) menisci reduce shock and help transfer force from the upper to the lower leg. Medial meniscal injury can occur with twisting movement of the knee and often accompanies MCL injury. Lateral meniscal injury is less common. Meniscal injury is diagnosed by joint line tenderness while the knee is flexed.

(Choice B) The lateral collateral ligament (LCL) resists excessive lateral movement of the knee. LCL injury is uncommon but would be characterized by laxity of the knee with varus stress.

(Choice C) The anterior cruciate ligament (ACL) resists anterior movement and medial rotation of the tibia. Injury is indicated by increased anterior movement of the tibia in relation to the femur (eg, anterior drawer test, Lachman test).

(Choice D) The posterior cruciate ligament (PCL) stabilizes the tibia and femur during knee movement. Excessive backward movement of the tibia in relation to the femur (posterior drawer test) indicates PCL injury.

Educational objective:
The medial collateral ligament resists force that pushes the knee medially. Increased laxity of the knee with the valgus stress test indicates injury to the medial collateral ligament.

References

- MCL injuries of the knee: current concepts review.

Anatomy	Rheumatology/Orthopedics & Sports	Medial collateral ligament injury
Subject	System	Topic

Copyright © UWorld. All rights reserved.

6
7
8
9
10
11
12
13
14
15
16
17
18
19
20
21
22
23
24
25
26
27
28
29
30
31
32
33
34
35
36

A 23-year-old athlete comes to the office with right knee pain after playing basketball. A coronal MRI of his knee viewed from the posterior aspect is shown below.

The asterisk marks the attachment site of which of the following ligaments?

A. Anterior cruciate
B. Patellar
C. Posterior cruciate
D. Tibial collateral
E. Transverse genicular

6
7
8
9
10
11
12
13
14
15
16
17
18
19
20
21
22
23
24
25
26
27
28
29
30
31
32
33
34
35
36

The asterisk marks the attachment site of which of the following ligaments?

A. Anterior cruciate (36%)

B. Patellar (0%)

✓ C. Posterior cruciate (58%)

D. Tibial collateral (1%)

E. Transverse genicular (2%)

Omitted
Correct answer

58%
Answered correctly

05 secs
Time Spent

06/28/2020
Last Updated

6
7
8
9
10
11
12
13
14
15
16
17
18
19
20
21
22
23
24
25
26
27
28
29
30
31
32
33
34
35
36

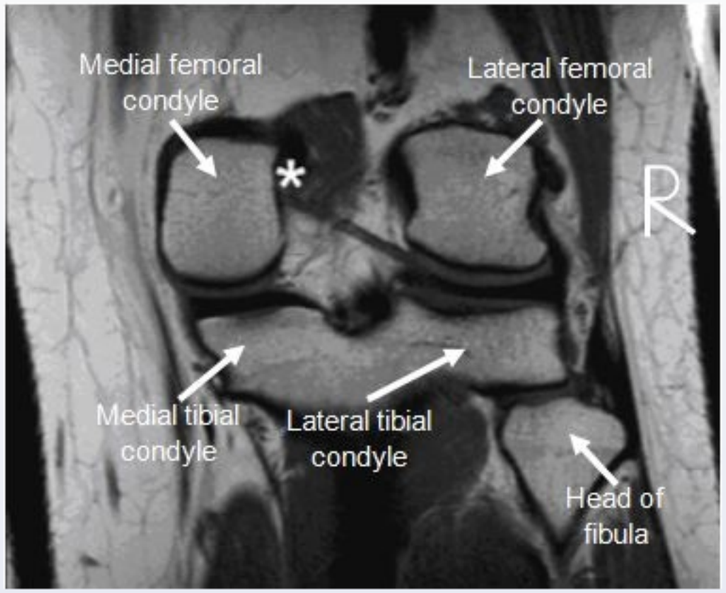

In this coronal MRI of the right knee viewed from the posterior aspect, the opaque (white) regions, from top to bottom, correspond to the medial and lateral condyles of the femur (the medial condyle is adjacent to the asterisk), the medial and lateral condyles of the tibia, and the head of the fibula. The **anterior cruciate ligament** (ACL) and the **posterior cruciate ligament** (PCL) are located within the articular capsule of the knee joint and cross one another as each spans from the femur to the tibia. The **PCL** attaches to the posterior part of the intercondylar area of the tibia and the anterolateral surface of the medial condyle of the femur (asterisk). It prevents posterior displacement of the tibia relative to the femur when the knee is flexed (posterior drawer test).

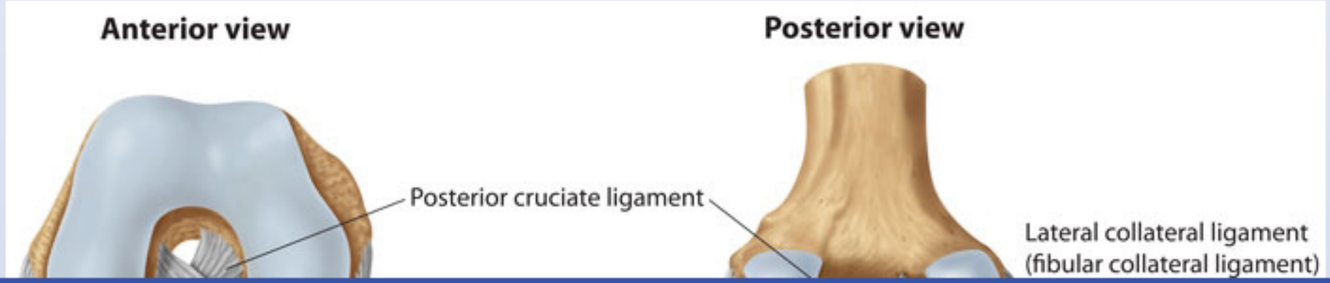

6
7
8
9
10
11
12
13
14
15
16
17
18
19
20
21
22
23
24
25
26
27
28
29
30
31
32
33
34
35
36

In this coronal MRI of the right knee viewed from the posterior aspect, the opaque (white) regions, from top to bottom, correspond to the medial and lateral condyles of the femur (the medial condyle is adjacent to the asterisk), the medial and lateral condyles of the tibia, and the head of the fibula. The **anterior cruciate ligament** (ACL) and the **posterior cruciate ligament** (PCL) are located within the articular capsule of the knee joint and cross one another as each spans from the femur to the tibia. The **PCL** attaches to the posterior part of the intercondylar area of the tibia and the anterolateral surface of the medial condyle of the femur (asterisk). It prevents posterior displacement of the tibia relative to the femur when the knee is flexed (posterior drawer test).

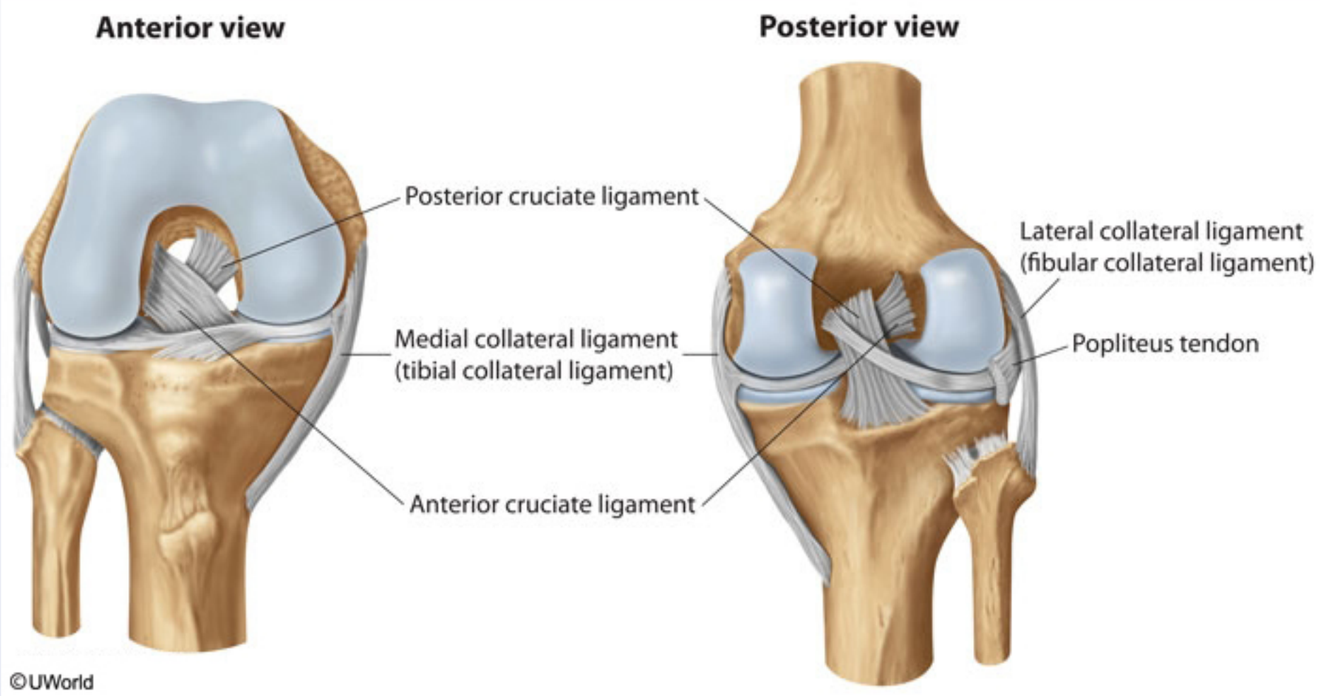

(Choice A) The ACL is injured more commonly than the PCL. It spans from the anterior portion of the intercondylar tibia to the posterior medial side of the lateral femoral condyle. It prevents anterior displacement of the tibia relative to the femur when the knee is flexed (anterior drawer test).

6
7
8
9
10
11
12
13
14
15
16
17
18
19
20
21
22
23
24
25
26
27
28
29
30
31
32
33
34
35
36

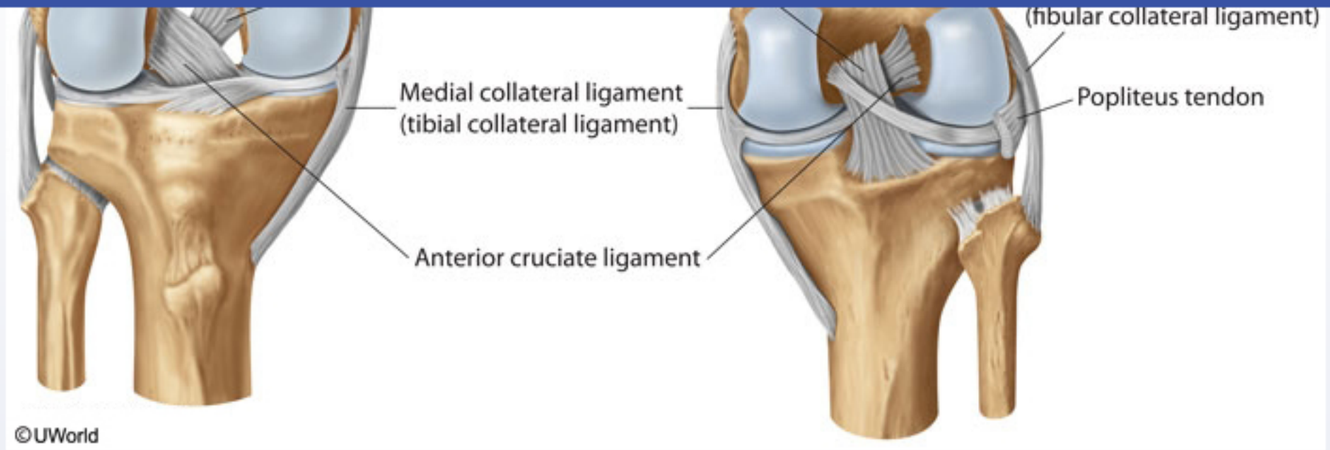

(Choice A) The ACL is injured more commonly than the PCL. It spans from the anterior portion of the intercondylar tibia to the posterior medial side of the lateral femoral condyle. It prevents anterior displacement of the tibia relative to the femur when the knee is flexed (anterior drawer test).

(Choice B) The patellar ligament spans from the patella to the tibial tuberosity and is the continuation of the quadriceps femoris tendon.

(Choice D) The tibial (medial) collateral ligament is a very strong band of tissue that spans from the medial femoral epicondyle to the medial condyle of the tibia. It also attaches to the medial meniscus.

(Choice E) The transverse genicular ligament attaches the medial and lateral menisci anteriorly on the proximal articular surface of the tibia.

Educational objective:
The posterior cruciate ligament prevents posterior displacement of the tibia relative to the femur when the knee is flexed. It attaches to the posterior part of the intercondylar area of the tibia and the anterior part of the lateral surface of the medial epicondyle of the femur.

Anatomy	Rheumatology/Orthopedics & Sports	Knee trauma
Subject	System	Topic

Copyright © UWorld. All rights reserved.

6
7
8
9
10
11
12
13
14
15
16
17
18
19
20
21
22
23
24
25
26
27
28
29
30
31
32
33
34
35
36

A 54-year-old woman comes to the emergency department due to a hand injury after a fall. The patient slipped in the bathroom and fell backwards onto her extended right hand. She was able to get up but has had right wrist pain and finger numbness since the fall. Medical history is notable for obesity, hypertension, and type 2 diabetes mellitus. On examination of her right hand, there is decreased sensation in the palmar aspect of her first three digits and a small bump is noted just below the palm. Lunate dislocation causing median nerve compression is suspected. Which of the following marked bones on a normal x-ray is most likely dislocated in this patient?

6
7
8
9
10
11
12
13
14
15
16
17
18
19
20
21
22
23
24
25
26
27
28
29
30
31
32
33
34
35
36

A. A

B. B

6
7
8
9
10
11
12
13
14
15
16
17
18
19
20
21
22
23
24
25
26
27
28
29
30
31
32
33
34
35
36

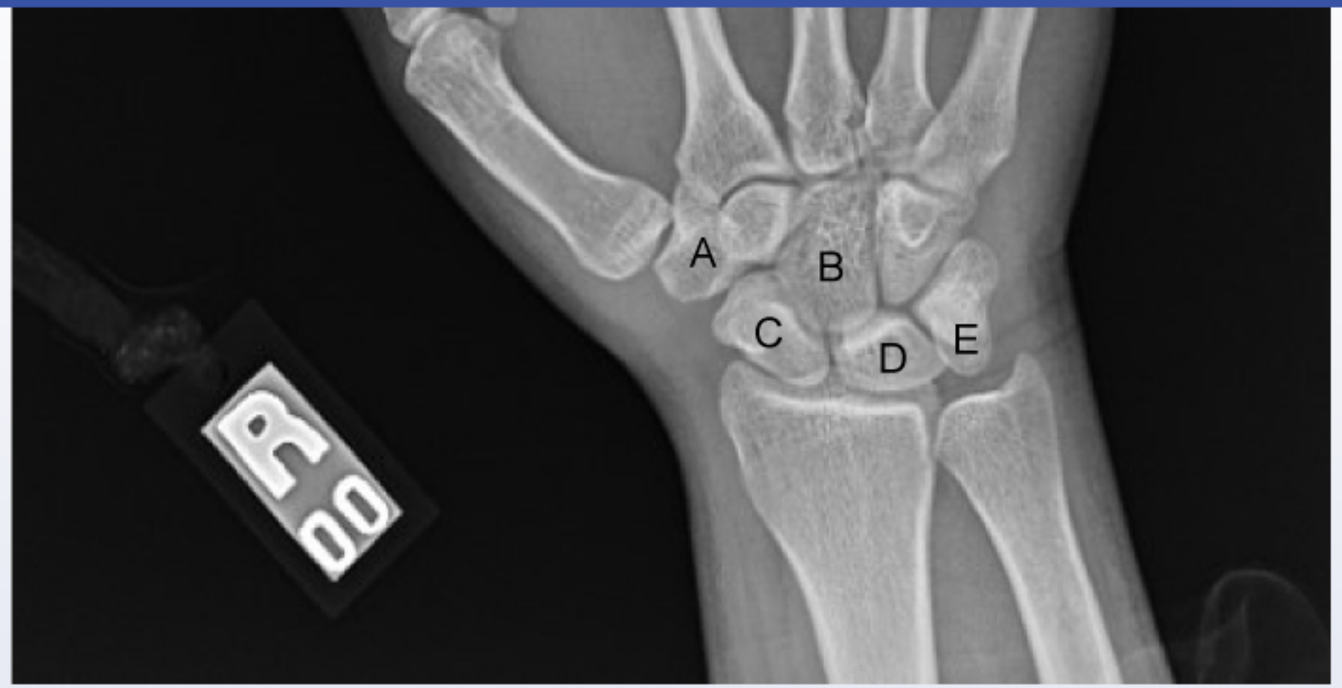

A. A

B. B

C. C

D. D

E. E

Submit

6
7
8
9
10
11
12
13
14
15
16
17
18
19
20
21
22
23
24
25
26
27
28
29
30
31
32
33
34
35
36

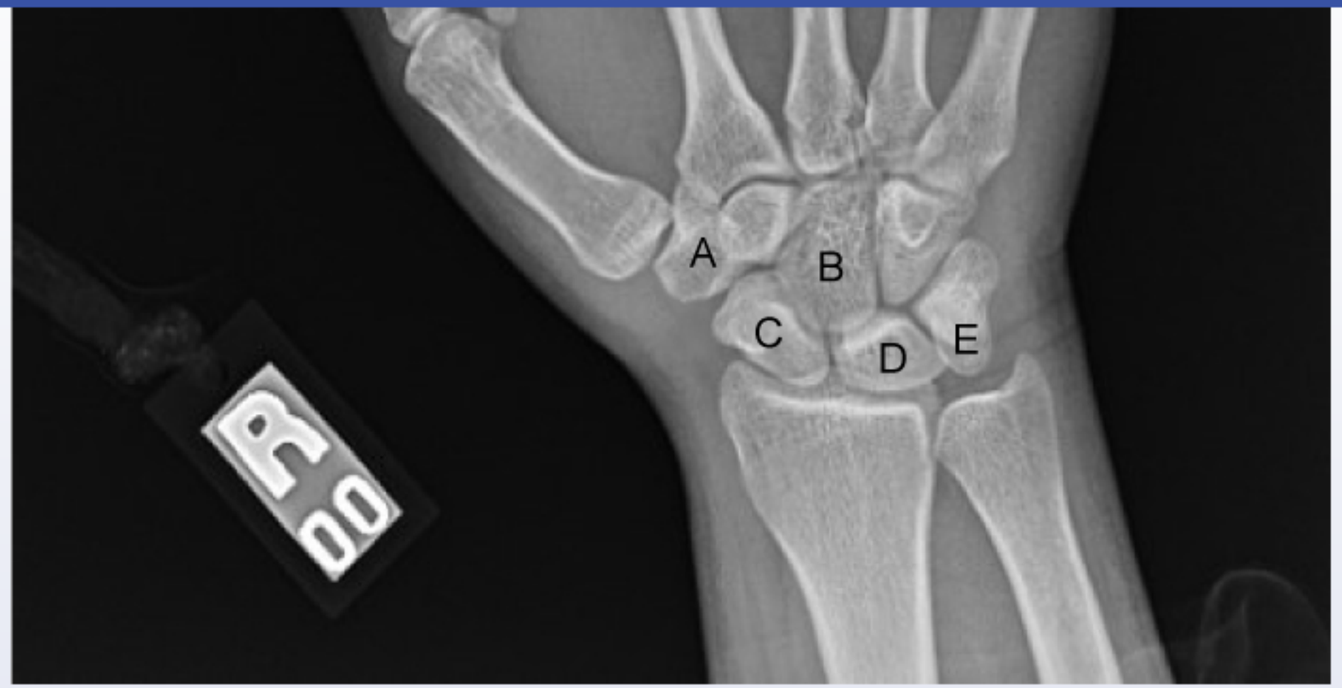

A. A (5%)

B. B (6%)

C. C (20%)

✓ D. D (64%)

E. E (3%)

Omitted
Correct answer

64%
Answered correctly

08 secs
Time Spent

02/10/2020
Last Updated

6
7
8
9
10
11
12
13
14
15
16
17
18
19
20
21
22
23
24
25
26
27
28
29
30
31
32
33
34
35
36

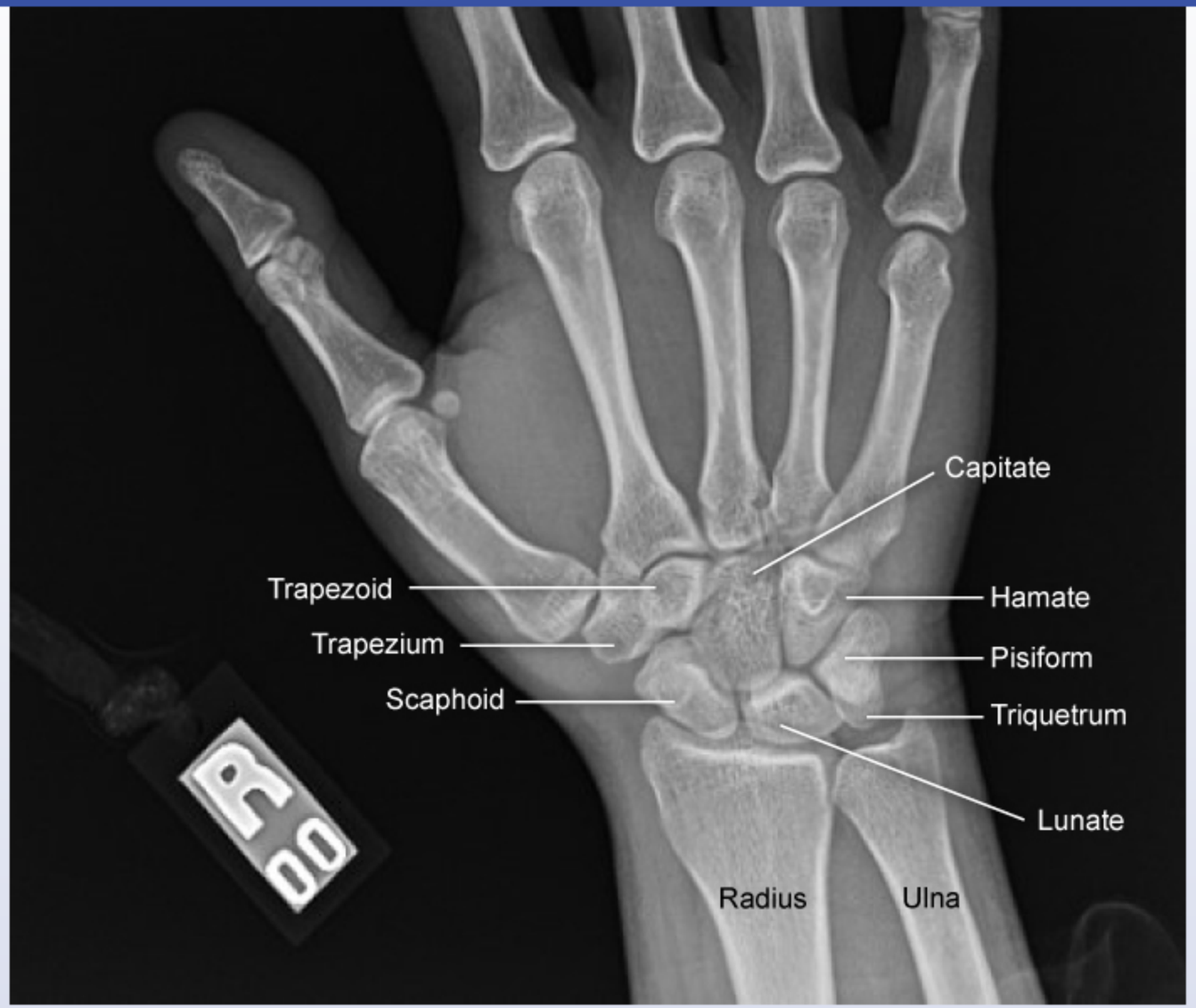

This patient has **lunate dislocation** after a fall onto an outstretched hand (FOOSH). Although the force transmitted up the arm by a FOOSH can injure many different structures in the arm (eg, elbow, humerus, shoulder), wrist complications are the most common (eg, lunate or scaphoid

6
7
8
9
10
11
12
13
14
15
16
17
18
19
20
21
22
23
24
25
26
27
28
29
30
31
32
33
34
35
36



This patient has **lunate dislocation** after a fall onto an outstretched hand (FOOSH). Although the force transmitted up the arm by a FOOSH can injure many different structures in the arm (eg, elbow, humerus, shoulder), wrist complications are the most common (eg, lunate or scaphoid dislocation/fracture, distal radius fracture).

The **lunate** is in the proximal row of carpal bones and can be identified on x-ray as the **more medial** (ulnar) of the 2 bones that **articulate with the radius**. Volar dislocation of the lunate can compress the median nerve within the carpal tunnel, resulting in wrist pain and numbness in the first (radial) 3½ digits.

(Choice A) The trapezium is the most lateral (radial) of the distal carpal bones and articulates with the first metacarpal.

(Choice B) The capitate is the largest carpal bone; it lies in the distal row at the center of the wrist and articulates with the third metacarpal.

(Choice C) The scaphoid is the most lateral (radial) of the proximal carpal bones and articulates with the radius. It is the carpal bone most frequently affected by a FOOSH; dislocation or fracture of the scaphoid can present with wrist pain and tenderness in the anatomic snuffbox. Scaphoid fractures have a high risk of avascular necrosis.

(Choice E) The triquetrum is located in the proximal row on the medial (ulnar) side and is partially obscured on x-ray by the pisiform, which lies directly anterior to it.

Educational objective:
The lunate bone is the more medial (ulnar) of the 2 proximal carpal bones that articulate with the radius. A fall onto an outstretched hand can cause dislocation of the lunate bone with resulting compression of the median nerve (eg, wrist pain, numbness in the first 3½ digits).

Anatomy	Rheumatology/Orthopedics & Sports	Hand injury
Subject	System	Topic

Copyright © UWorld. All rights reserved.

6
7
8
9
10
11
12
13
14
15
16
17
18
19
20
21
22
23
24
25
26
27
28
29
30
31
32
33
34
35
36

Radius Ulna

Exhibit Display

Anatomic snuffbox

Zoom In Zoom Out Reset Add To New Card | Existing Card

6
7
8
9
10
11
12
13
14
15
16
17
18
19
20
21
22
23
24
25
26
27
28
29
30
31
32
33
34
35
36

A 46-year-old gardener comes to the office due to knee pain. It began abruptly 3 days earlier and improved only minimally with acetaminophen. The patient spends hours on his knees several times a week while working. Past medical history is notable for hypertension and seasonal allergies. His current medications include lisinopril, loratadine, and fluticasone nasal spray. Examination of the lower extremity shows no visible erythema or abrasions, but there is sharp, localized pain on palpation. Passive range of motion is normal in all joints, but the patient has severe pain when walking around the room or climbing onto the examination table. Which of the following bursae is most likely affected in this patient?

A. Anserine
B. Gastrocnemius
C. Prepatellar
D. Semimembranosus (popliteal)
E. Suprapatellar

Submit

6
7
8
9
10
11
12
13
14
15
16
17
18
19
20
21
22
23
24
25
26
27
28
29
30
31
32
33
34
35
36

A 46-year-old gardener comes to the office due to knee pain. It began abruptly 3 days earlier and improved only minimally with acetaminophen. The patient spends hours on his knees several times a week while working. Past medical history is notable for hypertension and seasonal allergies. His current medications include lisinopril, loratadine, and fluticasone nasal spray. Examination of the lower extremity shows no visible erythema or abrasions, but there is sharp, localized pain on palpation. Passive range of motion is normal in all joints, but the patient has severe pain when walking around the room or climbing onto the examination table. Which of the following bursae is most likely affected in this patient?

A. Anserine (3%)
B. Gastrocnemius (2%)
✓ C. Prepatellar (65%)
D. Semimembranosus (popliteal) (10%)
E. Suprapatellar (17%)

Omitted
Correct answer
C

65%
Answered correctly

02 secs
Time Spent

05/30/2020
Last Updated

Explanation

6
7
8
9
10
11
12
13
14
15
16
17
18
19
20
21
22
23
24
25
26
27
28
29
30
31
32
33
34
35
36

Lateral knee

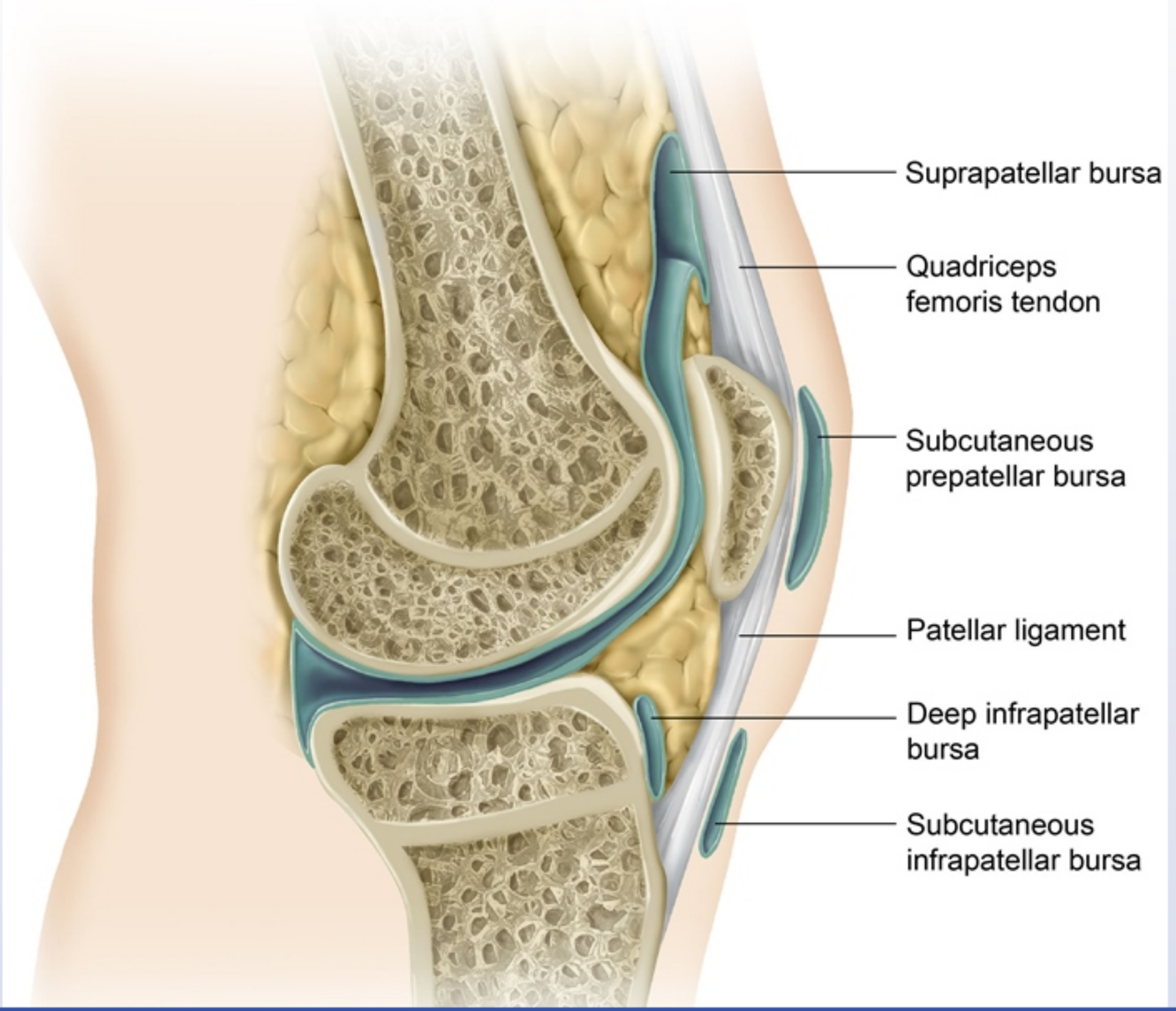

©UWorld

A **bursa** is a fluid-filled synovial sac that serves to alleviate pressure and friction at bony prominences and ligamentous attachments throughout the body. Bursae are vulnerable to injury from acute trauma or chronic repetitive pressure and may also become inflamed due to infection (septic bursitis), crystalline arthropathy (eg, gout), or autoimmune conditions (eg, rheumatoid arthritis). Because bursae are located in prominent and exposed positions, the pain of bursitis may be exquisite, and point tenderness is typical. Other features of bursitis may include swelling and erythema, particularly with more superficial bursae. Active range of motion is often decreased or painful, but passive motion is usually normal as it results in less pressure on the inflamed bursa.

This patient with acute pain and localized tenderness associated with repetitive **anterior** knee trauma from kneeling has typical features of **prepatellar bursitis**, sometimes called "housemaid's knee." The prepatellar bursa is located between the patella and the overlying skin. Other occupations associated with prepatellar and infrapatellar bursitis include carpet layers, mechanics, and plumbers.

(Choice A) Anserine bursitis presents with pain along the medial knee and well-defined tenderness approximately 4 cm distal to the anteromedial joint margin of the knee. It frequently results from obesity or overuse in athletes.

(Choices B and D) Popliteal (Baker) cysts are caused by swelling of the gastrocnemius or semimembranosus bursa. They often form due to extrusion of synovial fluid from the knee joint into the bursa in patients with osteoarthritis or inflammatory joint disease.

(Choice E) The suprapatellar bursa is located anteriorly between the distal femur and quadriceps. Bursitis here is most often caused by a direct blow to the distal thigh or prolonged/repetitive quadriceps activity (eg, running).

Educational objective:
A bursa is a fluid-filled synovial sac that serves to alleviate pressure from bony prominences and reduce friction between muscles and tendons. Acute trauma or chronic repetitive pressure can cause injury, leading to localized pain and tenderness. Prepatellar bursitis causes anterior knee pain and is usually due to repetitive or prolonged kneeling.

Anatomy	Rheumatology/Orthopedics & Sports	Bursitis
Subject	System	Topic

Copyright © UWorld. All rights reserved.

©UWorld

Exhibit Display

Medial knee & pes anserinus

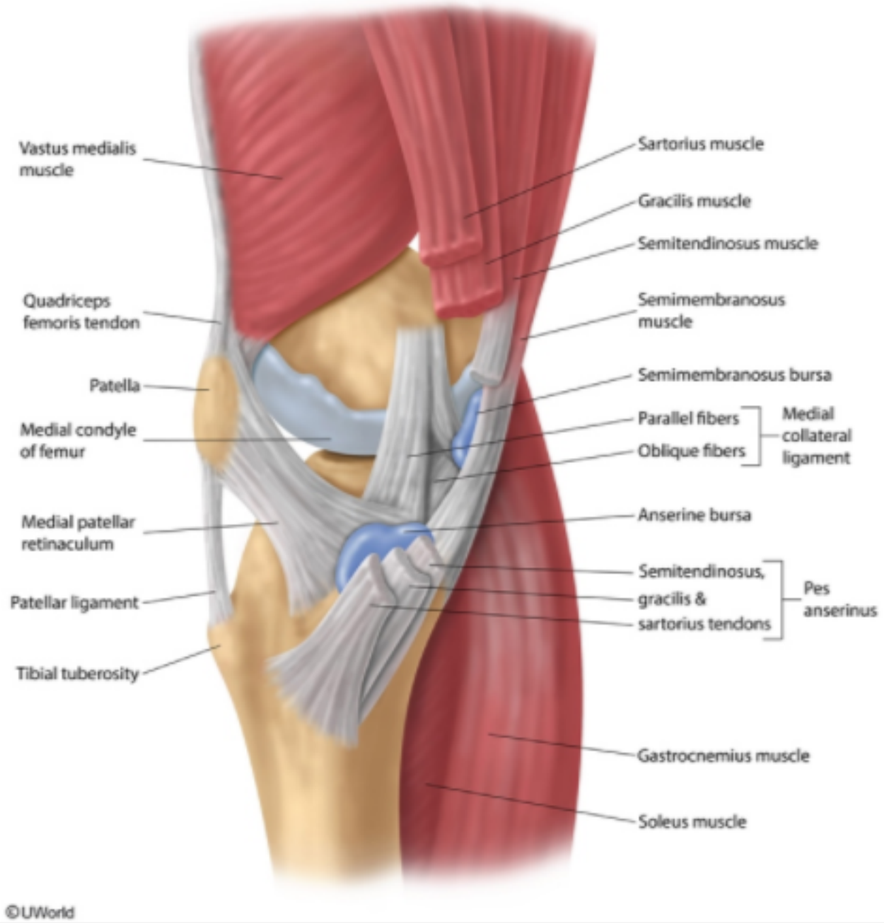

Zoom In | Zoom Out | Reset | Add To New Card | Existing Card

6
7
8
9
10
11
12
13
14
15
16
17
18
19
20
21
22
23
24
25
26
27
28
29
30
31
32
33
34
35
36

A 24-year-old man is brought to the emergency department due to right arm pain after a fall. While rock climbing at a nearby national park, the patient lost his grip and fell approximately 3 m (10 ft) onto the boulders below. He says, "I landed on my right arm and heard something snap." The patient did not strike his head or lose consciousness. He has no chronic medical conditions and takes no daily medications. Vital signs are within normal limits. Physical examination shows extensive bruising over the lateral right arm and a total inability to extend the right wrist. X-ray reveals a midshaft fracture of the right humerus. Which of the following arteries is most likely to be injured in this patient?

A. Brachial artery

B. Common interosseous artery

C. Deep brachial artery

D. Posterior circumflex humeral artery

E. Radial collateral artery

Submit

6
7
8
9
10
11
12
13
14
15
16
17
18
19
20
21
22
23
24
25
26
27
28
29
30
31
32
33
34
35
36

A 24-year-old man is brought to the emergency department due to right arm pain after a fall. While rock climbing at a nearby national park, the patient lost his grip and fell approximately 3 m (10 ft) onto the boulders below. He says, "I landed on my right arm and heard something snap." The patient did not strike his head or lose consciousness. He has no chronic medical conditions and takes no daily medications. Vital signs are within normal limits. Physical examination shows extensive bruising over the lateral right arm and a total inability to extend the right wrist. X-ray reveals a midshaft fracture of the right humerus. Which of the following arteries is most likely to be injured in this patient?

- A. Brachial artery (26%)
- B. Common interosseous artery (1%)
- ✓ C. Deep brachial artery (47%)
- D. Posterior circumflex humeral artery (10%)
- E. Radial collateral artery (13%)

Omitted
Correct answer
C

47%
Answered correctly

02 secs
Time Spent

05/10/2020
Last Updated

Explanation

Deep brachial artery & radial nerve

6
7
8
9
10
11
12
13
14
15
16
17
18
19
20
21
22
23
24
25
26
27
28
29
30
31
32
33
34
35
36

Deep brachial artery & radial nerve

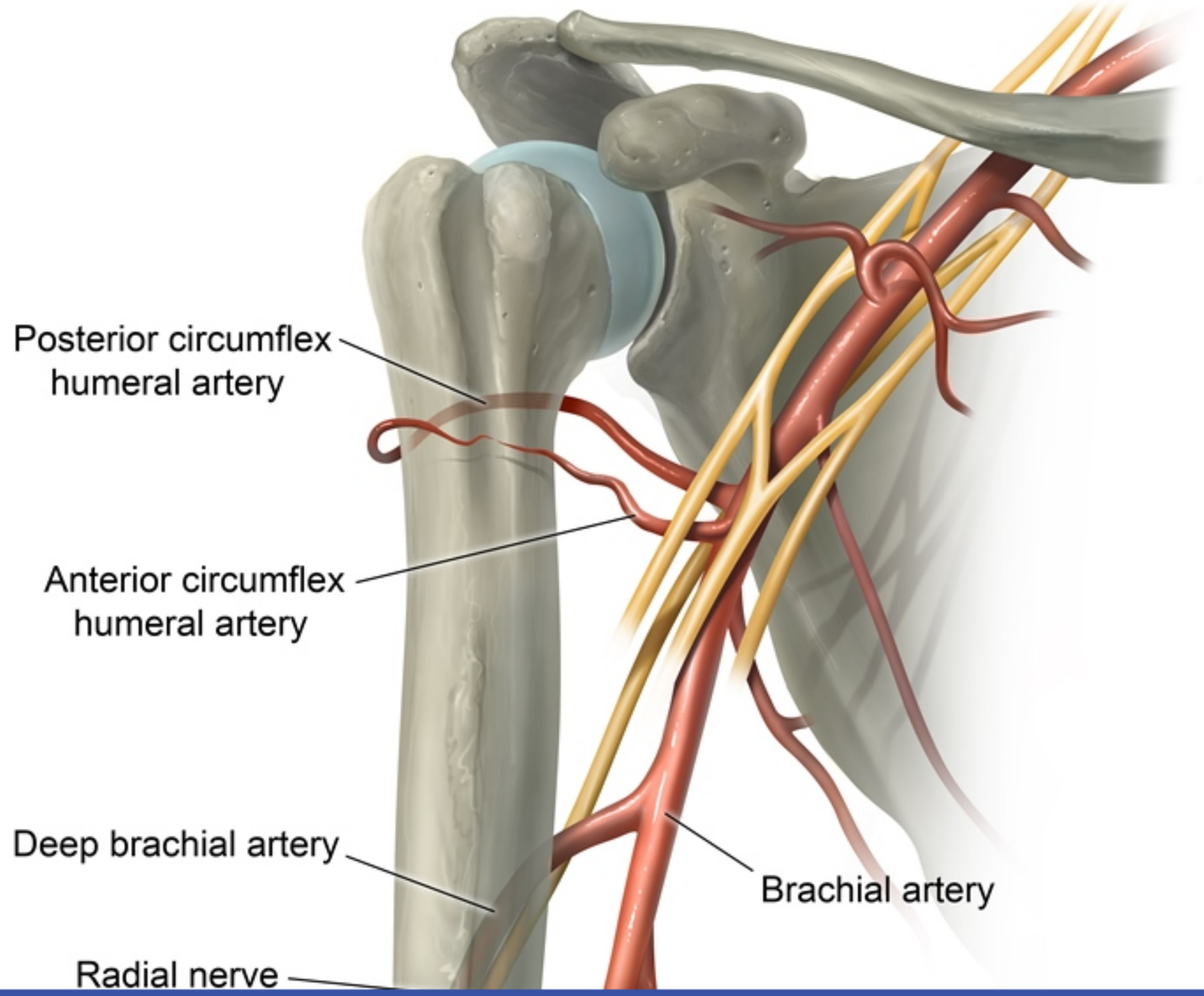

6
7
8
9
10
11
12
13
14
15
16
17
18
19
20
21
22
23
24
25
26
27
28
29
30
31
32
33
34
35
36

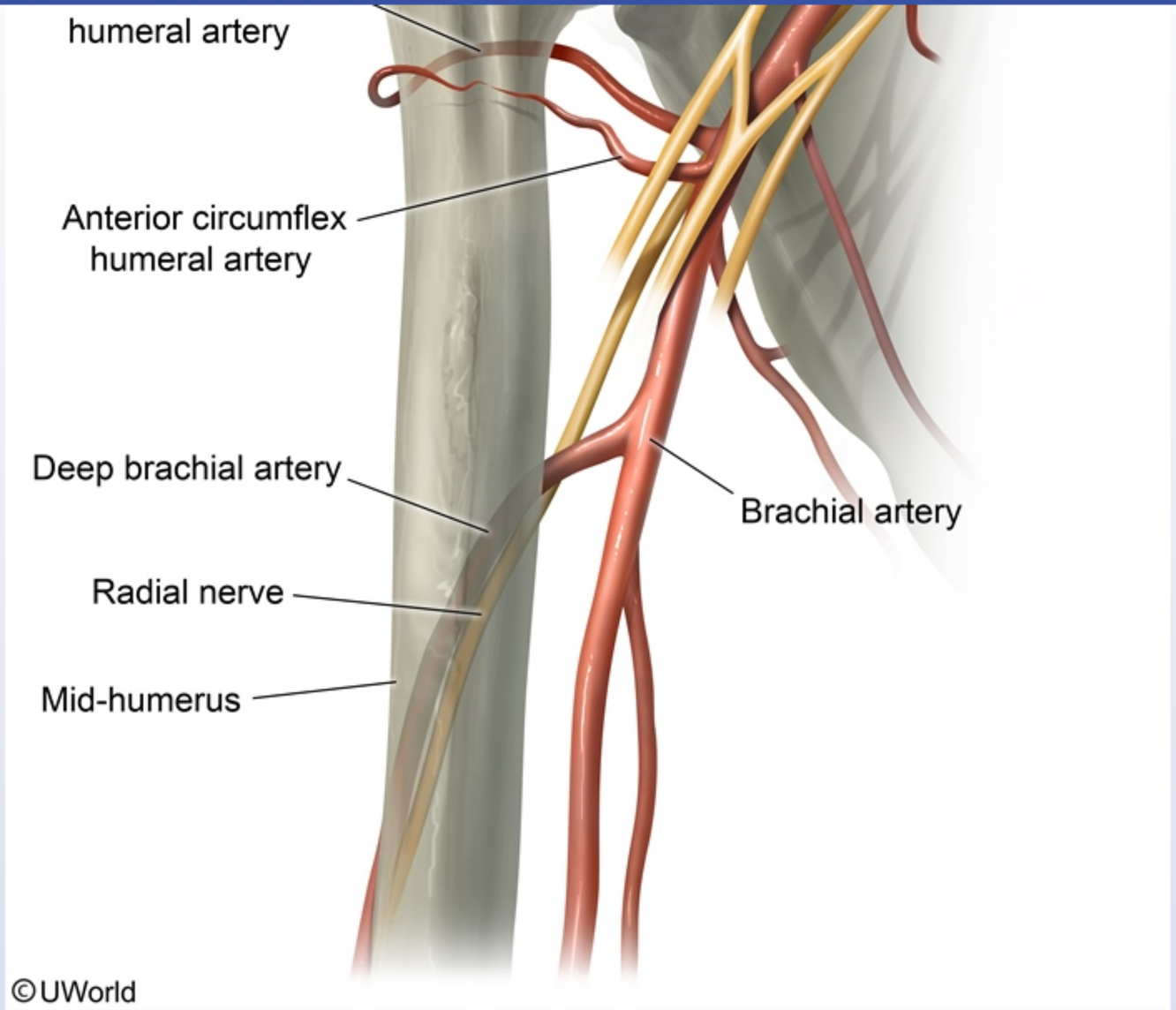

This patient has a humerus fracture associated with wrist drop, suggesting a **radial nerve injury**. The radial nerve is a terminal branch of the

This patient has a humerus fracture associated with wrist drop, suggesting a **radial nerve injury**. The radial nerve is a terminal branch of the brachial plexus that carries fibers originating in the C5-T1 nerve roots. It innervates most of the **forearm extensors** at the elbow (eg, triceps) and most of the **hand extensors** at the wrist. It also innervates the extrinsic extensors of the digits and the brachioradialis and supinator muscles. In addition, the radial nerve provides cutaneous sensory innervation to the dorsal hand, forearm, and upper arm.

Radial nerve deficits due to a **midshaft humeral fracture** raise concern for an associated injury to the deep brachial artery. The **deep brachial** (profunda brachii) artery branches off the brachial artery high in the arm, passes inferior to the teres major muscle, and courses posteriorly along the humerus in close association with the radial nerve.

(Choice A) After giving off the deep brachial artery, the brachial artery continues anteromedially until it branches to form the radial and ulnar arteries in the forearm. Supracondylar fractures of the humerus may injure the distal portion of the brachial artery but are unlikely to injure the radial nerve or cause wrist drop.

(Choice B) The common interosseous artery is a short branch of the ulnar artery that gives rise to anterior, posterior, and recurrent branches within the proximal forearm.

(Choice D) The anterior and posterior circumflex humeral arteries are branches of the axillary artery that form an anastomosis encircling the surgical neck of the humerus in the quadrangular space. The axillary nerve travels in close association with the posterior circumflex artery, and a fracture to the surgical neck of the humerus may damage them.

(Choice E) The deep brachial artery divides into the radial and middle collateral arteries. The radial collateral artery also courses with the radial nerve, but injury to this artery from a midshaft fracture is less likely because it originates at the lower end of the spiral groove.

Educational objective:
The deep brachial (profunda brachii) artery and radial nerve run together along the posterior aspect of the humerus. Midshaft fractures of the humerus risk injury to these structures.

Anatomy	Rheumatology/Orthopedics & Sports	Upper extremity long bone fracture
Subject	System	Topic

Copyright © UWorld. All rights reserved.

6
7
8
9
10
11
12
13
14
15
16
17
18
19
20
21
22
23
24
25
26
27
28
29
30
31
32
33
34
35
36

Exhibit Display

Complications of supracondylar fracture

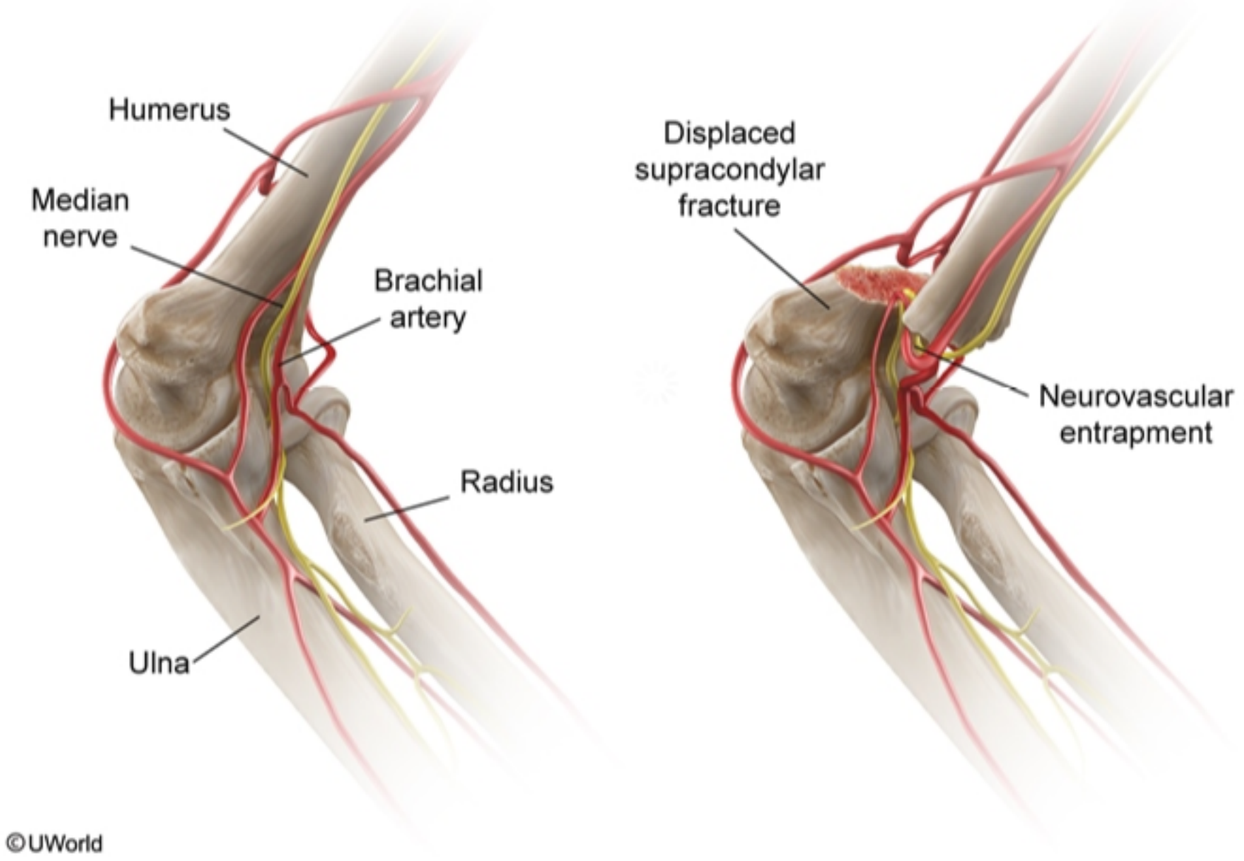

Zoom In | Zoom Out | Reset | Add To New Card | Existing Card

Copyright © UWorld. All rights reserved.

6
7
8
9
10
11
12
13
14
15
16
17
18
19
20
21
22
23
24
25
26
27
28
29
30
31
32
33
34
35
36

Exhibit Display

Arteries of forearm

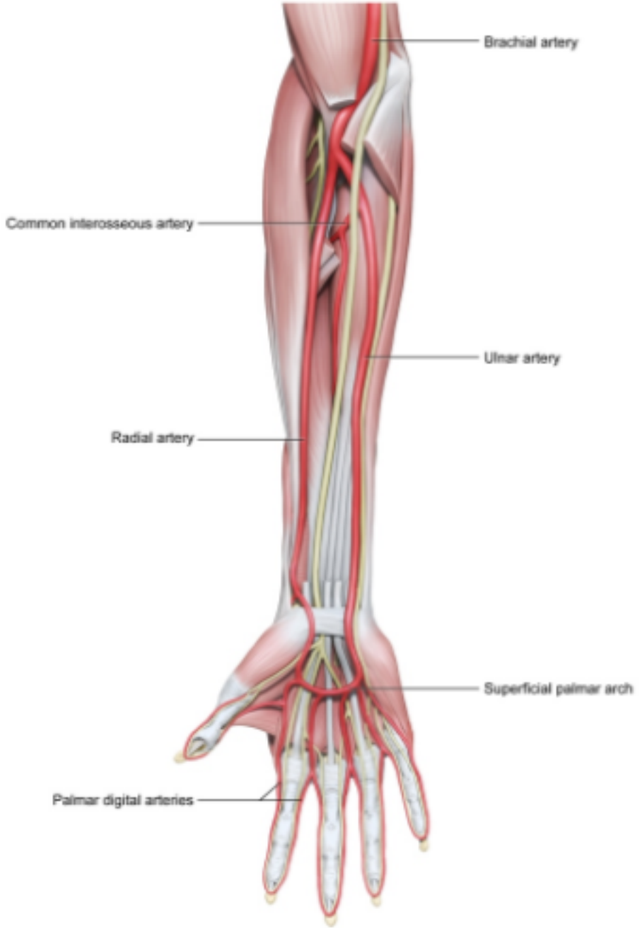

Zoom In | Zoom Out | Reset | Add To New Card | Existing Card

Copyright © UWorld. All rights reserved.

6
7
8
9
10
11
12
13
14
15
16
17
18
19
20
21
22
23
24
25
26
27
28
29
30
31
32
33
34
35
36

Exhibit Display

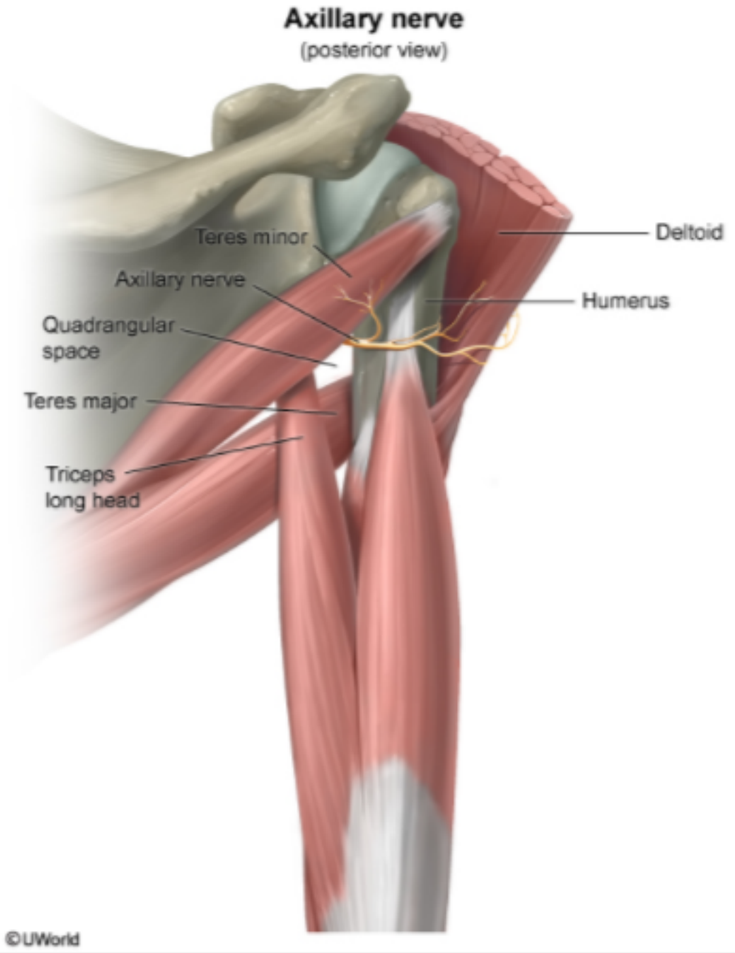

Zoom In | Zoom Out | Reset | Add To New Card | Existing Card

Copyright © UWorld. All rights reserved.

6
7
8
9
10
11
12
13
14
15
16
17
18
19
20
21
22
23
24
25
26
27
28
29
30
31
32
33
34
35
36

Exhibit Display

Arteries of the upper limb

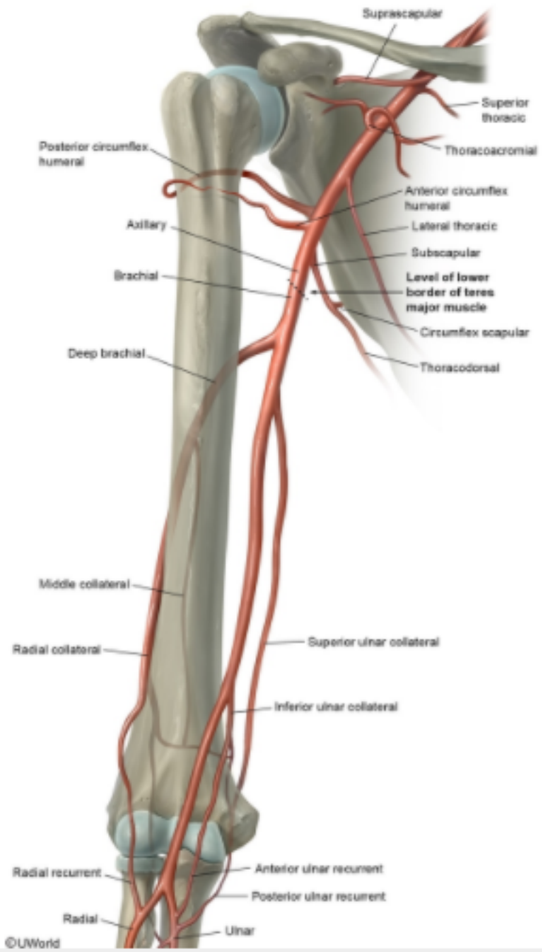

Zoom In | Zoom Out | Reset | Add To New Card | Existing Card

Copyright © UWorld. All rights reserved.

6
7
8
9
10
11
12
13
14
15
16
17
18
19
20
21
22
23
24
25
26
27
28
29
30
31
32
33
34
35
36

A 52-year-old man comes to the hospital following 4 weeks of vague back and abdominal pain. He also has experienced episodic fever, anorexia, and a 2-kg (4.4-lb) weight loss. The patient was recently diagnosed with HIV and has not yet begun taking antiretroviral therapy. He has a history of intravenous drug use. A CT scan of the abdomen reveals an infection involving the structure indicated by the arrow in the image below.

Which of the following structures is involved by this patient's infectious process?

A. Erector spinae muscle

B. Iliacus muscle

C. Ligamentum flavum

D. Psoas muscle

10
11
12
13
14
15
16
17
18
19
20
21
22
23
24
25
26
27
28
29
30
31
32
33
34
35
36
37
38
39
40

Which of the following structures is involved by this patient's infectious process?

A. Erector spinae muscle

B. Iliacus muscle

C. Ligamentum flavum

D. Psoas muscle

E. Transversus abdominis muscle

Submit

10
11
12
13
14
15
16
17
18
19
20
21
22
23
24
25
26
27
28
29
30
31
32
33
34
35
36
37
38
39
40

Which of the following structures is involved by this patient's infectious process?

A. Erector spinae muscle (13%)

B. Iliacus muscle (7%)

C. Ligamentum flavum (3%)

✓ D. Psoas muscle (75%)

E. Transversus abdominis muscle (0%)

Omitted
Correct answer

75%
Answered correctly

05 secs
Time Spent

05/12/2020
Last Updated

10
11
12
13
14
15
16
17
18
19
20
21
22
23
24
25
26
27
28
29
30
31
32
33
34
35
36
37
38
39
40

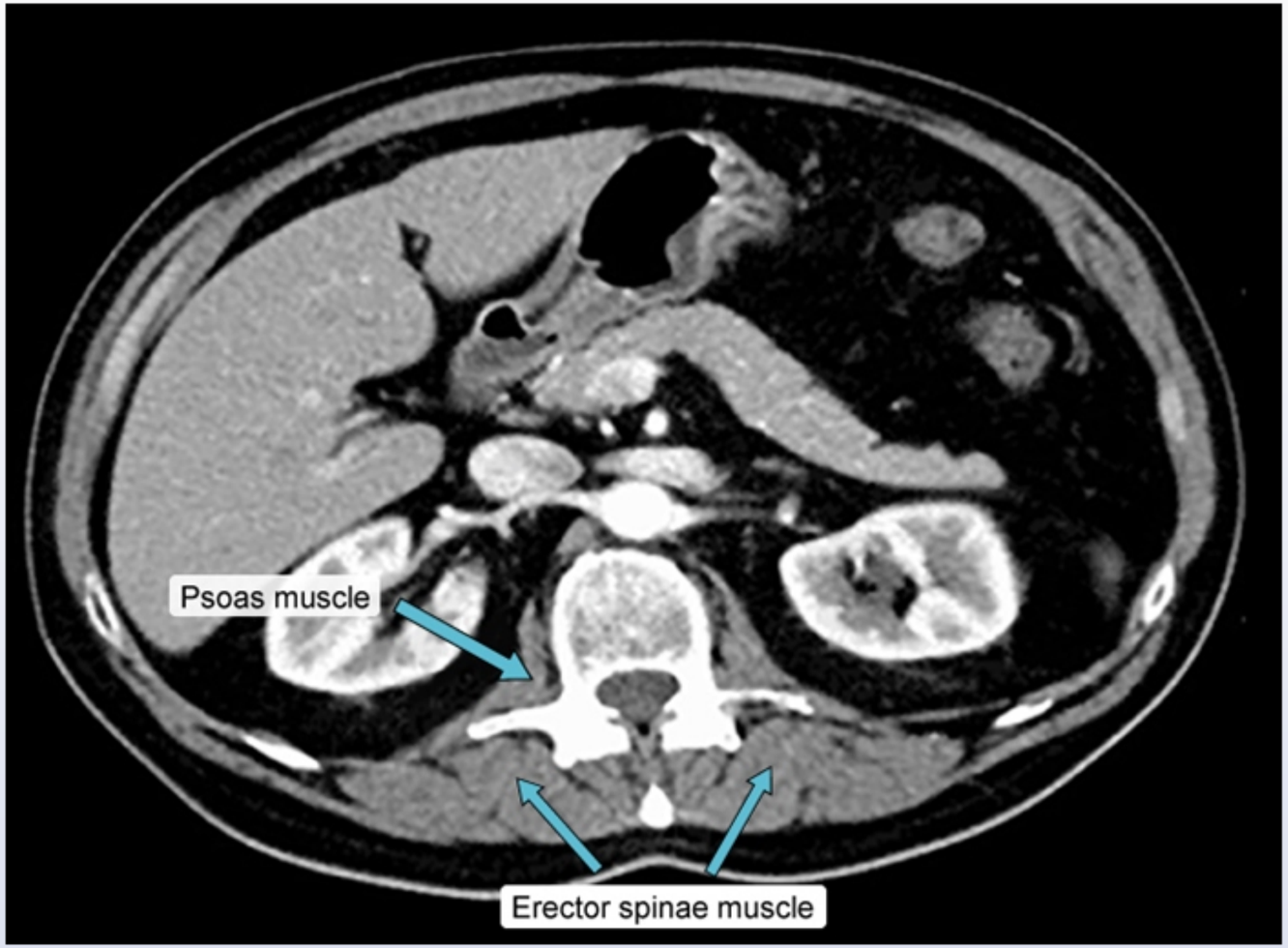

The arrow points to a bilaterally symmetric structure that lies in close association to the vertebral body and vertebral transverse process. This is the **psoas muscle**, which originates from the anterior surface of the transverse processes and lateral surface of the vertebral bodies at T12-L5. Inferiorly (at around the level of the inguinal ligament), the psoas muscle combines with the iliacus muscle **(Choice B)** to form the iliopsoas muscle, which functions in hip flexion and contributes to external rotation of the thigh.

10
11
12
13
14
15
16
17
18
19
20
21
22
23
24
25
26
27
28
29
30
31
32
33
34
35
36
37
38
39
40

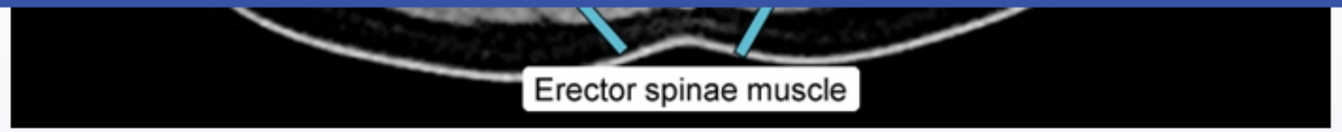

The arrow points to a bilaterally symmetric structure that lies in close association to the vertebral body and vertebral transverse process. This is the **psoas muscle**, which originates from the anterior surface of the transverse processes and lateral surface of the vertebral bodies at T12-L5. Inferiorly (at around the level of the inguinal ligament), the psoas muscle combines with the iliacus muscle **(Choice B)** to form the iliopsoas muscle, which functions in hip flexion and contributes to external rotation of the thigh.

Psoas abscess can develop due to hematogenous seeding from a distal site (primary abscess) or contiguous spread of infection from adjacent structures such as the vertebra (secondary abscess). Patients often present subacutely with abdominal/flank pain, fever, and inguinal mass. **HIV infection**, intravenous drug use, and diabetes mellitus are risk factors for primary psoas abscess development.

(Choice A) The erector spinae is a large muscle group of the back that courses longitudinally along the spinous processes. Bilateral contraction causes spine extension.

(Choice C) The ligamenta flava are paired elastic ligaments that connect the vertebral laminae. The ligamenta flava form the posterior wall of the spinal canal and help stabilize the spine.

(Choice E) The transversus abdominis (transversalis) muscle is the most internal of the anterior abdominal wall muscles. It lies immediately deep to the internal oblique and helps to flex the trunk as well as increase intraabdominal pressure during forced expiration.

Educational objective:
The psoas muscle originates from the anterior surface of the transverse processes and lateral surface of the vertebral bodies and functions primarily as a hip flexor. Psoas abscess may form due to direct spread of infection from an adjacent structure (eg, vertebral bodies, appendix, hip joint) or from hematogenous seeding from a distant site.

Anatomy	Rheumatology/Orthopedics & Sports	Psoas abscess
Subject	System	Topic

Copyright © UWorld. All rights reserved.

10
11
12
13
14
15
16
17
18
19
20
21
22
23
24
25
26
27
28
29
30
31
32
33
34
35
36
37
38
39
40

Exhibit Display

The iliopsoas muscle

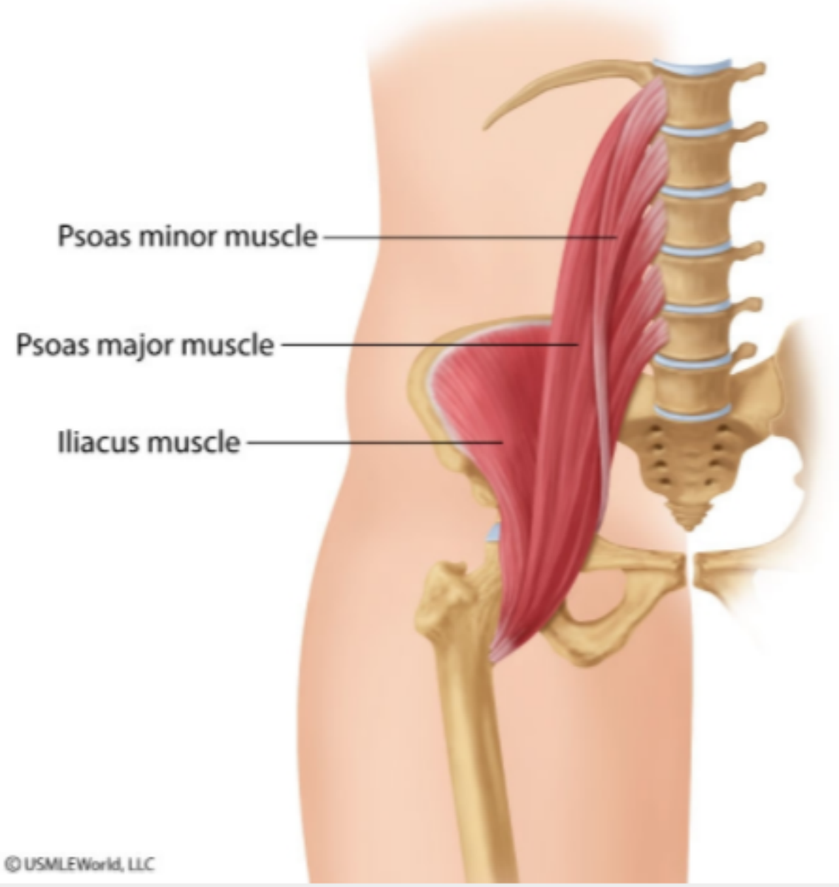

Zoom In | Zoom Out | Reset | Add To New Card | Existing Card

10
11
12
13
14
15
16
17
18
19
20
21
22
23
24
25
26
27
28
29
30
31
32
33
34
35
36
37
38
39
40

Exhibit Display

Vertebral ligaments

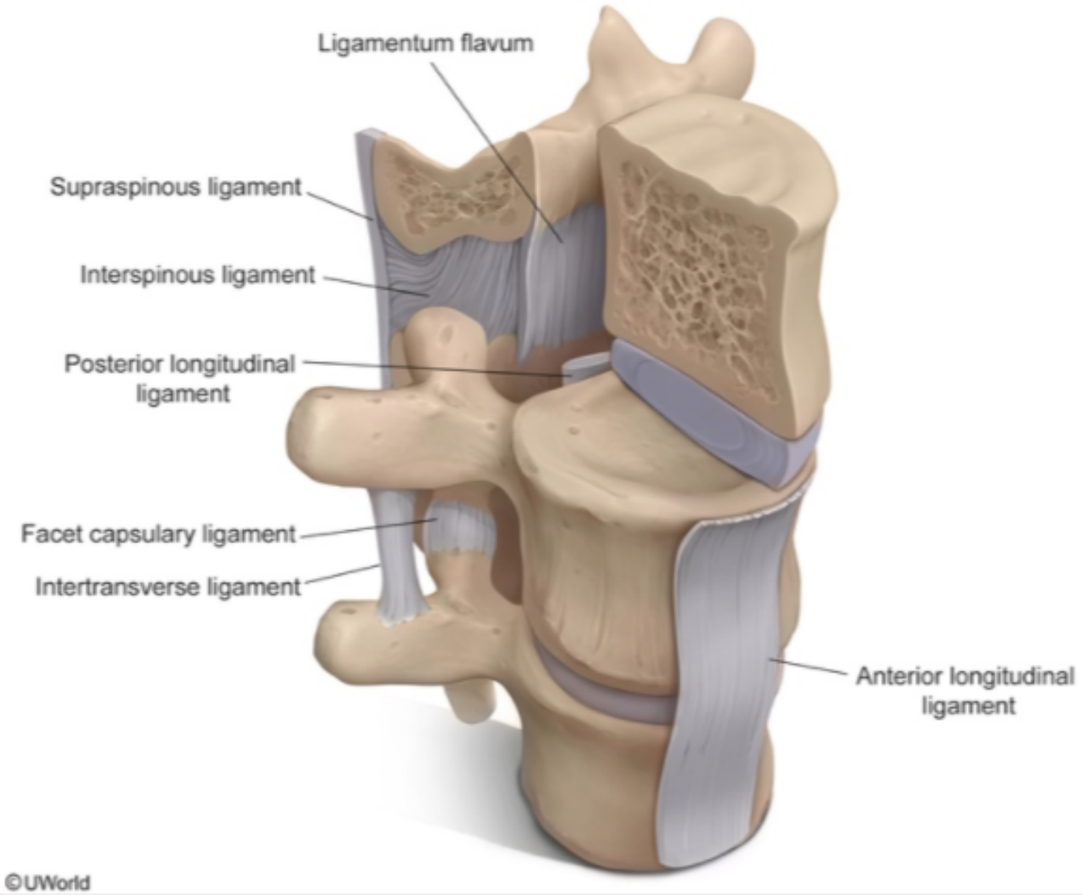

Zoom In | Zoom Out | Reset | Add To New Card | Existing Card

10
11
12
13
14
15
16
17
18
19
20
21
22
23
24
25
26
27
28
29
30
31
32
33
34
35
36
37
38
39
40

Exhibit Display

Abdominal wall musculature

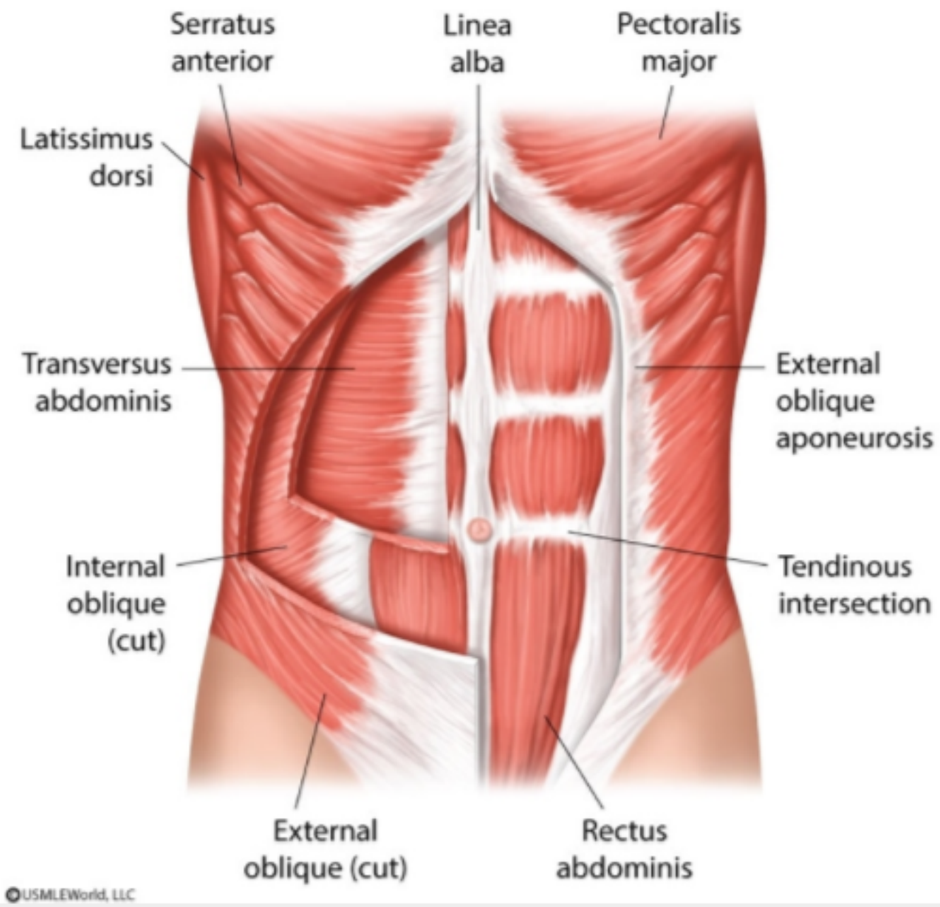

Zoom In | Zoom Out | Reset | Add To New Card | Existing Card

10
11
12
13
14
15
16
17
18
19
20
21
22
23
24
25
26
27
28
29
30
31
32
33
34
35
36
37
38
39
40

A 52-year-old man comes to the office due to right shoulder pain. He is an avid golfer but has been unable to play for the past 3 months due to the pain. Lately, it has started to interfere with his daily activities, such as getting dressed. An MRI shows thickening and calcification of the supraspinatus tendon. Which of the following shoulder actions is most likely to provoke pain in this patient?

A. Abduction
B. Adduction
C. Extension
D. Flexion
E. Internal rotation

Submit

A 52-year-old man comes to the office due to right shoulder pain. He is an avid golfer but has been unable to play for the past 3 months due to the pain. Lately, it has started to interfere with his daily activities, such as getting dressed. An MRI shows thickening and calcification of the supraspinatus tendon. Which of the following shoulder actions is most likely to provoke pain in this patient?

- ✓ A. Abduction (84%)
- B. Adduction (3%)
- C. Extension (2%)
- D. Flexion (2%)
- E. Internal rotation (7%)

Omitted
Correct answer
A

84%
Answered correctly

02 secs
Time Spent

01/11/2020
Last Updated

Explanation

Rotator cuff muscles				
Muscle	**Origin on scapula**	**Attachment on humerus**	**Function on arm**	**Innervation**
Supraspinatus	Supraspinous fossa	Superior aspect of greater tubercle	Abduction (primarily <15°)	Suprascapular nerve

Rotator cuff muscles				
Muscle	**Origin on scapula**	**Attachment on humerus**	**Function on arm**	**Innervation**
Supraspinatus	Supraspinous fossa	Superior aspect of greater tubercle	Abduction (primarily <15°)	Suprascapular nerve
Infraspinatus	Infraspinous fossa	Posterolateral aspect of greater tubercle	External rotation	Suprascapular nerve
Teres minor	Lateral border	Posterolateral aspect of greater tubercle	Adduction & external rotation	Axillary nerve
Subscapularis	Subscapular fossa	Lesser tubercle	Adduction & internal rotation	Upper & lower subscapular nerve

The rotator cuff is made up of the tendons of the supraspinatus, infraspinatus, subscapularis, and teres minor muscles. These tendons, along with the tendon of the long head of the biceps brachii muscle and the ligaments of the glenohumeral joint, contribute to shoulder stability.

In rotator cuff syndrome, the most commonly injured tendon is the supraspinatus as this tendon is prone to repeated impingement trauma between the humeral head and the acromion, especially in abduction. The supraspinatus is primarily an abductor of the arm; it originates in the supraspinous fossa of the scapula and inserts on the superior portion of the head of the humerus. Therefore, supraspinatus tendinopathy is associated with pain on abduction of the humerus, especially resisted active abduction.

(Choice B) Adduction of the humerus is accomplished by several muscles, including the latissimus dorsi, pectoralis major, coracobrachialis, subscapularis, and teres major and minor.

(Choice C) Extension of the humerus is accomplished primarily by the latissimus dorsi, posterior deltoid, and teres major.

(Choice D) Flexion of the humerus at the shoulder is accomplished primarily by the pectoralis major, coracobrachialis, biceps brachii, and anterior deltoid.

10
11
12
13
14
15
16
17
18
19
20
21
22
23
24
25
26
27
28
29
30
31
32
33
34
35
36
37
38
39
40

		tubercle	rotation	
Subscapularis	Subscapular fossa	Lesser tubercle	Adduction & internal rotation	Upper & lower subscapular nerve

The rotator cuff is made up of the tendons of the supraspinatus, infraspinatus, subscapularis, and teres minor muscles. These tendons, along with the tendon of the long head of the biceps brachii muscle and the ligaments of the glenohumeral joint, contribute to shoulder stability.

In rotator cuff syndrome, the most commonly injured tendon is the supraspinatus as this tendon is prone to repeated impingement trauma between the humeral head and the acromion, especially in abduction. The supraspinatus is primarily an abductor of the arm; it originates in the supraspinous fossa of the scapula and inserts on the superior portion of the head of the humerus. Therefore, supraspinatus tendinopathy is associated with pain on abduction of the humerus, especially resisted active abduction.

(Choice B) Adduction of the humerus is accomplished by several muscles, including the latissimus dorsi, pectoralis major, coracobrachialis, subscapularis, and teres major and minor.

(Choice C) Extension of the humerus is accomplished primarily by the latissimus dorsi, posterior deltoid, and teres major.

(Choice D) Flexion of the humerus at the shoulder is accomplished primarily by the pectoralis major, coracobrachialis, biceps brachii, and anterior deltoid.

(Choice E) Internal rotation of the humerus is accomplished by the subscapularis muscle, which originates in the subscapular fossa and inserts on the lesser tubercle of the head of the humerus with contribution from the teres major, pectoralis major, anterior deltoid, and latissimus dorsi.

Educational objective:
The most commonly injured structure in rotator cuff syndrome is the tendon of the supraspinatus muscle. Because the supraspinatus is an abductor of the humerus, injury to its tendon causes pain on abduction of the arm.

Anatomy	Rheumatology/Orthopedics & Sports	Rotator cuff
Subject	System	Topic

Copyright © UWorld. All rights reserved.

	fossa		(primarily <15°)	

Exhibit Display

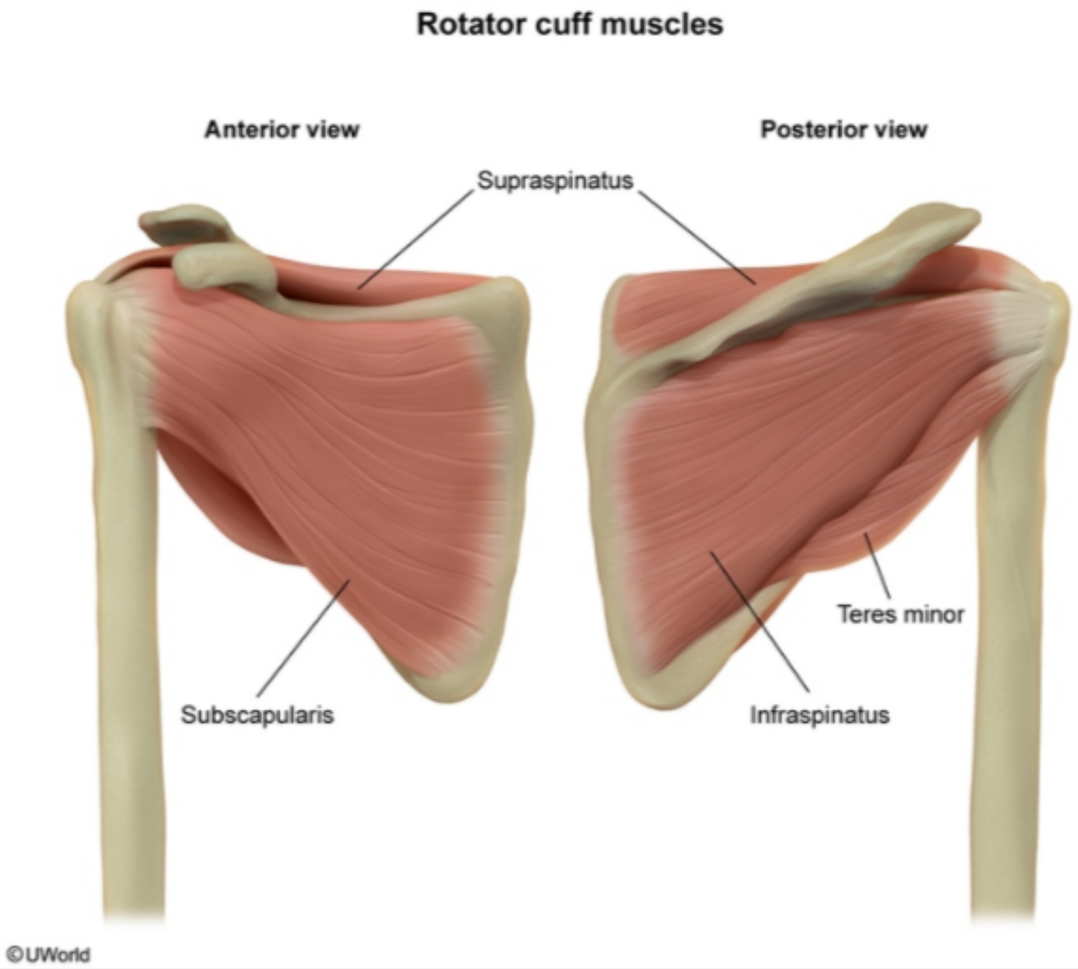

Zoom In | Zoom Out | Reset | Add To New Card | Existing Card

abductor of the humerus; injury to its tendon causes pain on abduction of the arm.

	fossa		(primarily <15°)	

Exhibit Display

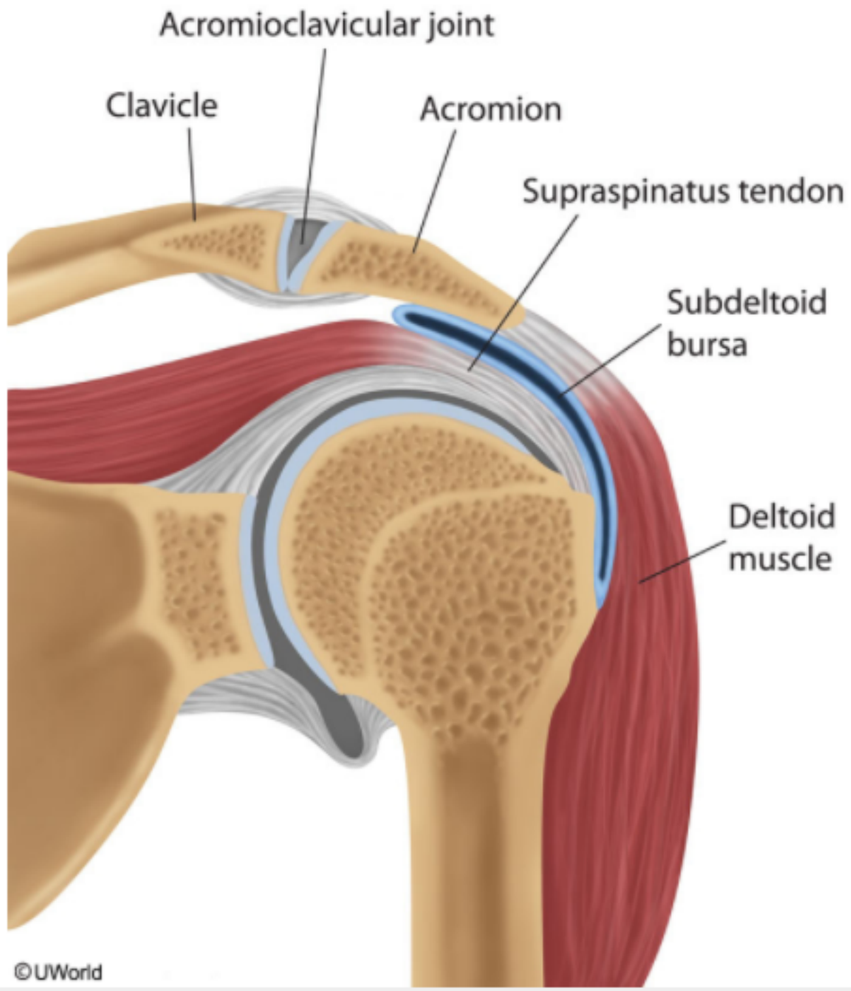

Zoom In | Zoom Out | Reset | Add To New Card | Existing Card

abductor of the humerus; injury to its tendon causes pain on abduction of the arm.

A 3-year-old boy is brought to the emergency department after falling off a jungle gym. The boy tried to catch himself and landed on his outstretched arms. He did not lose consciousness and has been crying inconsolably since he fell. Pulse is 140/min; all other vital signs are within normal limits. Physical examination reveals tenderness and swelling over the anterior portion of his right shoulder with crepitus over the swollen area. An x-ray of his right shoulder is shown below.

Tension from which of the following muscles is most likely responsible for displacement of the distal bone fragment?

10
11
12
13
14
15
16
17
18
19
20
21
22
23
24
25
26
27
28
29
30
31
32
33
34
35
36
37
38
39
40

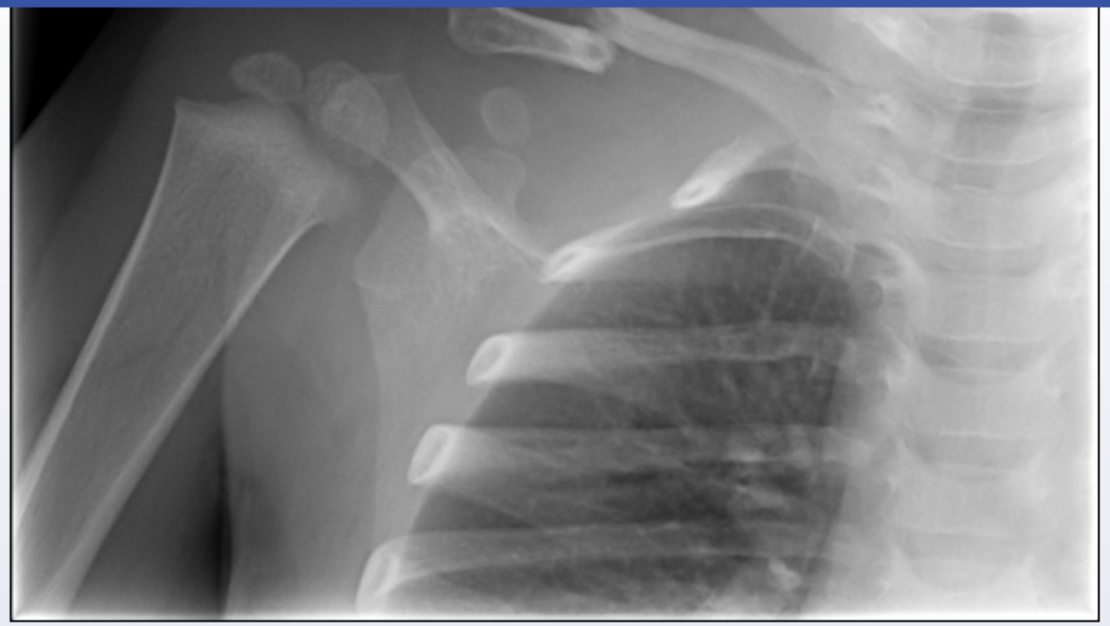

Tension from which of the following muscles is most likely responsible for displacement of the distal bone fragment?

A. Biceps
B. Deltoid
C. Levator scapulae
D. Pectoralis minor
E. Teres minor

Submit

10
11
12
13
14
15
16
17
18
19
20
21
22
23
24
25
26
27
28
29
30
31
32
33
34
35
36
37
38
39
40

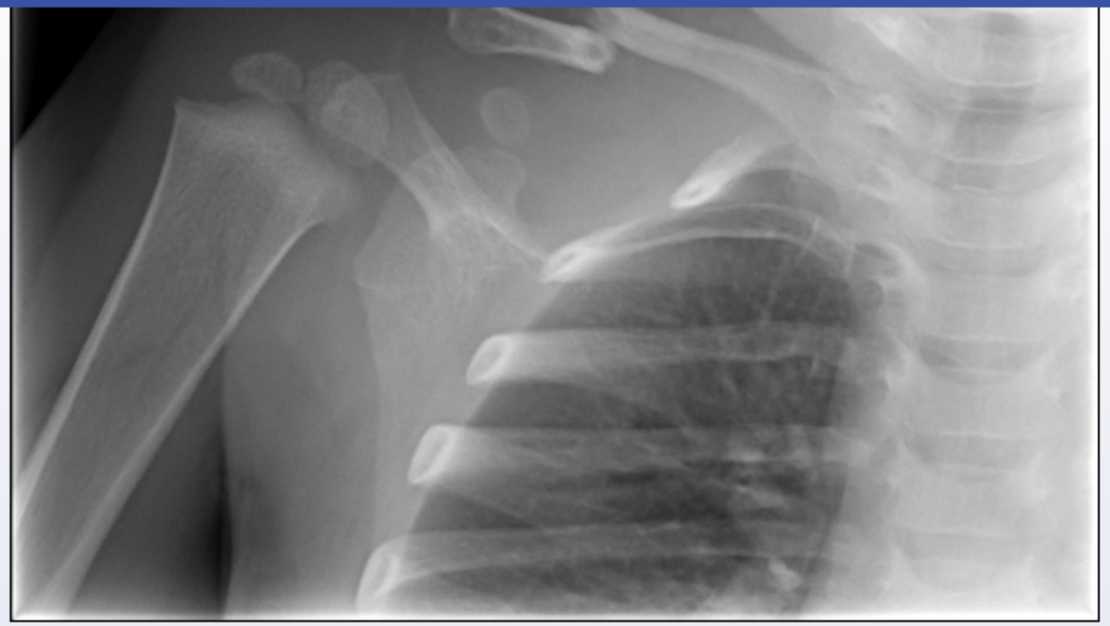

Tension from which of the following muscles is most likely responsible for displacement of the distal bone fragment?

A. Biceps (5%)
✓ B. Deltoid (37%)
C. Levator scapulae (16%)
D. Pectoralis minor (31%)
E. Teres minor (8%)

Omitted
Correct answer

37%
Answered correctly

05 secs
Time Spent

02/02/2020
Last Updated

10
11
12
13
14
15
16
17
18
19
20
21
22
23
24
25
26
27
28
29
30
31
32
33
34
35
36
37
38
39
40

Distal clavicle fracture

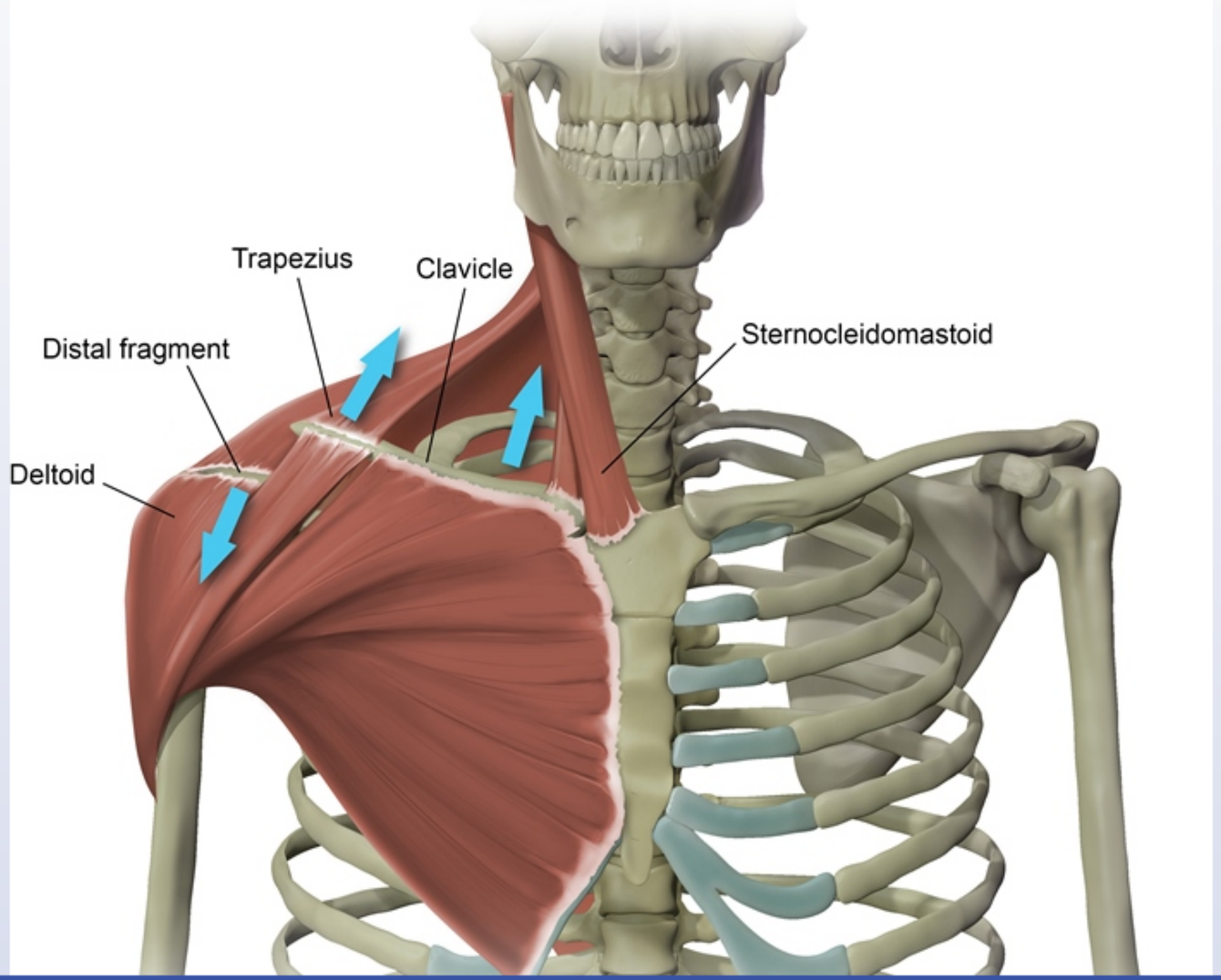

10
11
12
13
14
15
16
17
18
19
20
21
22
23
24
25
26
27
28
29
30
31
32
33
34
35
36
37
38
39
40

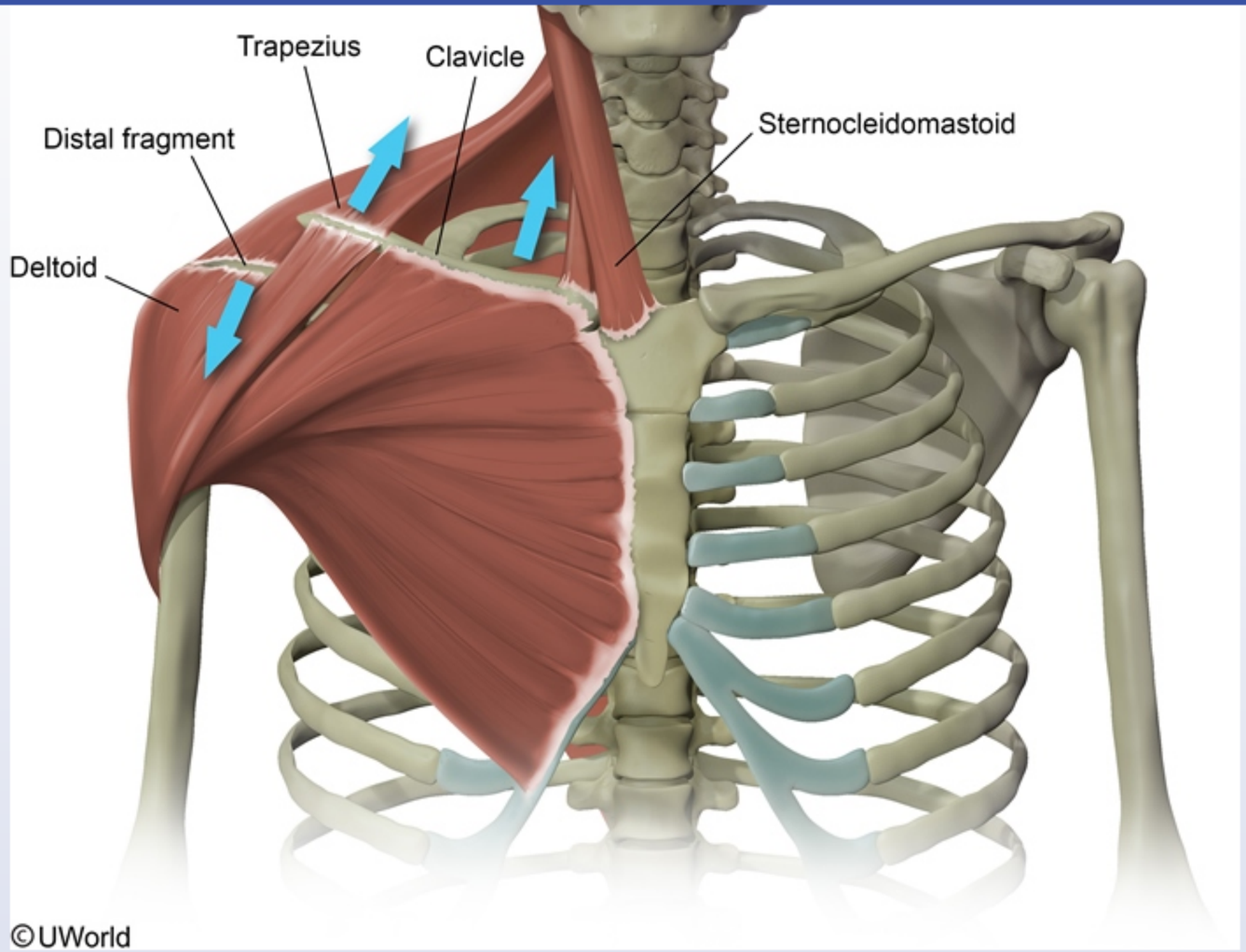

This patient has a displaced **fracture** of the **distal clavicle**, a commonly fractured bone. The clavicle is the only bone affixing the upper extremity and shoulder girdle to the thorax, and it can be subjected to significant forces during an injury, such as a fall onto the shoulder or outstretched arm.

Because of their attachments on the clavicle, numerous muscles can apply tension on the proximal or distal bone fragments of a clavicle fracture. The anterior portion of the **deltoid muscle** originates on the distal clavicle and inserts onto the humerus. Normally, this part of the muscle acts to

©UWorld

This patient has a displaced **fracture** of the **distal clavicle**, a commonly fractured bone. The clavicle is the only bone affixing the upper extremity and shoulder girdle to the thorax, and it can be subjected to significant forces during an injury, such as a fall onto the shoulder or outstretched arm.

Because of their attachments on the clavicle, numerous muscles can apply tension on the proximal or distal bone fragments of a clavicle fracture. The anterior portion of the **deltoid muscle** originates on the distal clavicle and inserts onto the humerus. Normally, this part of the muscle acts to abduct, flex, and medially rotate the humerus. However, in a distal clavicle fracture, deltoid muscle tone and the weight of the upper extremity act to pull the **distal fragment** in the **inferolateral** direction. The proximal segment of the bone is pulled in the superomedial direction by the sternocleidomastoid and trapezius muscles. The net effect is to displace the fracture, which increases the risk of **nonunion**.

(Choice A) The biceps brachii originates on the supraglenoid tubercle (long head) and coracoid process (short head) of the scapula. It inserts onto the radial tuberosity and bicipital aponeurosis of the forearm.

(Choice C) The levator scapulae originates on the C1-C4 vertebrae and spans to the superomedial scapula. This muscle raises the scapula and rotates the acromion inferiorly.

(Choice D) The pectoralis minor spans from the coracoid process of the scapula to the third, fourth, and fifth ribs and stabilizes the scapula against the thoracic wall.

(Choice E) The teres minor spans from the lateral scapula to the greater tubercle of the humerus. It stabilizes the glenohumeral joint and laterally rotates the humerus.

Educational objective:
The clavicle is commonly fractured in children after a fall on an outstretched arm. In a distal clavicle fracture, the deltoid muscle and the weight of the arm cause inferolateral displacement of the distal fragment, whereas the sternocleidomastoid and trapezius muscles cause superomedial displacement of the proximal fragment.

References

- Clavicle fractures: a review of the literature and update on treatment.

Anatomy | Rheumatology/Orthopedics & Sports | Clavicle fracture

10
11
12
13
14
15
16
17
18
19
20
21
22
23
24
25
26
27
28
29
30
31
32
33
34
35
36
37
38
39
40

A 56-year-old man comes to the emergency department due to persistent left wrist pain. While walking his dog 5 hours ago, he fell forward onto the ground and landed on his outstretched hand. Examination shows mild left wrist swelling with preserved range of motion. There is point tenderness over the dorsolateral aspect of the wrist between the tendons of the extensor pollicis longus and extensor pollicis brevis. An x-ray of the left wrist is shown in the image below:

10
11
12
13
14
15
16
17
18
19
20
21
22
23
24
25
26
27
28
29
30
31
32
33
34
35
36
37
38
39
40

©UWorld

This patient is at greatest risk for developing which of the following complications?

A. Avascular necrosis

B. Carpal tunnel syndrome

C. Compartment syndrome

D. Dupuytren contracture

E. Guyon canal syndrome

Submit

10
11
12
13
14
15
16
17
18
19
20
21
22
23
24
25
26
27
28
29
30
31
32
33
34
35
36
37
38
39
40

©UWorld

This patient is at greatest risk for developing which of the following complications?

- ✓ A. Avascular necrosis (82%)
- B. Carpal tunnel syndrome (6%)
- C. Compartment syndrome (2%)
- D. Dupuytren contracture (2%)
- E. Guyon canal syndrome (6%)

Omitted
Correct answer

82%
Answered correctly

04 secs
Time Spent

03/27/2020
Last Updated

10
11
12
13
14
15
16
17
18
19
20
21
22
23
24
25
26
27
28
29
30
31
32
33
34
35
36
37
38
39
40

Scaphoid avascular necrosis

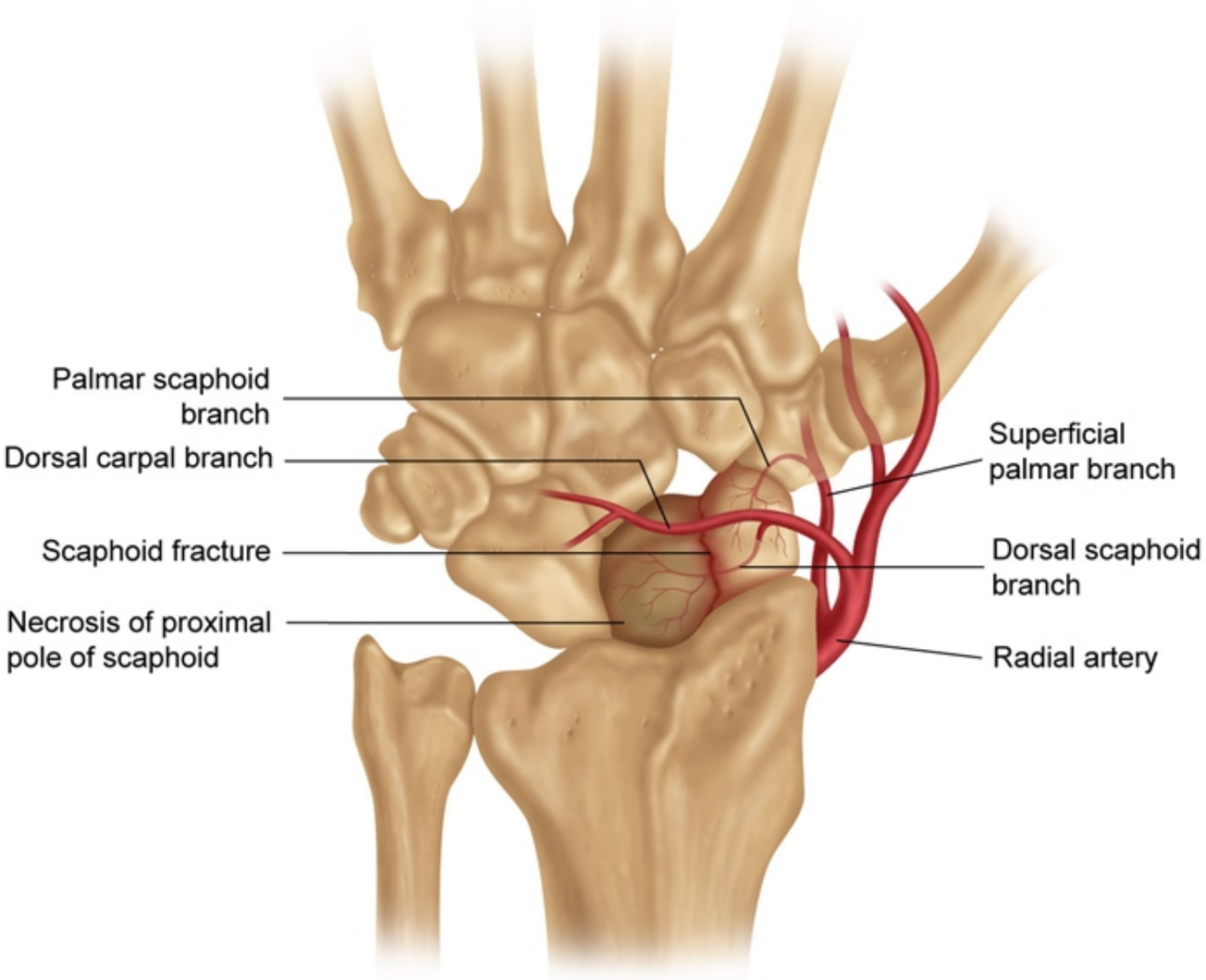

©UWorld

Scaphoid fractures are the most common carpal bone fracture and frequently result from a **fall** on an **outstretched hand** that causes direct axial compression or hyperextension of the wrist. A scaphoid fracture should be suspected in any patient with persistent wrist pain and **tenderness** in the anatomic snuffbox—a shallow, triangular depression at the dorsoradial wrist defined by the following borders:

- Medial: tendon of the extensor pollicis longus
- Lateral: tendons of the abductor pollicis longus and extensor pollicis brevis
- Proximal: styloid process of the radius
- **Floor: scaphoid** and trapezium bones

The main blood supply to the scaphoid is provided by the dorsal scaphoid branch of the radial artery; this branch enters near the bone's distal pole and then proceeds in a retrograde manner to provide blood supply to the proximal pole. Because fracture of the scaphoid can easily interrupt this retrograde flow, the fractured scaphoid is at risk for **avascular necrosis** of the proximal pole and fracture **nonunion**.

(Choice B) Carpal tunnel syndrome is caused by median nerve compression at the wrist within the carpal tunnel. It is mostly commonly nontraumatic in origin, but when it does occur following trauma (eg, fall on an outstretched hand), it is typically due to palmar dislocation of the lunate into the carpal tunnel space.

(Choice C) Acute compartment syndrome occurs when increased pressure within a fascial compartment (eg, intracompartmental bleeding, muscle swelling) compromises blood circulation within that space. It typically develops after significant trauma, particularly long bone fractures of the leg or forearm.

(Choice D) Dupuytren contracture is a slowly progressive fibroproliferative disease of the palmar fascia. Nodules form on the fascia, eventually resulting in contractures that draw the fingers into flexion.

(Choice E) Guyon canal syndrome is caused by compression of the ulnar nerve at the wrist within Guyon canal. It can develop following a fall on an outstretched hand but typically occurs due to fracture of the hook of the hamate, which forms the lateral bony wall of Guyon canal.

Educational objective:
Fracture of the scaphoid bone may result from a fall on an outstretched hand and should be suspected if examination shows tenderness in the anatomic snuff box. Scaphoid fracture can disrupt retrograde blood supply to the proximal scaphoid, increasing risk of avascular necrosis.

References

and then proceeds in a retrograde manner to provide blood supply to the proximal pole. Because fracture of the scaphoid can easily interrupt this retrograde flow, the fractured scaphoid is at risk for **avascular necrosis** of the proximal pole and fracture **nonunion**.

(Choice B) Carpal tunnel syndrome is caused by median nerve compression at the wrist within the carpal tunnel. It is mostly commonly nontraumatic in origin, but when it does occur following trauma (eg, fall on an outstretched hand), it is typically due to palmar dislocation of the lunate into the carpal tunnel space.

(Choice C) Acute compartment syndrome occurs when increased pressure within a fascial compartment (eg, intracompartmental bleeding, muscle swelling) compromises blood circulation within that space. It typically develops after significant trauma, particularly long bone fractures of the leg or forearm.

(Choice D) Dupuytren contracture is a slowly progressive fibroproliferative disease of the palmar fascia. Nodules form on the fascia, eventually resulting in contractures that draw the fingers into flexion.

(Choice E) Guyon canal syndrome is caused by compression of the ulnar nerve at the wrist within Guyon canal. It can develop following a fall on an outstretched hand but typically occurs due to fracture of the hook of the hamate, which forms the lateral bony wall of Guyon canal.

Educational objective:
Fracture of the scaphoid bone may result from a fall on an outstretched hand and should be suspected if examination shows tenderness in the anatomic snuff box. Scaphoid fracture can disrupt retrograde blood supply to the proximal scaphoid, increasing risk of avascular necrosis.

References

- Fractures in brief: scaphoid fractures.
- Management of scaphoid fractures.
- Posttraumatic avascular necrosis after proximal femur, proximal humerus, talar neck, and scaphoid fractures.

Anatomy	Rheumatology/Orthopedics & Sports	Scaphoid fracture
Subject	System	Topic

Copyright © UWorld. All rights reserved.

10
11
12
13
14
15
16
17
18
19
20
21
22
23
24
25
26
27
28
29
30
31
32
33
34
35
36
37
38
39
40

pole of scaphoid

Radial artery

Exhibit Display

Scaphoid fracture

©UWorld

Zoom In | Zoom Out | Reset | Add To New Card | Existing Card

the leg or forearm.

10
11
12
13
14
15
16
17
18
19
20
21
22
23
24
25
26
27
28
29
30
31
32
33
34
35
36
37
38
39
40

pole of scaphoid

Radial artery

Exhibit Display

Anatomic snuffbox

Zoom In | Zoom Out | Reset | Add To New Card | Existing Card

the leg or forearm.

10
11
12
13
14
15
16
17
18
19
20
21
22
23
24
25
26
27
28
29
30
31
32
33
34
35
36
37
38
39
40

pole of scaphoid

Radial artery

Exhibit Display

Carpal tunnel, palmar view

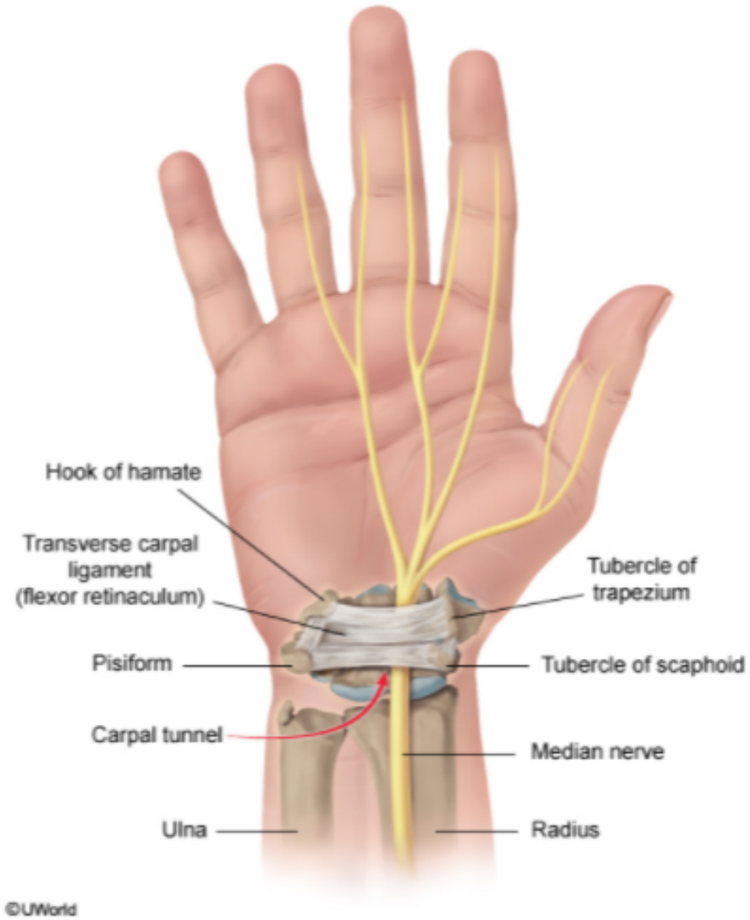

Zoom In | Zoom Out | Reset | Add To New Card | Existing Card

the leg or forearm.

and then proceeds in a retrograde manner to provide blood supply to the proximal pole. Because fracture of the scaphoid can easily interrupt this

Exhibit Display

Zoom In | Zoom Out | Reset | Add To New Card | Existing Card

10
11
12
13
14
15
16
17
18
19
20
21
22
23
24
25
26
27
28
29
30
31
32
33
34
35
36
37
38
39
40

and then proceeds in a retrograde manner to provide blood supply to the proximal pole. Because fracture of the scaphoid can easily interrupt this

Exhibit Display

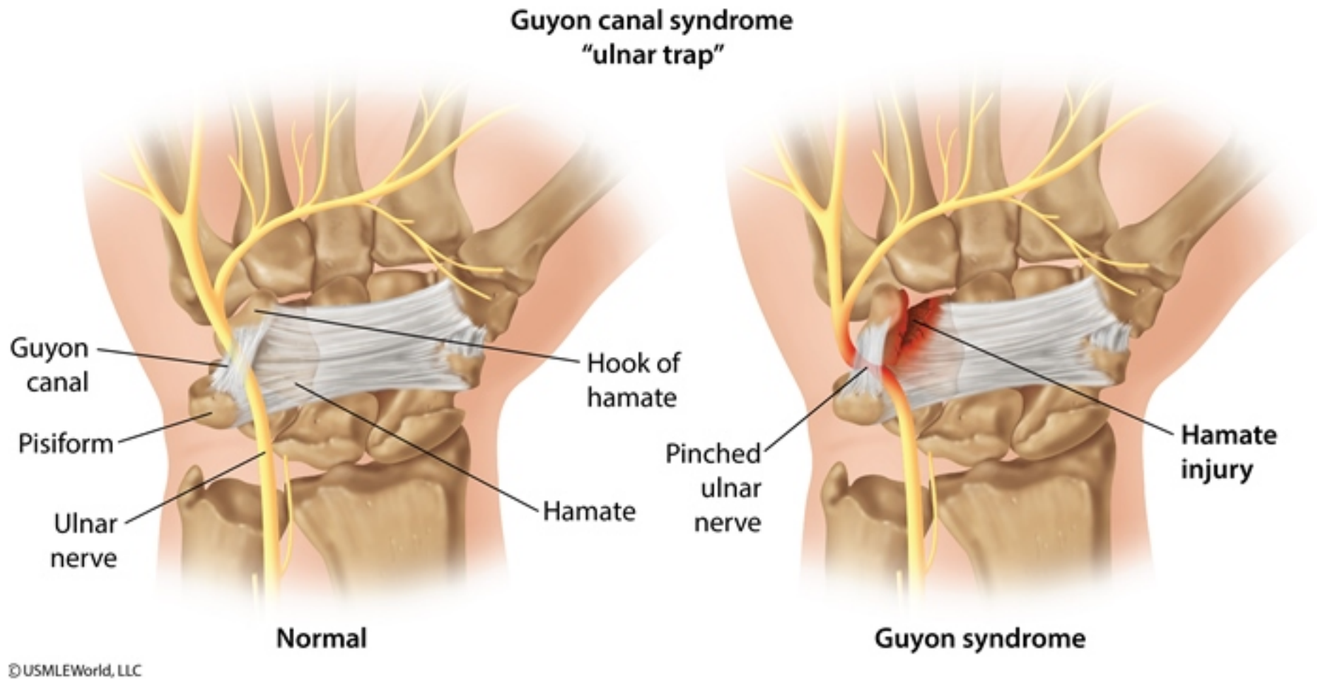

Zoom In | Zoom Out | Reset | Add To New Card | Existing Card

10
11
12
13
14
15
16
17
18
19
20
21
22
23
24
25
26
27
28
29
30
31
32
33
34
35
36
37
38
39
40

A 46-year-old woman is brought by ambulance to the emergency department following a ground-level fall at home. She slipped while getting out of the shower and hit her left knee on the tile floor. The patient developed severe left knee pain and swelling and is unable to ambulate. Examination shows a contusion and soft tissue swelling at the knee with a large knee effusion. X-ray of the knee is shown in the image below:

10
11
12
13
14
15
16
17
18
19
20
21
22
23
24
25
26
27
28
29
30
31
32
33
34
35
36
37
38
39
40

Which of the following examination findings would most likely be seen in this patient?

10
11
12
13
14
15
16
17
18
19
20
21
22
23
24
25
26
27
28
29
30
31
32
33
34
35
36
37
38
39
40

Which of the following examination findings would most likely be seen in this patient?

A. Backward movement of the tibia against a fixed femur

B. Excessive joint widening on valgus stress

C. Forward movement of the tibia against a fixed femur

D. Inability to extend the knee against gravity

E. Inability to flex the knee against resistance

Submit

10
11
12
13
14
15
16
17
18
19
20
21
22
23
24
25
26
27
28
29
30
31
32
33
34
35
36
37
38
39
40

Which of the following examination findings would most likely be seen in this patient?

A. Backward movement of the tibia against a fixed femur (2%)

B. Excessive joint widening on valgus stress (1%)

C. Forward movement of the tibia against a fixed femur (6%)

✓ D. Inability to extend the knee against gravity (79%)

E. Inability to flex the knee against resistance (9%)

Omitted
Correct answer

79%
Answered correctly

08 secs
Time Spent

06/07/2020
Last Updated

10
11
12
13
14
15
16
17
18
19
20
21
22
23
24
25
26
27
28
29
30
31
32
33
34
35
36
37
38
39
40

This patient has a comminuted **patella fracture**. The patella is a large sesamoid bone that facilitates knee extension, protects the joint from direct injury, and improves nourishment of the distal femur articular cartilage. The quadriceps tendon inserts at the superior pole of the patella and wraps distally around the patella to become the patellar tendon, which inserts at the tibial tuberosity.

Patella fractures are most commonly due to a **direct blow** to the **anterior aspect** of the knee (eg, landing on a flexed knee in a fall, striking the knee against the dashboard in a frontal motor vehicle collision). The patella can also be fractured indirectly due to excessive force transmitted through the quadriceps tendon (eg, landing on the feet after falling from a height). Patients develop acute swelling (often with an associated effusion), focal tenderness, **inability to extend the knee** against gravity, and a **palpable gap** in the extensor mechanism.

This patient has a comminuted **patella fracture**. The patella is a large sesamoid bone that facilitates knee extension, protects the joint from direct injury, and improves nourishment of the distal femur articular cartilage. The quadriceps tendon inserts at the superior pole of the patella and wraps distally around the patella to become the patellar tendon, which inserts at the tibial tuberosity.

Patella fractures are most commonly due to a **direct blow** to the **anterior aspect** of the knee (eg, landing on a flexed knee in a fall, striking the knee against the dashboard in a frontal motor vehicle collision). The patella can also be fractured indirectly due to excessive force transmitted through the quadriceps tendon (eg, landing on the feet after falling from a height). Patients develop acute swelling (often with an associated effusion), focal tenderness, **inability to extend the knee** against gravity, and a **palpable gap** in the extensor mechanism.

(Choice A) The posterior cruciate ligament (PCL) protects against excessive posterior knee movement and is the least frequently injured knee ligament. PCL injury results in a positive posterior drawer test (increased backward movement of the tibia against a fixed femur).

(Choice B) The medial collateral ligament (MCL) protects against valgus stress on the knee and excessive external tibial rotation. MCL injury occurs after a lateral blow to the knee or indirect stress from excessive lower leg rotation or abduction. Patients have excessive joint widening on valgus stress (eg, the femur is held in a fixed position while an abducting [lateral] force is applied to the lower leg/foot).

(Choice C) The anterior cruciate ligament (ACL) controls anterior knee movement and prevents excessive tibial rotation. ACL injury often occurs due to sudden acceleration or deceleration in noncontact athletic injuries. Patients have laxity of forward movement of the tibia against a fixed femur (anterior drawer test).

(Choice E) Knee flexors include the hamstring muscles (biceps femoris, semitendinosus, semimembranosus), gracilis, gastrocnemius, and sartorius. Hamstring injury can decrease hip extension and knee flexion. However, these muscles do not involve the patella.

Educational objective:
Patella fractures are most commonly due to a direct impact to the anterior aspect of the knee. Signs include an acutely swollen knee, focal patella tenderness, inability to extend the knee against gravity, and a palpable gap in the extensor mechanism.

References

- Patellar fractures in adults.

injury, and improves nourishment of the distal femur articular cartilage. The quadriceps tendon inserts at the superior pole of the patella and wraps

Exhibit Display

Medial collateral ligament injury

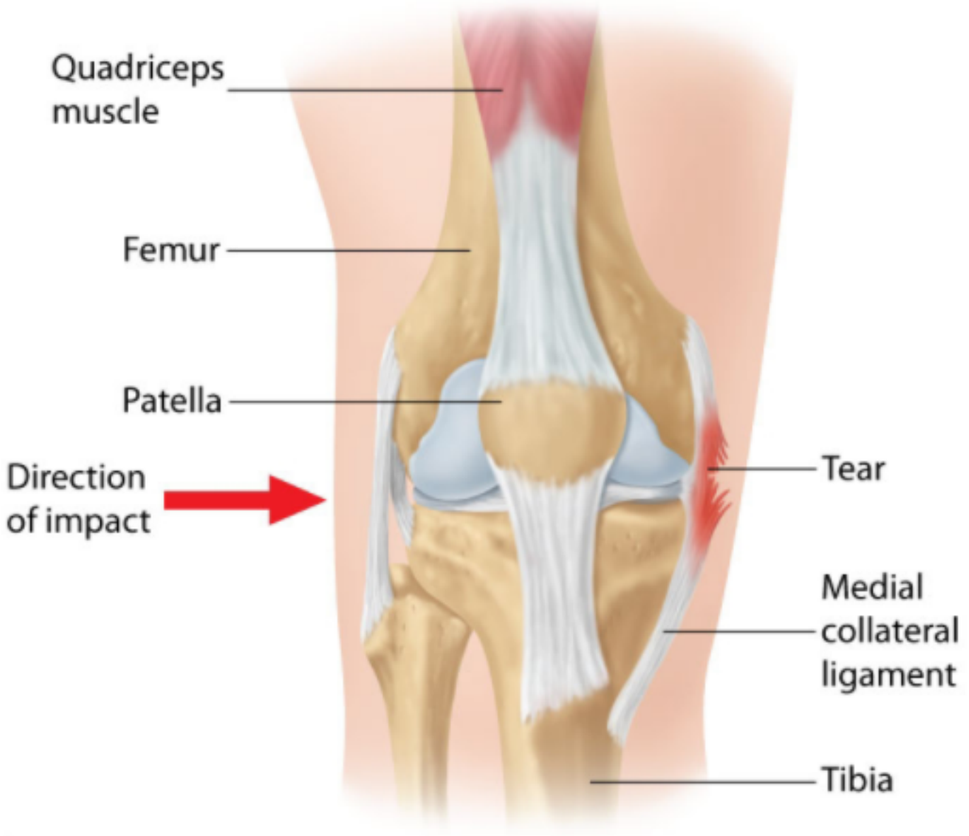

©UWorld

Zoom In | Zoom Out | Reset | Add To New Card | Existing Card

injury, and improves nourishment of the distal femur articular cartilage. The quadriceps tendon inserts at the superior pole of the patella and wraps

Exhibit Display

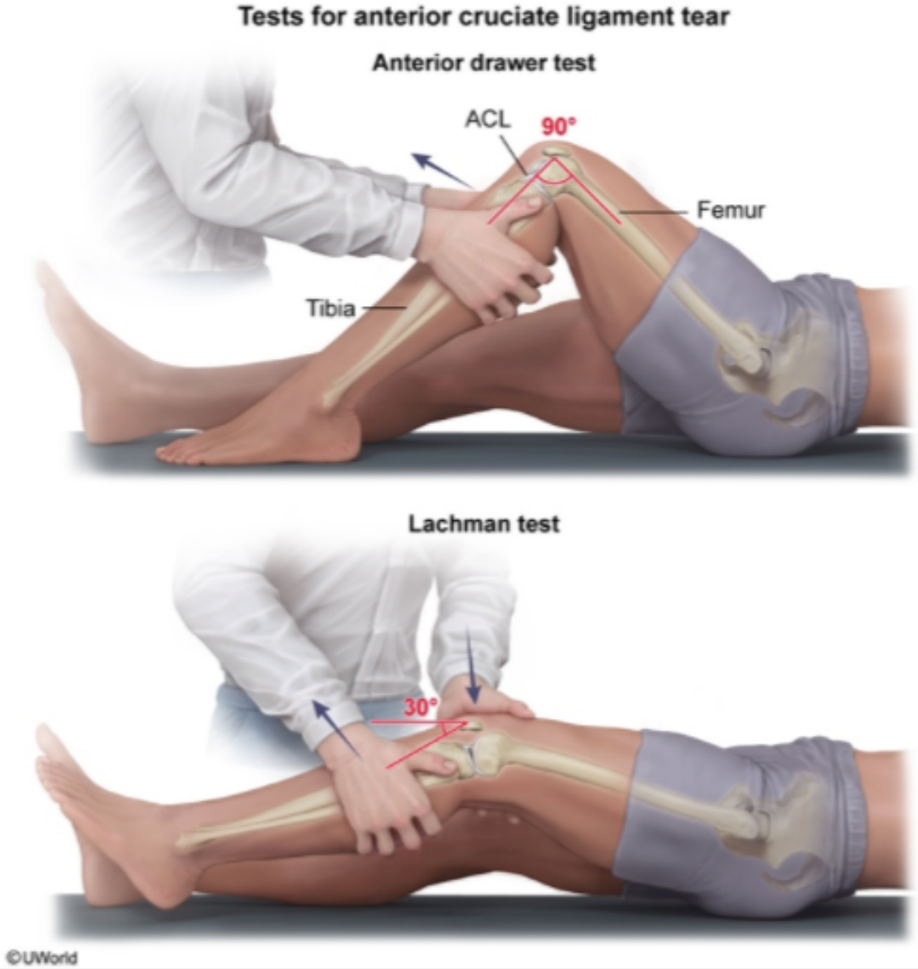

Zoom In | Zoom Out | Reset | Add To New Card | Existing Card

A 34-year-old woman comes to the physician complaining of easy fatigability. She lives alone and works as an accountant. Her menstrual cycles are regular and her last menstrual period was 2 weeks ago. She does not smoke or consume alcohol. Her blood pressure is 150/90 mm Hg and pulse is 82/min. During her physical examination, she sits up from the supine position without using her hands. Which of the following muscles contributes most to the described movement?

- A. Adductor magnus
- B. Biceps femoris, long head
- C. Gluteus medius
- D. Obturator externus
- E. Psoas major
- F. Vastus medialis

Submit

A 34-year-old woman comes to the physician complaining of easy fatigability. She lives alone and works as an accountant. Her menstrual cycles are regular and her last menstrual period was 2 weeks ago. She does not smoke or consume alcohol. Her blood pressure is 150/90 mm Hg and pulse is 82/min. During her physical examination, she sits up from the supine position without using her hands. Which of the following muscles contributes most to the described movement?

- A. Adductor magnus (2%)
- B. Biceps femoris, long head (5%)
- C. Gluteus medius (10%)
- D. Obturator externus (2%)
- ✓ E. Psoas major (72%)
- F. Vastus medialis (5%)

Omitted
Correct answer
E

72%
Answered correctly

02 secs
Time Spent

06/24/2020
Last Updated

Explanation

Major muscles responsible for motion at the hip			
Flexion	Extension	Abduction	Adduction
	• Gluteus maximus		

Major muscles responsible for motion at the hip			
Flexion	**Extension**	**Abduction**	**Adduction**
• Iliopsoas • Rectus femoris • Tensor fascia lata	• Gluteus maximus • Semitendinosus • Semimembranosus • Biceps femoris - long head	• Gluteus medius • Gluteus minimus	• Adductor brevis • Adductor longus • Adductor magnus

Major muscles used when sitting up from the supine position include the external abdominal obliques, the rectus abdominis, and the hip flexors. The psoas major and iliacus contribute most significantly to the hip flexion; they, along with the psoas minor, are collectively known as the iliopsoas. The capacity of these muscles to carry out this motion can be deduced from the fact that they originate on the pelvis and spinal column, cross the hip joint, and insert on the femur.

The psoas major muscle arises from the bodies and intervertebral discs of the inferior-most thoracic and all of the lumbar vertebrae. The iliacus originates from the iliac fossa, a large concave surface found on the inner aspect of the ilium. Both muscles insert via the common iliopsoas tendon into the lesser trochanter of the femur.

(Choice A) The adductor portion of the adductor magnus originates from the inferior ramus of the ischium and inserts into the proximal two-thirds of the posteromedial femur. It is a powerful adductor of the thigh.

(Choice B) The long head of the biceps femoris originates from the ischial tuberosity and inserts into the lateral head of the fibula; it functions as a thigh extensor and leg flexor.

(Choice C) The gluteus medius abducts the femur and is important in keeping the hip level during gait when the body's weight rests on one leg.

(Choice D) The obturator externus arises from the anteromedial surface of the obturator foramen and inserts near the greater trochanter of the femur. This muscle is a lateral rotator of the thigh.

(Choice F) The vastus medialis is a component of the quadriceps femoris. It arises from the proximal femur and ultimately inserts into the tibial

The psoas major and iliacus contribute most significantly to the hip flexion; they, along with the psoas minor, are collectively known as the iliopsoas. The capacity of these muscles to carry out this motion can be deduced from the fact that they originate on the pelvis and spinal column, cross the hip joint, and insert on the femur.

The psoas major muscle arises from the bodies and intervertebral discs of the inferior-most thoracic and all of the lumbar vertebrae. The iliacus originates from the iliac fossa, a large concave surface found on the inner aspect of the ilium. Both muscles insert via the common iliopsoas tendon into the lesser trochanter of the femur.

(Choice A) The adductor portion of the adductor magnus originates from the inferior ramus of the ischium and inserts into the proximal two-thirds of the posteromedial femur. It is a powerful adductor of the thigh.

(Choice B) The long head of the biceps femoris originates from the ischial tuberosity and inserts into the lateral head of the fibula; it functions as a thigh extensor and leg flexor.

(Choice C) The gluteus medius abducts the femur and is important in keeping the hip level during gait when the body's weight rests on one leg.

(Choice D) The obturator externus arises from the anteromedial surface of the obturator foramen and inserts near the greater trochanter of the femur. This muscle is a lateral rotator of the thigh.

(Choice F) The vastus medialis is a component of the quadriceps femoris. It arises from the proximal femur and ultimately inserts into the tibial tuberosity by means of the patella. It functions as a knee extensor.

Educational objective:
Muscles used when sitting up from the supine position include the external abdominal obliques, the rectus abdominis, and the hip flexors. The iliopsoas muscle is the most important of the hip flexors and includes the psoas major, psoas minor, and iliacus. The rectus femoris, sartorius, tensor fascia lata, and the medial compartment of the thigh also contribute to hip flexion.

Anatomy	Rheumatology/Orthopedics & Sports	Hip muscle
Subject	System	Topic

Copyright © UWorld. All rights reserved.

10
11
12
13
14
15
16
17
18
19
20
21
22
23
24
25
26
27
28
29
30
31
32
33
34
35
36
37
38
39
40

A 54-year-old woman comes to the office due to right upper limb weakness and fatigue. She has no problem during most activities but develops symptoms when attempting to raise her arm overhead. The patient first noticed the symptoms after a recent hospitalization. On examination, there is no sensory loss in the upper extremities, but she has difficulty abducting her right arm past the horizontal position. The patient is instructed to press her outstretched arms against a wall, and the medial border of the right scapula lifts off the thoracic wall and becomes prominent. This patient was most likely hospitalized for which of the following conditions?

A. Anterior dislocation of the shoulder joint

B. Fracture of the middle third of the clavicle

C. Mastectomy with axillary lymph node removal

D. Total thyroidectomy

E. Violent stretch between the head and the shoulder

Submit

A 54-year-old woman comes to the office due to right upper limb weakness and fatigue. She has no problem during most activities but develops symptoms when attempting to raise her arm overhead. The patient first noticed the symptoms after a recent hospitalization. On examination, there is no sensory loss in the upper extremities, but she has difficulty abducting her right arm past the horizontal position. The patient is instructed to press her outstretched arms against a wall, and the medial border of the right scapula lifts off the thoracic wall and becomes prominent. This patient was most likely hospitalized for which of the following conditions?

A. Anterior dislocation of the shoulder joint (6%)

B. Fracture of the middle third of the clavicle (4%)

✓ C. Mastectomy with axillary lymph node removal (79%)

D. Total thyroidectomy (1%)

E. Violent stretch between the head and the shoulder (7%)

Omitted
Correct answer
C

79%
Answered correctly

02 secs
Time Spent

04/26/2020
Last Updated

Explanation

This patient has paralysis of the **serratus anterior** muscle due to **long thoracic nerve** injury. The serratus anterior originates on the surface of the first 8 ribs and inserts on the medial border of the scapula. It functions to stabilize and **rotate the scapula upward**. The deltoid and supraspinatus muscles abduct the arm up to the horizontal position, after which the serratus anterior and trapezius are required to rotate the glenoid cavity superiorly, thereby allowing complete abduction of the arm over the head.

Innervation of the serratus anterior is from the long thoracic nerve, which arises from the C5-C7 nerve roots via the brachial plexus and follows a

This patient has paralysis of the **serratus anterior** muscle due to **long thoracic nerve** injury. The serratus anterior originates on the surface of the first 8 ribs and inserts on the medial border of the scapula. It functions to stabilize and **rotate the scapula upward**. The deltoid and supraspinatus muscles abduct the arm up to the horizontal position, after which the serratus anterior and trapezius are required to rotate the glenoid cavity superiorly, thereby allowing complete abduction of the arm over the head.

Innervation of the serratus anterior is from the long thoracic nerve, which arises from the C5-C7 nerve roots via the brachial plexus and follows a lengthy course along the lateral chest wall. Injury to the nerve can occur during penetrating trauma or iatrogenically during **axillary lymph node dissection** or chest tube insertion. Paralysis of the serratus anterior causes scapular winging due to inability of the serratus to hold the scapula against the thorax. Patients will also show weakness in abducting the arm above horizontal due to impaired rotation of the scapula.

(Choice A) Anterior dislocation of the shoulder or fracture of the neck of the humerus can injure the axillary nerve. This causes paralysis of the deltoid and teres minor muscles and localized sensory loss in the upper arm.

(Choice B) Clavicular fracture only occasionally causes neurovascular compromise, usually involving the subclavian vessels and supraclavicular nerve.

(Choice D) Thyroidectomy may cause injury to the recurrent laryngeal nerve. Injury causes weakness of the posterior cricoarytenoid muscles, with hoarseness and impaired breathing.

(Choice E) Injury to the upper brachial plexus (musculocutaneous and suprascapular nerves) can occur due to traction between the head and shoulder. This can occur in the neonate due to dystocia or in the adult from violent injury. The resulting palsy is characterized by shoulder adduction, elbow extension, and forearm pronation.

Educational objective:
Dissection of the axillary lymph nodes can injure the long thoracic nerve. This results in weakness of the serratus anterior with winging of the scapula and impaired abduction of the shoulder past the horizontal.

References

- Long thoracic nerve injury in breast cancer patients treated with axillary lymph node dissection.

Anatomy	Rheumatology/Orthopedics & Sports	Brachial plexus
Subject	System	Topic

This patient has paralysis of the **serratus anterior** muscle due to **long thoracic nerve** injury. The serratus anterior originates on the surface of

Exhibit Display

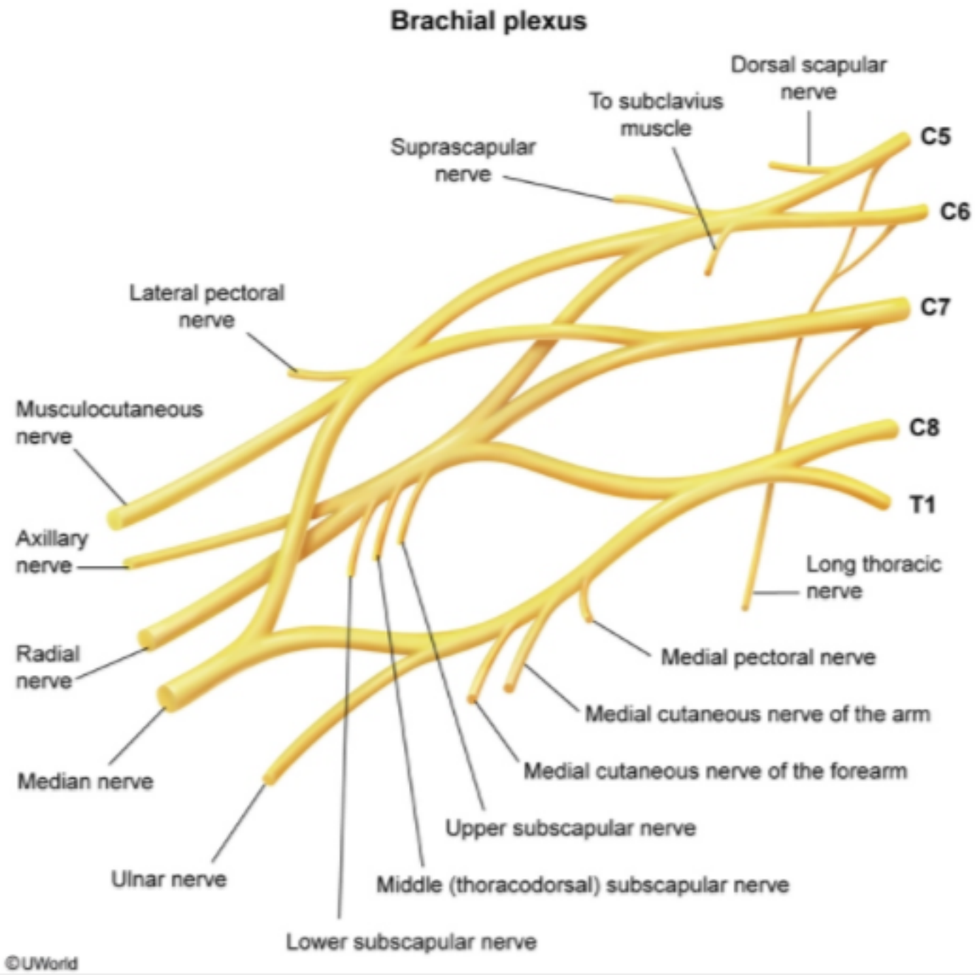

Zoom In | Zoom Out | Reset | Add To New Card | Existing Card

Subject System Topic

This patient has paralysis of the **serratus anterior** muscle due to **long thoracic nerve** injury. The serratus anterior originates on the surface of

Exhibit Display

Winging of scapula

Zoom In | Zoom Out | Reset | Add To New Card | Existing Card

Subject System Topic

10
11
12
13
14
15
16
17
18
19
20
21
22
23
24
25
26
27
28
29
30
31
32
33
34
35
36
37
38
39
40

This patient has paralysis of the **serratus anterior** muscle due to **long thoracic nerve** injury. The serratus anterior originates on the surface of

Exhibit Display

Upper plexus lesions

Bellman's or Waiter's tip pose

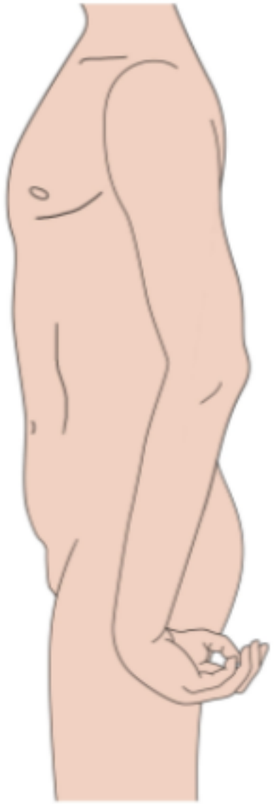

USMLEWorld, LLC © 2011

Zoom In | Zoom Out | Reset | Add To New Card | Existing Card

10
11
12
13
14
15
16
17
18
19
20
21
22
23
24
25
26
27
28
29
30
31
32
33
34
35
36
37
38
39
40

Subject System Topic

10
11
12
13
14
15
16
17
18
19
20
21
22
23
24
25
26
27
28
29
30
31
32
33
34
35
36
37
38
39
40

A 43-year-old man comes to the office due to difficulty walking. The patient was seen at an outpatient clinic 2 days ago and received a right-sided deep intramuscular injection. He had no trouble walking at the time of the appointment but started having problems later that day. The patient has no history of trauma or pain at the injection site. Physical examination is negative for local erythema and swelling, and the patient has full strength against resistance on knee flexion and ankle plantar flexion bilaterally. When the patient is asked to walk across the room, his left hip drops every time he raises his left foot. Which of the following locations is the most likely site of this patient's intramuscular injection?

A. Inferolateral quadrant of the buttock
B. Inferomedial quadrant of the buttock
C. Superior portion of the posterior thigh
D. Superolateral quadrant of the buttock
E. Superomedial quadrant of the buttock

Submit

10
11
12
13
14
15
16
17
18
19
20
21
22
23
24
25
26
27
28
29
30
31
32
33
34
35
36
37
38
39
40

A 43-year-old man comes to the office due to difficulty walking. The patient was seen at an outpatient clinic 2 days ago and received a right-sided deep intramuscular injection. He had no trouble walking at the time of the appointment but started having problems later that day. The patient has no history of trauma or pain at the injection site. Physical examination is negative for local erythema and swelling, and the patient has full strength against resistance on knee flexion and ankle plantar flexion bilaterally. When the patient is asked to walk across the room, his left hip drops every time he raises his left foot. Which of the following locations is the most likely site of this patient's intramuscular injection?

A. Inferolateral quadrant of the buttock (8%)

B. Inferomedial quadrant of the buttock (16%)

C. Superior portion of the posterior thigh (0%)

D. Superolateral quadrant of the buttock (23%)

✓ E. Superomedial quadrant of the buttock (51%)

Omitted
Correct answer
E

51%
Answered correctly

02 secs
Time Spent

05/21/2020
Last Updated

Explanation

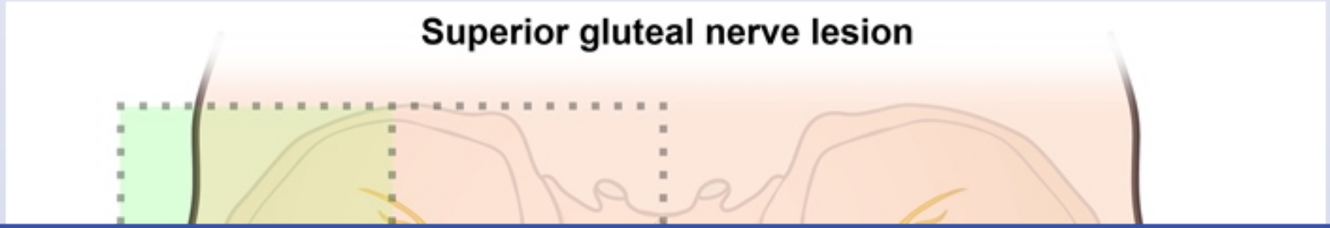

10
11
12
13
14
15
16
17
18
19
20
21
22
23
24
25
26
27
28
29
30
31
32
33
34
35
36
37
38
39
40

Superior gluteal nerve lesion

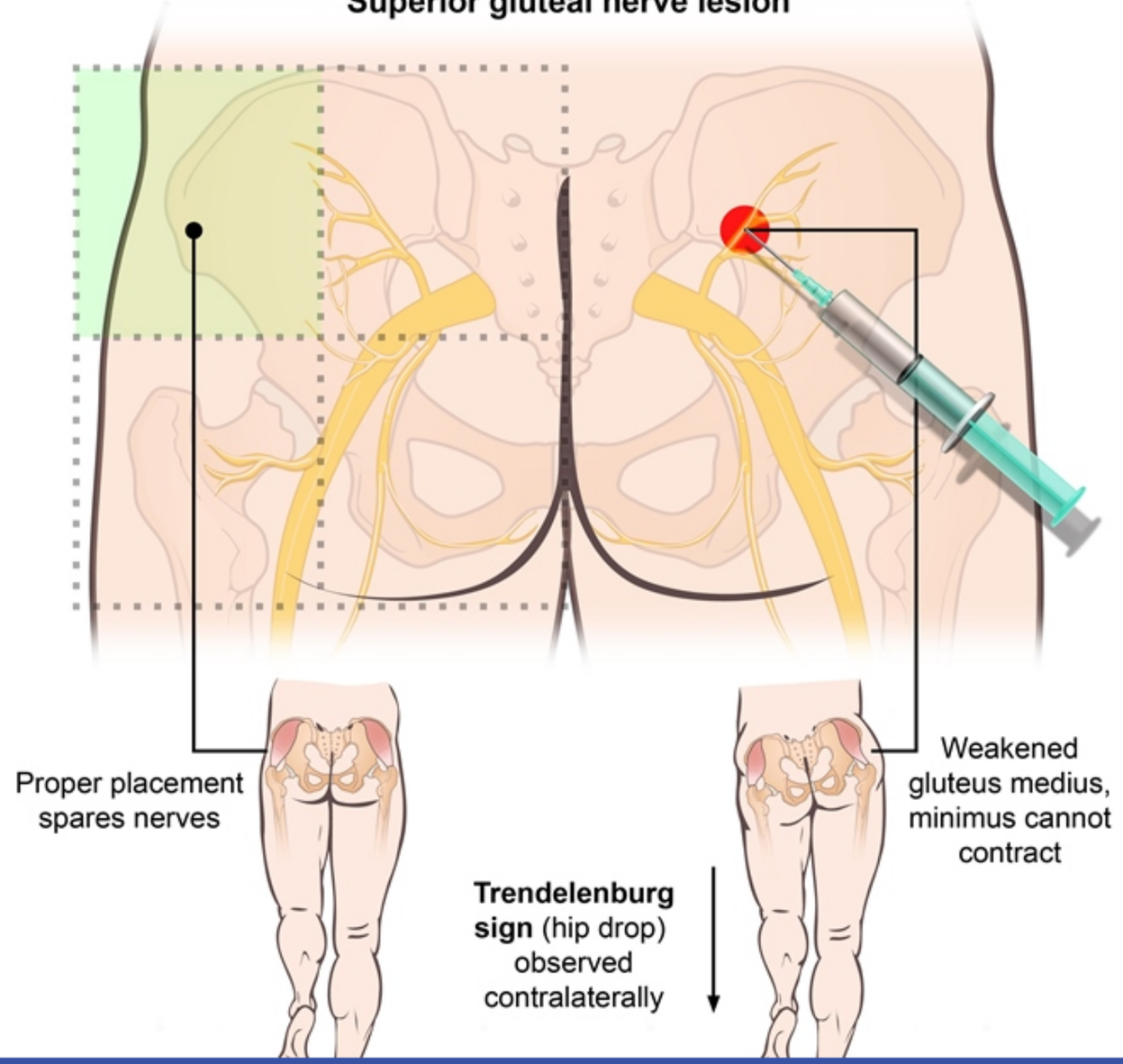

10
11
12
13
14
15
16
17
18
19
20
21
22
23
24
25
26
27
28
29
30
31
32
33
34
35
36
37
38
39
40

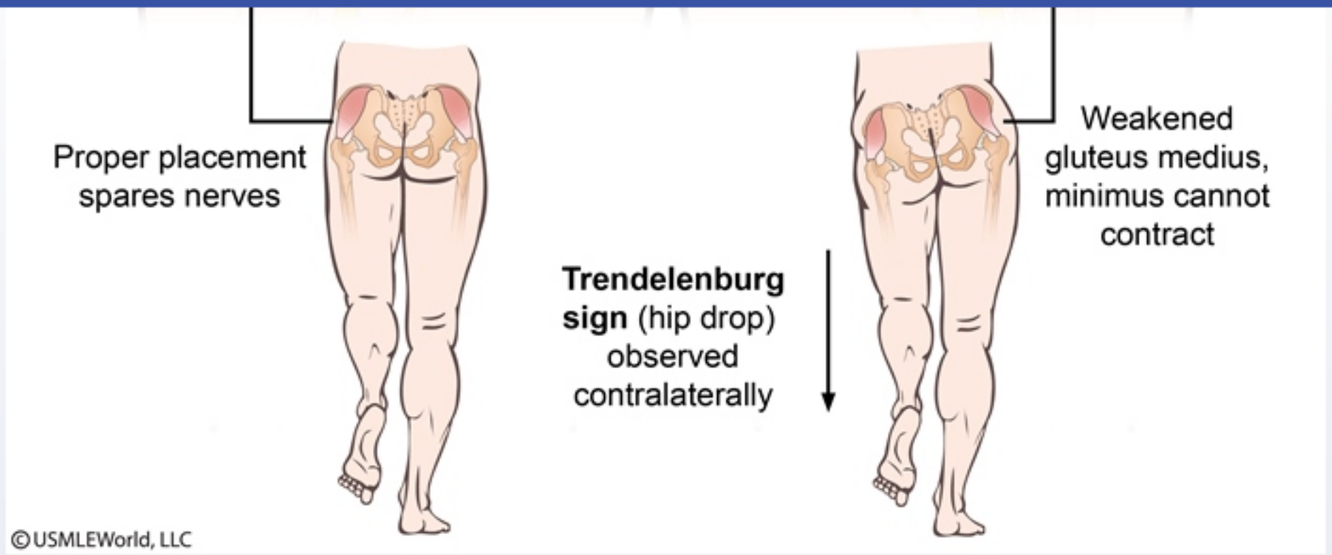

This patient is exhibiting classic **Trendelenburg gait** (ie, gluteus medius gait), which is characterized by hip drop on the contralateral, unaffected side when that foot is raised. This gait is observed when there is **injury to the superior gluteal nerve** or to the gluteus medius muscle. The superior gluteal nerve is derived from the L4-S1 ventral rami and leaves the pelvis through the greater sciatic foramen above the level of the piriformis. Injections into the **superomedial quadrant** of the buttock have a high probability of injuring the superior gluteal nerve.

(Choices A, B, and C) Due to its large size, the sciatic nerve is at risk of injury following an injection in any quadrant of the buttock or the superior portion of the posterior thigh. However, the sciatic nerve innervates the knee flexors (eg, hamstrings) and leg/foot muscles, and injury to the nerve would cause weakness in knee flexion and ankle plantarflexion (eg, foot drop) rather than Trendelenburg gait.

(Choice D) The superolateral quadrant of the buttocks is considered the safest place for dorsogluteal injections. However, damage to the gluteal and sciatic nerves can still result from injections into this region. Most intragluteal injections should target the anterolateral gluteal area (ie, von Hochstetter triangle) to minimize the possibility of nerve damage.

Educational objective:
Injections given in the superomedial quadrant of the buttock have a high risk of injuring the superior gluteal nerve, resulting in gluteus medius weakness and Trendelenburg gait. The superolateral quadrant of the buttock is a relatively safe site for intragluteal injections, although the anterolateral gluteal region is preferred.

10
11
12
13
14
15
16
17
18
19
20
21
22
23
24
25
26
27
28
29
30
31
32
33
34
35
36
37
38
39
40

This patient is exhibiting classic **Trendelenburg gait** (ie, gluteus medius gait), which is characterized by hip drop on the contralateral, unaffected side when that foot is raised. This gait is observed when there is **injury to the superior gluteal nerve** or to the gluteus medius muscle. The superior gluteal nerve is derived from the L4-S1 ventral rami and leaves the pelvis through the greater sciatic foramen above the level of the piriformis. Injections into the **superomedial quadrant** of the buttock have a high probability of injuring the superior gluteal nerve.

(Choices A, B, and C) Due to its large size, the sciatic nerve is at risk of injury following an injection in any quadrant of the buttock or the superior portion of the posterior thigh. However, the sciatic nerve innervates the knee flexors (eg, hamstrings) and leg/foot muscles, and injury to the nerve would cause weakness in knee flexion and ankle plantarflexion (eg, foot drop) rather than Trendelenburg gait.

(Choice D) The superolateral quadrant of the buttocks is considered the safest place for dorsogluteal injections. However, damage to the gluteal and sciatic nerves can still result from injections into this region. Most intragluteal injections should target the anterolateral gluteal area (ie, von Hochstetter triangle) to minimize the possibility of nerve damage.

Educational objective:
Injections given in the superomedial quadrant of the buttock have a high risk of injuring the superior gluteal nerve, resulting in gluteus medius weakness and Trendelenburg gait. The superolateral quadrant of the buttock is a relatively safe site for intragluteal injections, although the anterolateral gluteal region is preferred.

References

- Injection nerve palsy.
- Sciatic nerve injury from intramuscular injection: a persistent and global problem.

Anatomy	Rheumatology/Orthopedics & Sports	Peripheral neuropathy
Subject	System	Topic

Copyright © UWorld. All rights reserved.

10
11
12
13
14
15
16
17
18
19
20
21
22
23
24
25
26
27
28
29
30
31
32
33
34
35
36
37
38
39
40

Exhibit Display

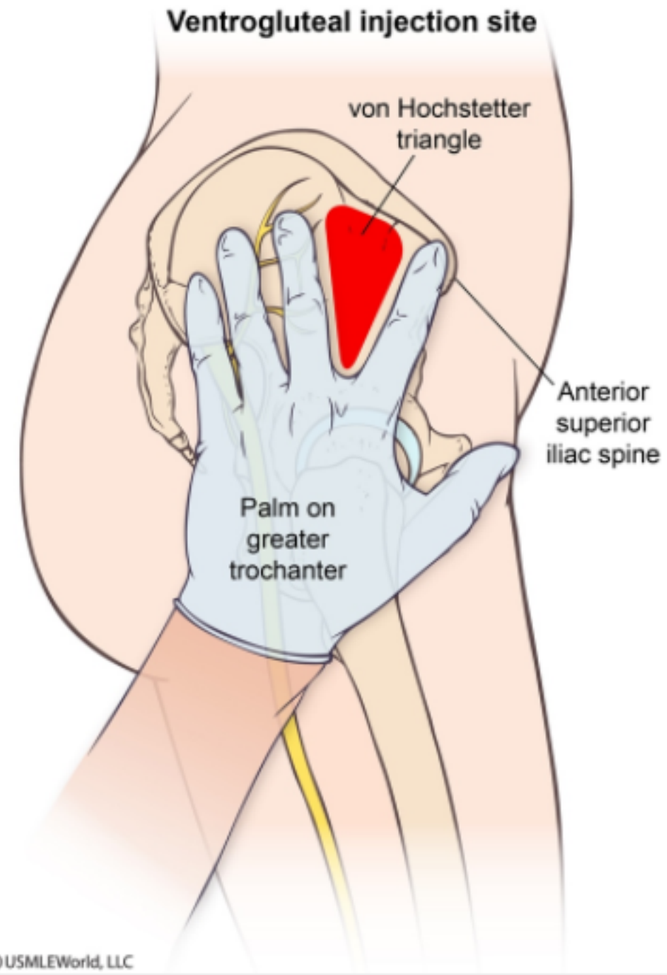

Zoom In | Zoom Out | Reset | Add To New Card | Existing Card

10
11
12
13
14
15
16
17
18
19
20
21
22
23
24
25
26
27
28
29
30
31
32
33
34
35
36
37
38
39
40

A 6-year-old girl is brought to the emergency department after falling from a chair onto her outstretched right arm. Physical examination shows swelling of the right elbow and tenderness to palpation over the distal humerus. Radial pulses are full and symmetric bilaterally. The patient is unable to cooperate with neurologic examination of the right hand due to significant pain. A peripheral intravenous line is placed, and analgesics are administered for pain control. X-rays show a supracondylar humeral fracture with anterolateral displacement of the proximal fracture fragment. Which of the following structures is most likely to be injured in this patient?

A. Basilic vein
B. Biceps tendon
C. Median nerve
D. Radial nerve
E. Ulnar nerve

Submit

A 6-year-old girl is brought to the emergency department after falling from a chair onto her outstretched right arm. Physical examination shows swelling of the right elbow and tenderness to palpation over the distal humerus. Radial pulses are full and symmetric bilaterally. The patient is unable to cooperate with neurologic examination of the right hand due to significant pain. A peripheral intravenous line is placed, and analgesics are administered for pain control. X-rays show a supracondylar humeral fracture with anterolateral displacement of the proximal fracture fragment. Which of the following structures is most likely to be injured in this patient?

- A. Basilic vein (1%)
- B. Biceps tendon (4%)
- C. Median nerve (47%)
- ✓ D. Radial nerve (36%)
- E. Ulnar nerve (10%)

Omitted
Correct answer
D

36%
Answered correctly

02 secs
Time Spent

03/03/2020
Last Updated

Explanation

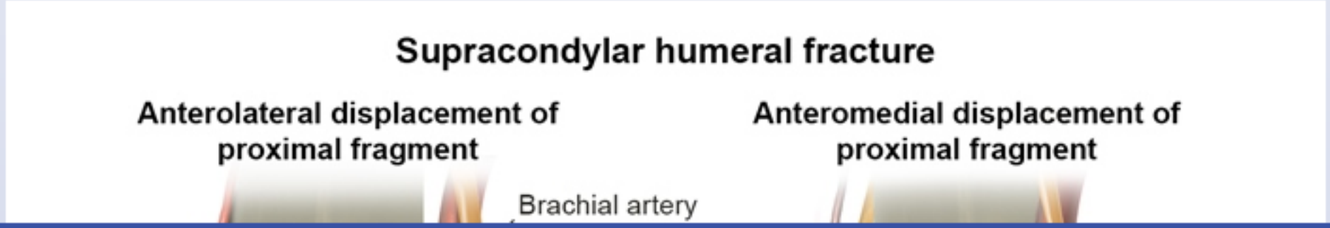

10
11
12
13
14
15
16
17
18
19
20
21
22
23
24
25
26
27
28
29
30
31
32
33
34
35
36
37
38
39
40

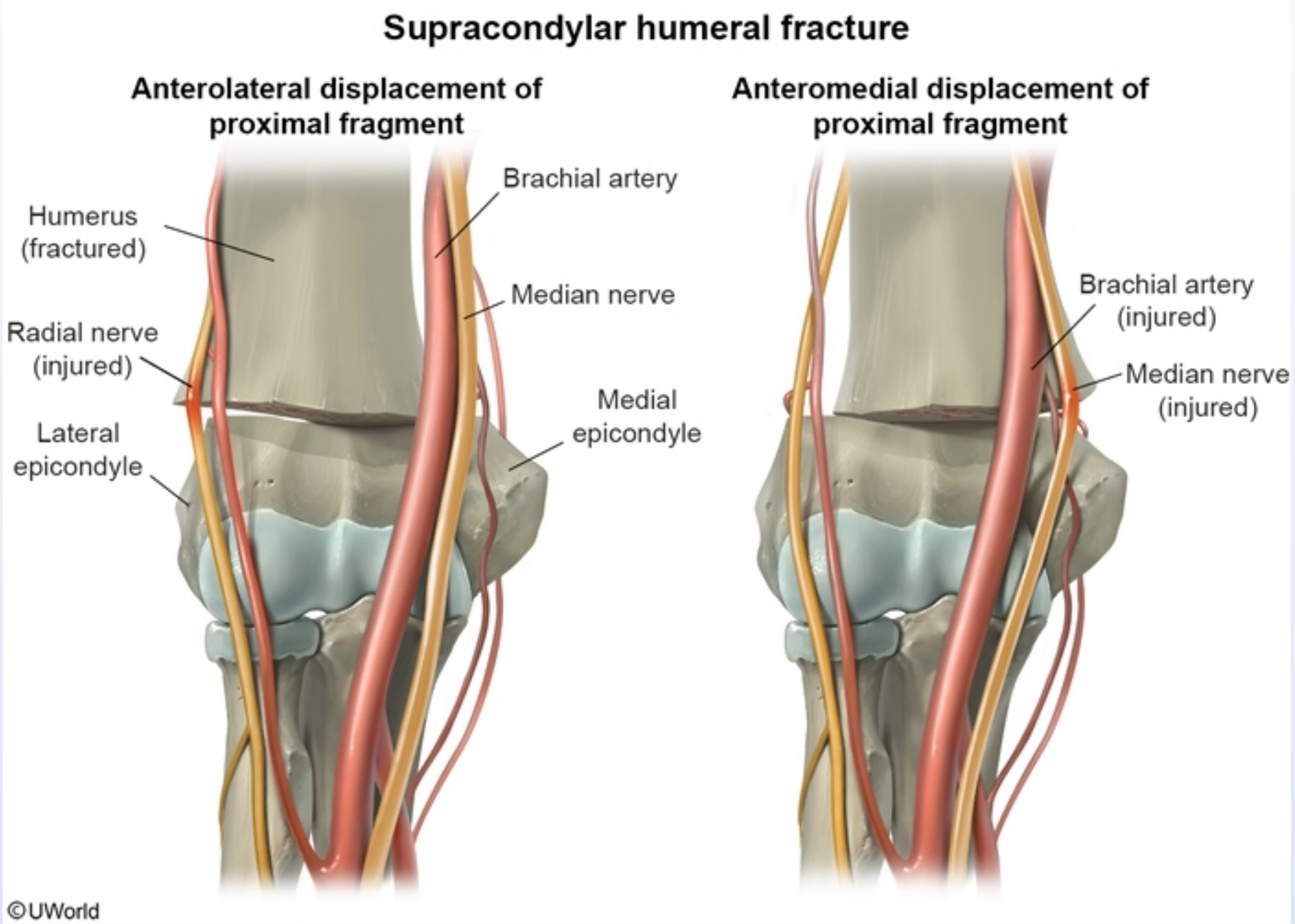

Supracondylar humeral fractures are common pediatric elbow fractures that characteristically occur after hyperextension injuries (eg, falling onto an outstretched arm). These fractures carry a significant risk of neurovascular compromise, especially if the fragments are displaced. The brachial artery, median nerve, and radial nerve all run anterior to the elbow, with the brachial artery and median nerve over the medial epicondyle and the **radial nerve** over the **lateral** epicondyle.

The median nerve and brachial artery are frequently injured in supracondylar fractures due to anteromedial displacement of the proximal fracture.

Supracondylar humeral fractures are common pediatric elbow fractures that characteristically occur after hyperextension injuries (eg, falling onto an outstretched arm). These fractures carry a significant risk of neurovascular compromise, especially if the fragments are displaced. The brachial artery, median nerve, and radial nerve all run anterior to the elbow, with the brachial artery and median nerve over the medial epicondyle and the **radial nerve** over the **lateral** epicondyle.

The median nerve and brachial artery are frequently injured in supracondylar fractures due to anteromedial displacement of the proximal fracture fragment **(Choice C)**. However, this patient has **intact radial pulses** bilaterally (ie, sparing of the brachial artery) and anterolateral displacement of the proximal fracture fragment, making **radial nerve injury** more likely. Injury to the radial nerve at the elbow can result in wrist drop due to denervation of hand/finger extensor muscles, and sensory loss over the posterior forearm/dorsolateral hand.

(Choice A) The basilic vein runs superficially over the medial aspect of the elbow and is not commonly injured during supracondylar fractures.

(Choice B) The 2 heads of the biceps muscle originate from the scapula and insert onto the radius. Biceps tendon injury/rupture typically occurs in older patients following sudden extension of a flexed elbow while contracting the biceps (eg, lifting a heavy object).

(Choice E) The ulnar nerve runs posterior to the medial epicondyle and can be injured with hyperflexion injuries (eg, falling onto a flexed elbow), resulting in posterior displacement of the proximal humerus or fracture of the medial epicondyle. Ulnar nerve injury at the elbow often presents with sensory loss over the fifth digit and half of the fourth digit, as well as weakness on flexion of the wrist and fourth/fifth digits.

Educational objective:
Supracondylar humeral fractures commonly occur after hyperextension of the elbow as a result of a fall onto an outstretched arm. The radial nerve runs along the anterolateral aspect of the elbow and is the structure most likely to be injured with anterolateral displacement of the proximal fracture fragment. The brachial artery runs with the median nerve on the anteromedial aspect of the elbow and will usually be spared in these patients (eg, intact radial pulse).

References

- Nerve injuries associated with supracondylar fractures of the humerus in children

Anatomy	Rheumatology/Orthopedics & Sports	Radial neuropathy
Subject	System	Topic

10
11
12
13
14
15
16
17
18
19
20
21
22
23
24
25
26
27
28
29
30
31
32
33
34
35
36
37
38
39
40

A 36-year-old woman is evaluated for several months of tingling and numbness of the right hand and fingers that has progressed to dull, aching pain. The symptoms initially were intermittent but have become persistent, with the pain worsening overnight. The patient works as an office secretary and has had difficulty typing and holding the phone due to hand weakness. On examination, she has weakness of thumb opposition and atrophy of the thenar eminence. The patient attempted treatment with conservative measures but had no significant improvement and has now been referred for surgery. During surgery, incision of which of the following structures is most likely to improve this patient's symptoms?

A. Fibrous flexor sheaths

B. Flexor carpi ulnaris aponeurosis

C. Palmar aponeurosis

D. Synovial sheaths of flexor tendons

E. Transverse carpal ligament

Submit

10
11
12
13
14
15
16
17
18
19
20
21
22
23
24
25
26
27
28
29
30
31
32
33
34
35
36
37
38
39
40

A 36-year-old woman is evaluated for several months of tingling and numbness of the right hand and fingers that has progressed to dull, aching pain. The symptoms initially were intermittent but have become persistent, with the pain worsening overnight. The patient works as an office secretary and has had difficulty typing and holding the phone due to hand weakness. On examination, she has weakness of thumb opposition and atrophy of the thenar eminence. The patient attempted treatment with conservative measures but had no significant improvement and has now been referred for surgery. During surgery, incision of which of the following structures is most likely to improve this patient's symptoms?

A. Fibrous flexor sheaths

B. Flexor carpi ulnaris aponeurosis

C. Palmar aponeurosis

D. Synovial sheaths of flexor tendons

E. Transverse carpal ligament

Submit

A 36-year-old woman is evaluated for several months of tingling and numbness of the right hand and fingers that has progressed to dull, aching pain. The symptoms initially were intermittent but have become persistent, with the pain worsening overnight. The patient works as an office secretary and has had difficulty typing and holding the phone due to hand weakness. On examination, she has weakness of thumb opposition and atrophy of the thenar eminence. The patient attempted treatment with conservative measures but had no significant improvement and has now been referred for surgery. During surgery, incision of which of the following structures is most likely to improve this patient's symptoms?

- A. Fibrous flexor sheaths (8%)
- B. Flexor carpi ulnaris aponeurosis (4%)
- C. Palmar aponeurosis (9%)
- D. Synovial sheaths of flexor tendons (4%)
- ✓ E. Transverse carpal ligament (71%)

Omitted
Correct answer
E

71%
Answered correctly

02 secs
Time Spent

03/22/2020
Last Updated

Explanation

10
11
12
13
14
15
16
17
18
19
20
21
22
23
24
25
26
27
28
29
30
31
32
33
34
35
36
37
38
39
40

Carpal tunnel, palmar view

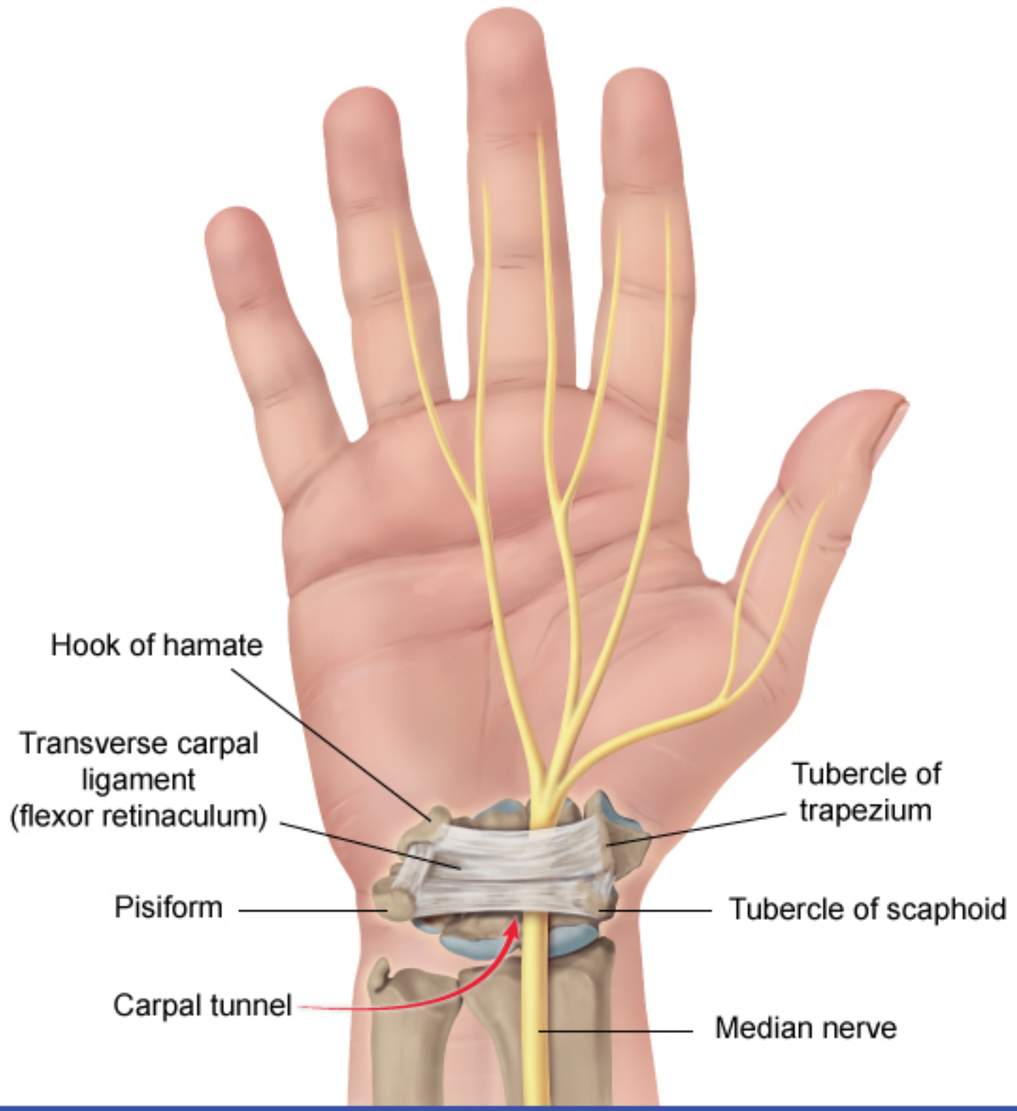

10
11
12
13
14
15
16
17
18
19
20
21
22
23
24
25
26
27
28
29
30
31
32
33
34
35
36
37
38
39
40

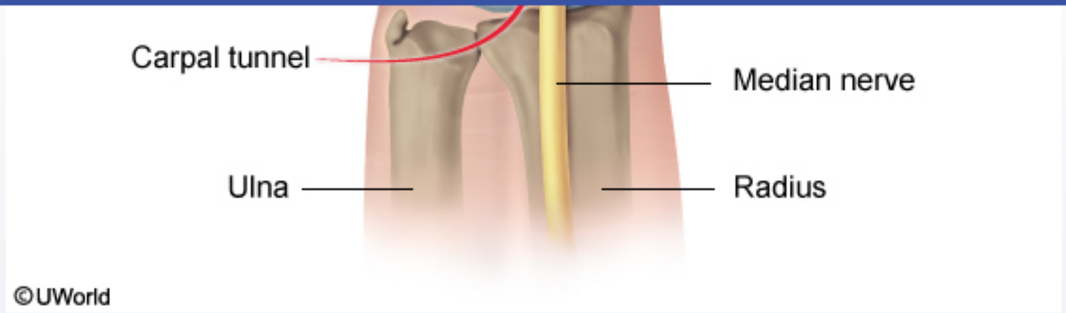

This patient has right hand pain and numbness, thenar atrophy, and weakness of thumb opposition characteristic of **carpal tunnel syndrome** (CTS). The carpal tunnel is an anatomic space in the wrist between the carpal bones and the **transverse carpal ligament** (flexor retinaculum). The **median nerve** and 9 tendons (eg, flexor digitorum superficialis and profundus, flexor pollicis longus) pass through the carpal tunnel to enter the hand. CTS occurs when **increased pressure** within the carpal tunnel (eg, compression, inflammation) causes median nerve damage.

Often, CTS can be managed successfully with nonsurgical treatments (eg, wrist splint, glucocorticoid injection). However, patients with significant impairment and evidence of median nerve injury on electromyography are often treated with **surgical decompression**. A longitudinal incision through the transverse carpal ligament decreases the pressure on the median nerve, improving patients' symptoms.

(Choices A) The fibrous flexor sheaths are thick tunnels on the palmar surface of the fingers that act like pulleys to allow the flexor digitorum profundus tendons to flex the fingers at the interphalangeal joints. Swelling of the tendon and/or fibrous sheath can result in painful catching or locking of the affected finger during flexion (ie, trigger finger).

(Choice B) The flexor carpi ulnaris aponeurosis spans from the olecranon to the medial epicondyle and forms the roof of the cubital tunnel. The ulnar nerve runs through this space, and compression here can cause sensory loss over the ulnar aspect of the hand.

(Choice C) The palmar aponeurosis (palmar fascia) spans from the flexor retinaculum at the wrist and is continuous with the fibrous flexor sheaths of the digits. Fibrosis of the palmar aponeurosis can result in Dupuytren contracture, which is a progressive disorder characterized by nodular lesions in the palm with restricted finger motion.

(Choice D) The synovial sheaths of the flexor digitorum superficialis and profundus tendons pass through the carpal tunnel around the flexor tendons. However, incision of synovial sheaths would not relieve the pressure on the median nerve in CTS.

Educational objective:

Often, CTS can be managed successfully with nonsurgical treatments (eg, wrist splint, glucocorticoid injection). However, patients with significant impairment and evidence of median nerve injury on electromyography are often treated with **surgical decompression**. A longitudinal incision through the transverse carpal ligament decreases the pressure on the median nerve, improving patients' symptoms.

(Choices A) The fibrous flexor sheaths are thick tunnels on the palmar surface of the fingers that act like pulleys to allow the flexor digitorum profundus tendons to flex the fingers at the interphalangeal joints. Swelling of the tendon and/or fibrous sheath can result in painful catching or locking of the affected finger during flexion (ie, trigger finger).

(Choice B) The flexor carpi ulnaris aponeurosis spans from the olecranon to the medial epicondyle and forms the roof of the cubital tunnel. The ulnar nerve runs through this space, and compression here can cause sensory loss over the ulnar aspect of the hand.

(Choice C) The palmar aponeurosis (palmar fascia) spans from the flexor retinaculum at the wrist and is continuous with the fibrous flexor sheaths of the digits. Fibrosis of the palmar aponeurosis can result in Dupuytren contracture, which is a progressive disorder characterized by nodular lesions in the palm with restricted finger motion.

(Choice D) The synovial sheaths of the flexor digitorum superficialis and profundus tendons pass through the carpal tunnel around the flexor tendons. However, incision of synovial sheaths would not relieve the pressure on the median nerve in CTS.

Educational objective:
The carpal tunnel is formed by the carpal bones and the transverse carpal ligament (flexor retinaculum). Carpal tunnel syndrome results from compression of the median nerve as it passes through the carpal tunnel with 9 flexor tendons. Longitudinal incision of the transverse carpal ligament can decrease pressure within the carpal tunnel, improving patients' symptoms.

References

- Carpal tunnel syndrome - anatomical and clinical correlations.

Anatomy	Rheumatology/Orthopedics & Sports	Carpal tunnel syndrome
Subject	System	Topic

Copyright © UWorld. All rights reserved.

10
11
12
13
14
15
16
17
18
19
20
21
22
23
24
25
26
27
28
29
30
31
32
33
34
35
36
37
38
39
40

Exhibit Display

Transverse cross section of wrist & carpal tunnel

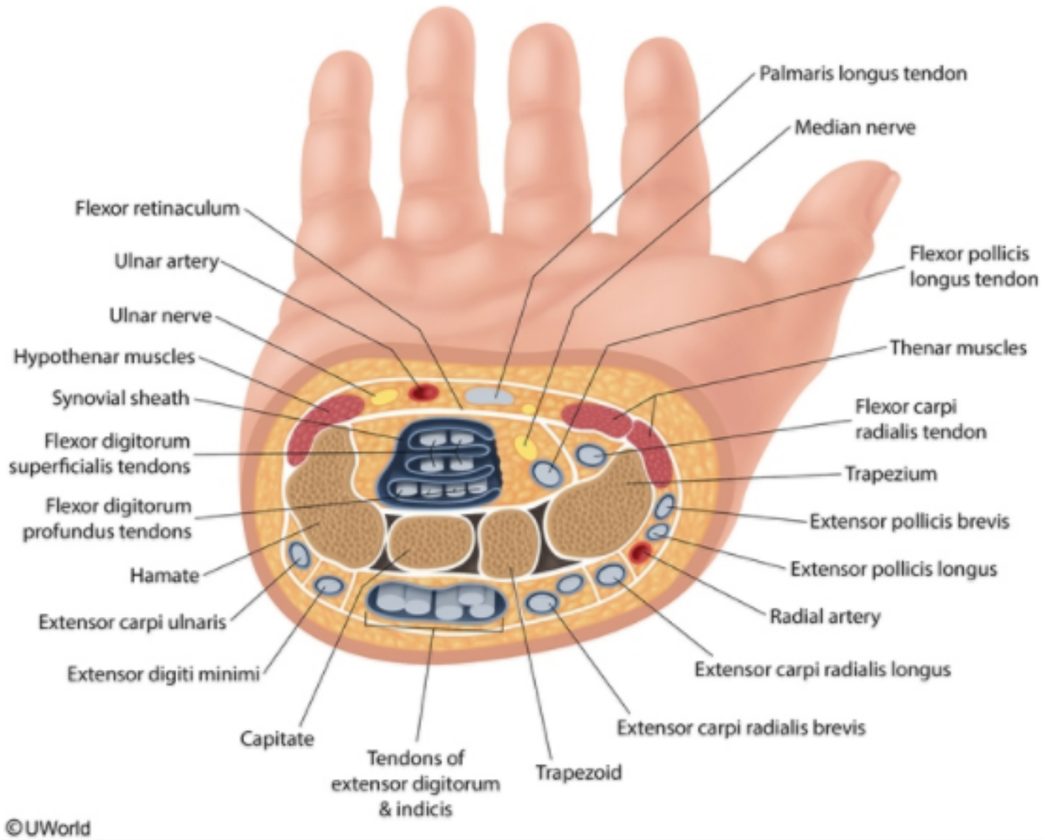

Zoom In | Zoom Out | Reset | Add To New Card | Existing Card

This patient has right hand
(CTS). The carpal tunnel
The **median nerve** and 9
the hand. CTS occurs wh

Often, CTS can be manag
impairment and evidence
through the transverse ca

(Choices A) The fibrous
profundus tendons to flex
locking of the affected fing

(Choice B) The flexor ca
ulnar nerve runs through t

(Choice C) The palmar a
sheaths of the digits. Fibr
nodular lesions in the palm

(Choice D) The synovial sheaths of the flexor digitorum superficialis and profundus tendons pass through the carpal tunnel around the flexor tendons. However, incision of synovial sheaths would not relieve the pressure on the median nerve in CTS.

10
11
12
13
14
15
16
17
18
19
20
21
22
23
24
25
26
27
28
29
30
31
32
33
34
35
36
37
38
39
40

Exhibit Display

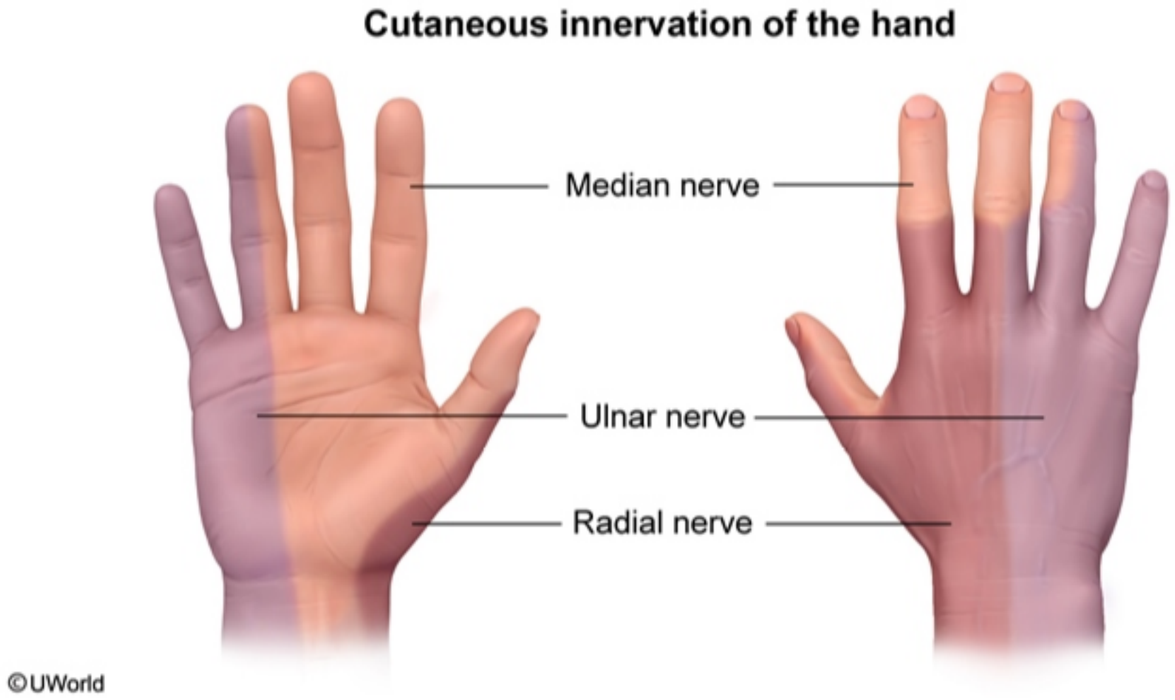

Zoom In | Zoom Out | Reset | Add To New Card | Existing Card

tendons. However, incision of synovial sheaths would not relieve the pressure on the median nerve in CTS.

A 16-year-old girl comes to the office due to several months of left elbow pain. The pain is worse with activity and limits her exercise. She has attempted treatment with over-the-counter ibuprofen and acetaminophen but has had only partial relief. Medical history is notable for seasonal allergies, and current medications include a fluticasone nasal spray. Further evaluation shows that the patient's condition is due to a tendon injury. A long-acting glucocorticoid injection is administered at the most tender spot, as marked in the image below.

Which of the following actions is most likely performed by the affected muscle?

- A. Finger adduction
- B. Forearm flexion
- C. Shoulder abduction

10
11
12
13
14
15
16
17
18
19
20
21
22
23
24
25
26
27
28
29
30
31
32
33
34
35
36
37
38
39
40

Which of the following actions is most likely performed by the affected muscle?

A. Finger adduction
B. Forearm flexion
C. Shoulder abduction
D. Thumb abduction
E. Wrist extension
F. Wrist flexion

Submit

10
11
12
13
14
15
16
17
18
19
20
21
22
23
24
25
26
27
28
29
30
31
32
33
34
35
36
37
38
39
40

Which of the following actions is most likely performed by the affected muscle?

A. Finger adduction (3%)

B. Forearm flexion (19%)

C. Shoulder abduction (1%)

D. Thumb abduction (3%)

✓ E. Wrist extension (64%)

F. Wrist flexion (7%)

Omitted
Correct answer

64%
Answered correctly

05 secs
Time Spent

01/19/2020
Last Updated

10
11
12
13
14
15
16
17
18
19
20
21
22
23
24
25
26
27
28
29
30
31
32
33
34
35
36
37
38
39
40

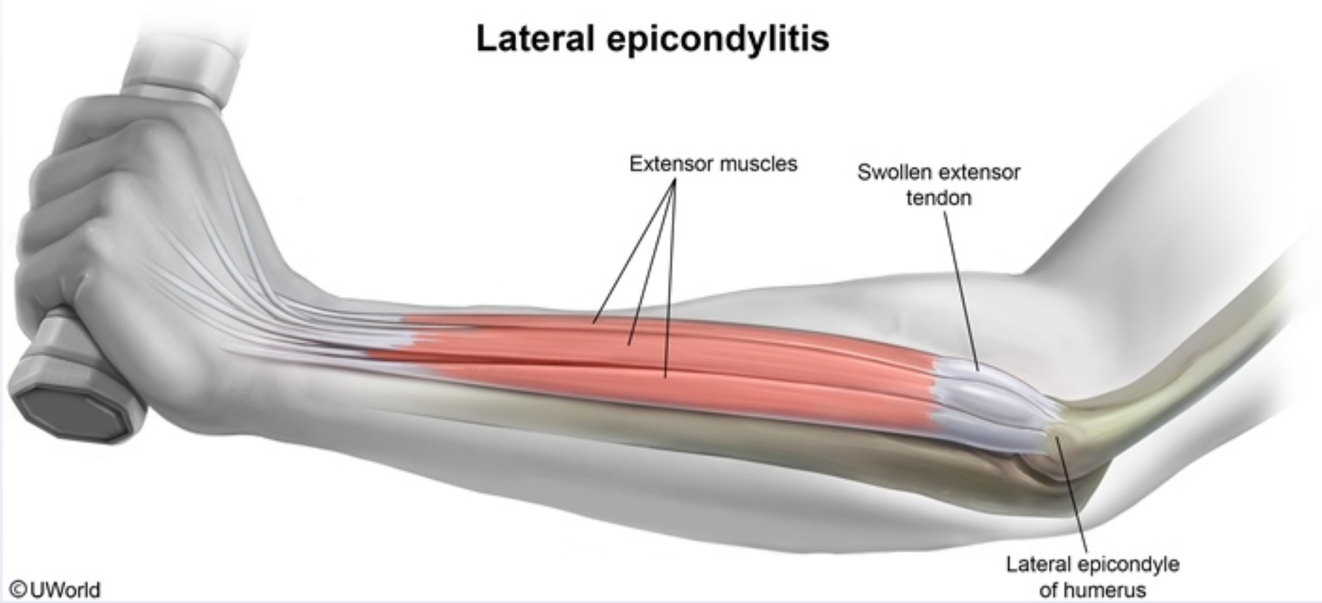

This patient has pain over the lateral epicondyle of the humerus, suggesting **lateral epicondylitis** (ie, tennis elbow). Lateral epicondylitis is classically seen in tennis players due to repetitive **wrist extension** (backhand strikes) transmitting sudden, extreme forces through the lateral epicondyle.

The lateral epicondyle serves as the primary attachment point for **extensor carpi radialis brevis** and **extensor digitorum**, which are the primary muscles involved in wrist extension. Overuse of these muscles can cause repetitive microtrauma of the tendons at their origins on the **lateral epicondyle**, leading to angiofibroblastic **tendinosis** (ie, excess fibroblasts and neovascularization) without a significant inflammatory infiltrate. This results in swelling and pain over the lateral epicondyle and proximal extensor tendons.

Overuse of the wrist flexor muscles can cause medial epicondylitis (ie, golfer's elbow), which occurs by a similar process in the tendons of the flexor muscles near their attachment on the medial epicondyle **(Choice F)**.

(Choice A) Adduction of the fingers is primarily accomplished by the palmar interosseous muscles, which originate on the metacarpals.

(Choice B) Flexion of the forearm is primarily accomplished by the biceps brachii, brachialis, and brachioradialis muscles. None of these

This patient has pain over the lateral epicondyle of the humerus, suggesting **lateral epicondylitis** (ie, tennis elbow). Lateral epicondylitis is classically seen in tennis players due to repetitive **wrist extension** (backhand strikes) transmitting sudden, extreme forces through the lateral epicondyle.

The lateral epicondyle serves as the primary attachment point for **extensor carpi radialis brevis** and **extensor digitorum**, which are the primary muscles involved in wrist extension. Overuse of these muscles can cause repetitive microtrauma of the tendons at their origins on the **lateral epicondyle**, leading to angiofibroblastic **tendinosis** (ie, excess fibroblasts and neovascularization) without a significant inflammatory infiltrate. This results in swelling and pain over the lateral epicondyle and proximal extensor tendons.

Overuse of the wrist flexor muscles can cause medial epicondylitis (ie, golfer's elbow), which occurs by a similar process in the tendons of the flexor muscles near their attachment on the medial epicondyle **(Choice F)**.

(Choice A) Adduction of the fingers is primarily accomplished by the palmar interosseous muscles, which originate on the metacarpals.

(Choice B) Flexion of the forearm is primarily accomplished by the biceps brachii, brachialis, and brachioradialis muscles. None of these muscles originate on the lateral epicondyle.

(Choice C) Shoulder abduction is primarily accomplished by the supraspinatus and deltoid muscles. Overuse of the supraspinatus leads to supraspinatus tendinopathy (ie, rotator cuff tendinopathy).

(Choice D) Overuse of the abductor pollicis longus (thumb abduction) and extensor pollicis brevis (thumb extension) can result in de Quervain tendinopathy, which causes thumb and wrist pain.

Educational objective:
Lateral epicondylitis (ie, tennis elbow) is characterized by overuse of wrist extensor muscles (eg, extensor carpi radialis, extensor digitorum), leading to angiofibroblastic tendinosis at their attachment on the lateral epicondyle.

References

- Lateral epicondylitis of the elbow.

Anatomy	Rheumatology/Orthopedics & Sports	Lateral epicondylitis
Subject	System	Topic

10
11
12
13
14
15
16
17
18
19
20
21
22
23
24
25
26
27
28
29
30
31
32
33
34
35
36
37
38
39
40

A 72-year-old man comes to the primary care clinic with a 6-month history of back and bilateral thigh pain provoked by walking. He normally can walk only 2-3 blocks before having to stop due to pain. However, when he is out walking with his grandchild, leaning on the stroller seems to provide pain relief. The patient also notices an occasional tingling sensation in his lower extremities. He has no prior trauma or history of rheumatologic disorders. On physical examination, muscular strength is normal and the sensory findings are unremarkable. Peripheral pulses are full and symmetric. Thickening of which of the following ligaments is most likely contributing to this patient's current presentation?

A. Anterior longitudinal
B. Iliolumbar
C. Interspinous
D. Ligamentum flavum
E. Sacroiliac

Submit

A 72-year-old man comes to the primary care clinic with a 6-month history of back and bilateral thigh pain provoked by walking. He normally can walk only 2-3 blocks before having to stop due to pain. However, when he is out walking with his grandchild, leaning on the stroller seems to provide pain relief. The patient also notices an occasional tingling sensation in his lower extremities. He has no prior trauma or history of rheumatologic disorders. On physical examination, muscular strength is normal and the sensory findings are unremarkable. Peripheral pulses are full and symmetric. Thickening of which of the following ligaments is most likely contributing to this patient's current presentation?

- A. Anterior longitudinal (10%)
- B. Iliolumbar (15%)
- C. Interspinous (11%)
- ✓ D. Ligamentum flavum (31%)
- E. Sacroiliac (30%)

Omitted
Correct answer
D

31%
Answered correctly

01 sec
Time Spent

03/10/2020
Last Updated

Explanation

10
11
12
13
14
15
16
17
18
19
20
21
22
23
24
25
26
27
28
29
30
31
32
33
34
35
36
37
38
39
40

Explanation

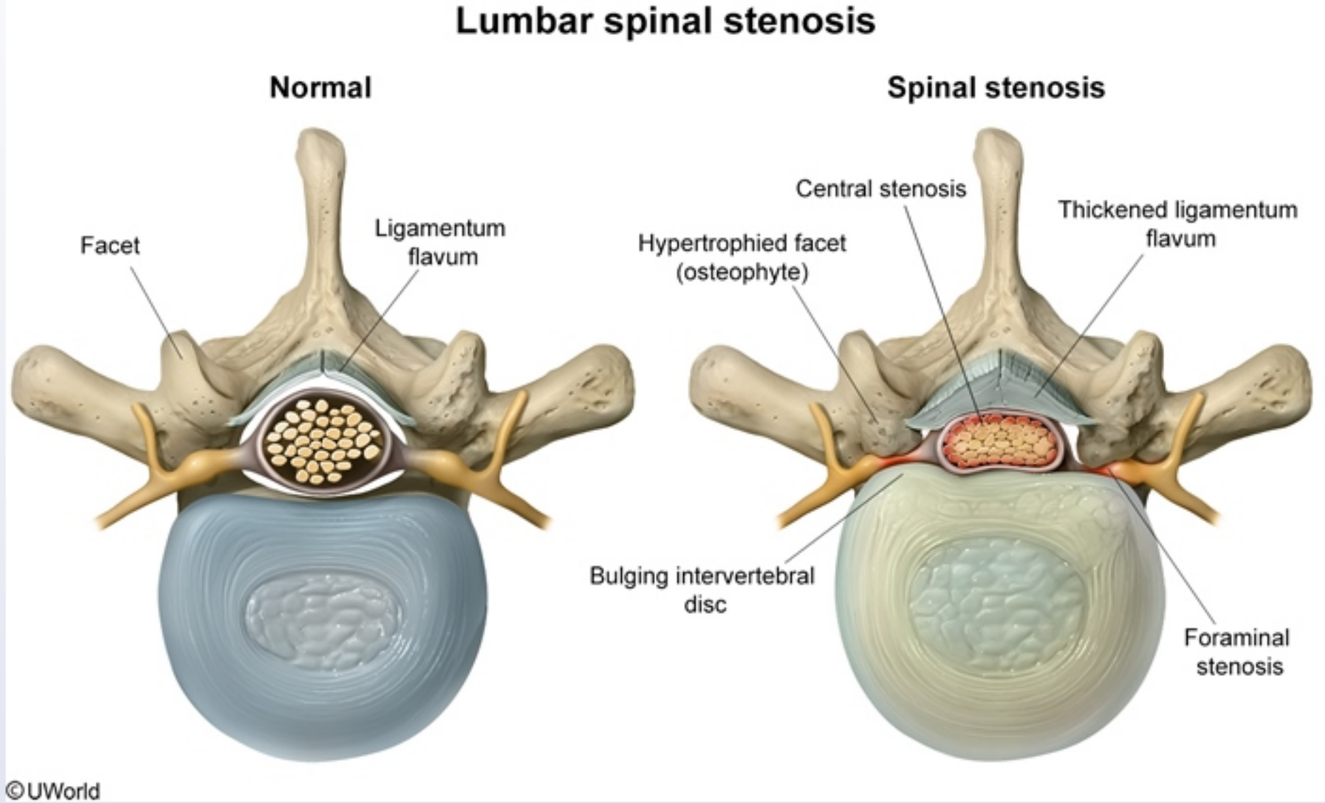

This patient presents with **spinal stenosis**, an abnormal narrowing of the spinal canal occurring most commonly in the lumbar region. Compression of nerve roots results in a number of neurologic symptoms, including **lower extremity pain**, **numbness/paresthesia**, and **weakness**. The onset of pain with walking is referred to as "neurogenic claudication" as it may resemble symptoms seen in vascular claudication. However, the symptoms of spinal stenosis are **posture-dependent**. Extension of the lumbar spine (eg, standing, walking upright) further narrows the spinal canal and worsens the symptoms, whereas lumbar flexion (eg, walking uphill, leaning on a stroller/shopping cart) relieves the pain.

Degenerative arthritis of the spine is the most common cause of spinal stenosis, typically occurring in patients age >60. Over time, the intervertebral disc degenerates and begins to protrude, resulting in a corresponding loss in disc height. This loss of height places a

©UWorld

This patient presents with **spinal stenosis**, an abnormal narrowing of the spinal canal occurring most commonly in the lumbar region. Compression of nerve roots results in a number of neurologic symptoms, including **lower extremity pain**, **numbness/paresthesia**, and **weakness**. The onset of pain with walking is referred to as "neurogenic claudication" as it may resemble symptoms seen in vascular claudication. However, the symptoms of spinal stenosis are **posture-dependent**. Extension of the lumbar spine (eg, standing, walking upright) further narrows the spinal canal and worsens the symptoms, whereas lumbar flexion (eg, walking uphill, leaning on a stroller/shopping cart) relieves the pain.

Degenerative arthritis of the spine is the most common cause of spinal stenosis, typically occurring in patients age >60. Over time, the intervertebral disc degenerates and begins to protrude, resulting in a corresponding loss in disc height. This loss of height places a disproportionate load on the posterior aspect of the spinal column, leading to formation of facet joint osteophytes and hypertrophy of the ligamentum flavum (a strong elastic ligament supporting the posterior aspect of the spinal canal). These physiologic changes lead to mechanical compression of nerve roots and corresponding neurologic symptoms.

(Choice A) The anterior longitudinal ligament covers the anterior aspect of the vertebral bodies, preventing excess spinal extension.

(Choice B) The iliolumbar ligament connects the fifth lumbar vertebrae to the iliac crest, strengthening the lumbosacral joint.

(Choice C) The interspinous ligaments connect the spinous processes and help limit flexion of the spine.

(Choice E) The sacroiliac ligament prevents distraction of the sacroiliac joint.

Educational objective:
Spinal stenosis occurs most commonly in the lumbar region and presents with posture-dependent lower extremity pain, numbness/paresthesia, and weakness. The most common cause is degenerative arthritis of the spine, which results in narrowing of the spinal canal due to intervertebral disc herniation, ligamentum flavum hypertrophy, and osteophyte formation affecting the facet joints.

References

- Management of lumbar spinal stenosis.

Anatomy	Rheumatology/Orthopedics & Sports	Spinal stenosis
Subject	System	Topic

Compression of nerve roots results in a number of neurologic symptoms, including **lower extremity pain**, **numbness/paresthesia**, and **weakness**. The onset of pain with walking is referred to as "neurogenic claudication" as it may resemble symptoms seen in vascular claudication. However, the symptoms of spinal stenosis are **posture-dependent**. Extension of the lumbar spine (eg, standing, walking upright) further narrows the spinal canal and worsens the symptoms, whereas lumbar flexion (eg, walking uphill, leaning on a stroller/shopping cart) relieves the pain.

Degenerative arthritis of the spine is the most common cause of spinal stenosis, typically occurring in patients age >60. Over time, the intervertebral disc degenerates and begins to protrude, resulting in a corresponding loss in disc height. This loss of height places a disproportionate load on the posterior aspect of the spinal column, leading to formation of facet joint osteophytes and hypertrophy of the ligamentum flavum (a strong elastic ligament supporting the posterior aspect of the spinal canal). These physiologic changes lead to mechanical compression of nerve roots and corresponding neurologic symptoms.

(Choice A) The anterior longitudinal ligament covers the anterior aspect of the vertebral bodies, preventing excess spinal extension.

(Choice B) The iliolumbar ligament connects the fifth lumbar vertebrae to the iliac crest, strengthening the lumbosacral joint.

(Choice C) The interspinous ligaments connect the spinous processes and help limit flexion of the spine.

(Choice E) The sacroiliac ligament prevents distraction of the sacroiliac joint.

Educational objective:
Spinal stenosis occurs most commonly in the lumbar region and presents with posture-dependent lower extremity pain, numbness/paresthesia, and weakness. The most common cause is degenerative arthritis of the spine, which results in narrowing of the spinal canal due to intervertebral disc herniation, ligamentum flavum hypertrophy, and osteophyte formation affecting the facet joints.

References

- Management of lumbar spinal stenosis.

Anatomy	Rheumatology/Orthopedics & Sports	Spinal stenosis
Subject	System	Topic

Copyright © UWorld. All rights reserved.

10
11
12
13
14
15
16
17
18
19
20
21
22
23
24
25
26
27
28
29
30
31
32
33
34
35
36
37
38
39
40

Foraminal stenosis

Exhibit Display

Shopping cart sign

Zoom In | Zoom Out | Reset | Add To New Card | Existing Card

- Management of lumbar spinal stenosis.

10
11
12
13
14
15
16
17
18
19
20
21
22
23
24
25
26
27
28
29
30
31
32
33
34
35
36
37
38
39
40

Foraminal stenosis

Exhibit Display

Vertebral ligaments

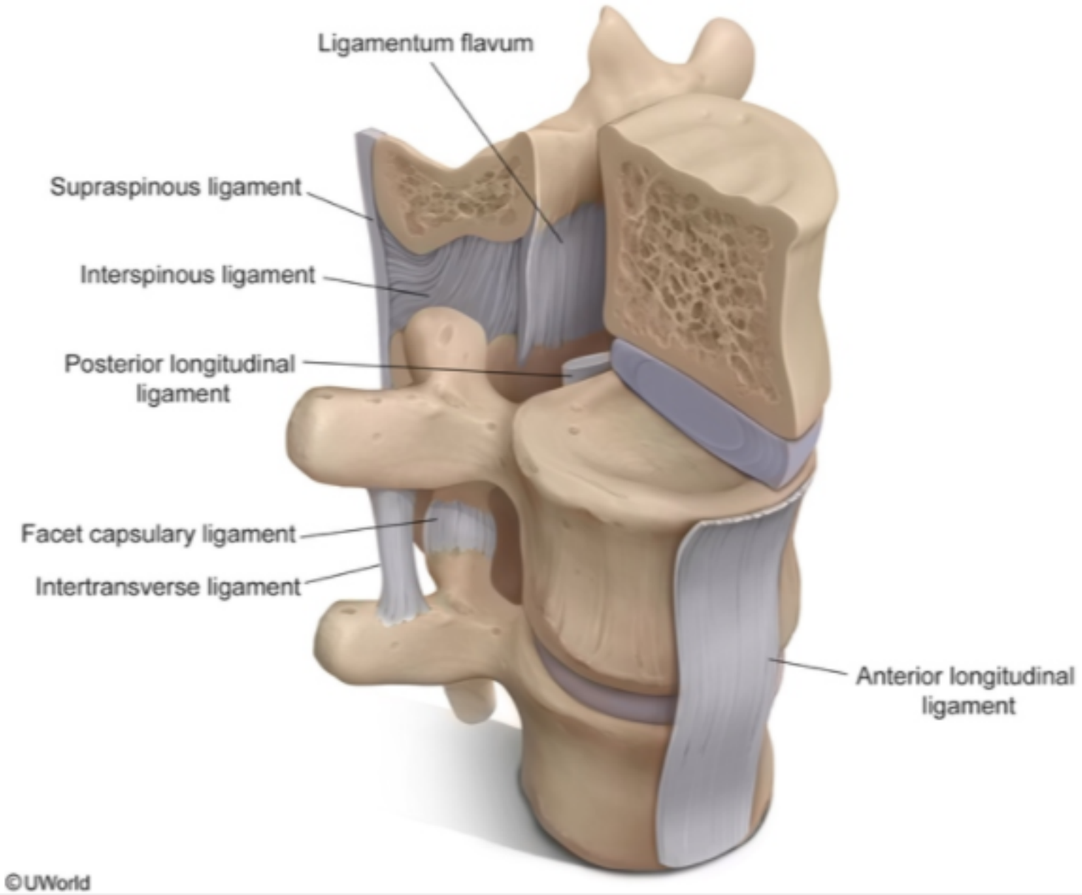

Zoom In | Zoom Out | Reset | Add To New Card | Existing Card

Management of lumbar spinal stenosis.

Compression of nerve roots results in a number of neurologic symptoms, including **lower extremity pain**, **numbness/paresthesia**, and **weakness**. The onset of pain with walking is referred to as "neurogenic claudication" as it may resemble symptoms seen in vascular claudication. However, the symptoms of spinal stenosis are **posture-dependent**. Extension of the lumbar spine (eg, standing, walking upright) further narrows the spinal canal and worsens the symptoms, whereas lumbar flexion (eg, walking uphill, leaning on a stroller/shopping cart) relieves the pain.

Degenerative arthritis of the spine is the most common cause of spinal stenosis, typically occurring in patients age >60. Over time, the intervertebral disc degenerates and begins to protrude, resulting in a corresponding loss in disc height. This loss of height places a disproportionate load on the posterior aspect of the spinal column, leading to formation of facet joint osteophytes and hypertrophy of the ligamentum flavum (a strong elastic ligament supporting the posterior aspect of the spinal canal). These physiologic changes lead to mechanical compression of nerve roots and corresponding neurologic symptoms.

(Choice A) The anterior longitudinal ligament covers the anterior aspect of the vertebral bodies, preventing excess spinal extension.

(Choice B) The iliolumbar ligament connects the fifth lumbar vertebrae to the iliac crest, strengthening the lumbosacral joint.

(Choice C) The interspinous ligaments connect the spinous processes and help limit flexion of the spine.

(Choice E) The sacroiliac ligament prevents distraction of the sacroiliac joint.

Educational objective:
Spinal stenosis occurs most commonly in the lumbar region and presents with posture-dependent lower extremity pain, numbness/paresthesia, and weakness. The most common cause is degenerative arthritis of the spine, which results in narrowing of the spinal canal due to intervertebral disc herniation, ligamentum flavum hypertrophy, and osteophyte formation affecting the facet joints.

References

- Management of lumbar spinal stenosis.

Anatomy	Rheumatology/Orthopedics & Sports	Spinal stenosis
Subject	System	Topic

Copyright © UWorld. All rights reserved.

10
11
12
13
14
15
16
17
18
19
20
21
22
23
24
25
26
27
28
29
30
31
32
33
34
35
36
37
38
39
40

A 73-year-old woman is brought to the emergency department due to right hip pain. The patient was getting out of the shower when she slipped and fell directly on her right hip. She now has pain and swelling over the lateral aspect of her hip and cannot walk without assistance. Vital signs are within normal limits. Bilateral pedal pulses are normal, and sensation is intact. X-ray of the right hip is shown below.

10
11
12
13
14
15
16
17
18
19
20
21
22
23
24
25
26
27
28
29
30
31
32
33
34
35
36
37
38
39
40

10
11
12
13
14
15
16
17
18
19
20
21
22
23
24
25
26
27
28
29
30
31
32
33
34
35
36
37
38
39
40

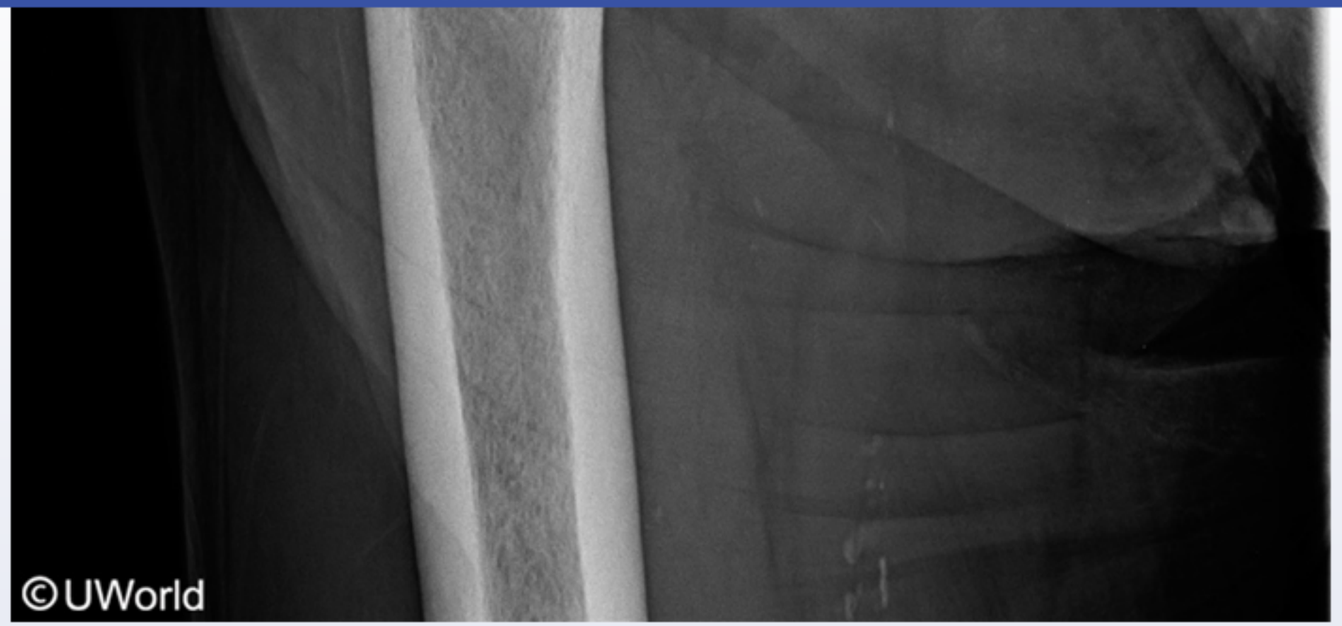

Examination of this patient will most likely show impaired function of which of the following muscles?

A. Adductor magnus

B. Gluteus medius

C. Iliopsoas

D. Rectus femoris

E. Sartorius

Submit

10
11
12
13
14
15
16
17
18
19
20
21
22
23
24
25
26
27
28
29
30
31
32
33
34
35
36
37
38
39
40

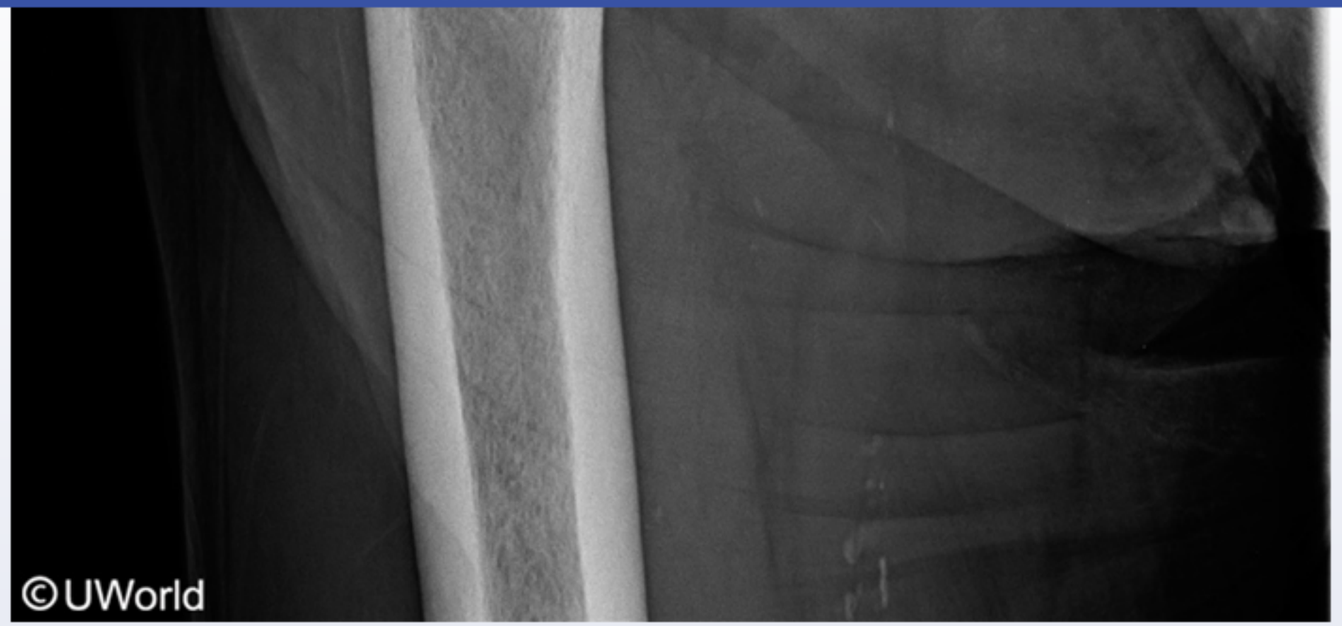

Examination of this patient will most likely show impaired function of which of the following muscles?

- A. Adductor magnus (8%)
- ✓ B. Gluteus medius (44%)
- C. Iliopsoas (21%)
- D. Rectus femoris (9%)
- E. Sartorius (16%)

Omitted
Correct answer

44%
Answered correctly

11 secs
Time Spent

02/23/2020
Last Updated

10
11
12
13
14
15
16
17
18
19
20
21
22
23
24
25
26
27
28
29
30
31
32
33
34
35
36
37
38
39
40

Gluteus medius

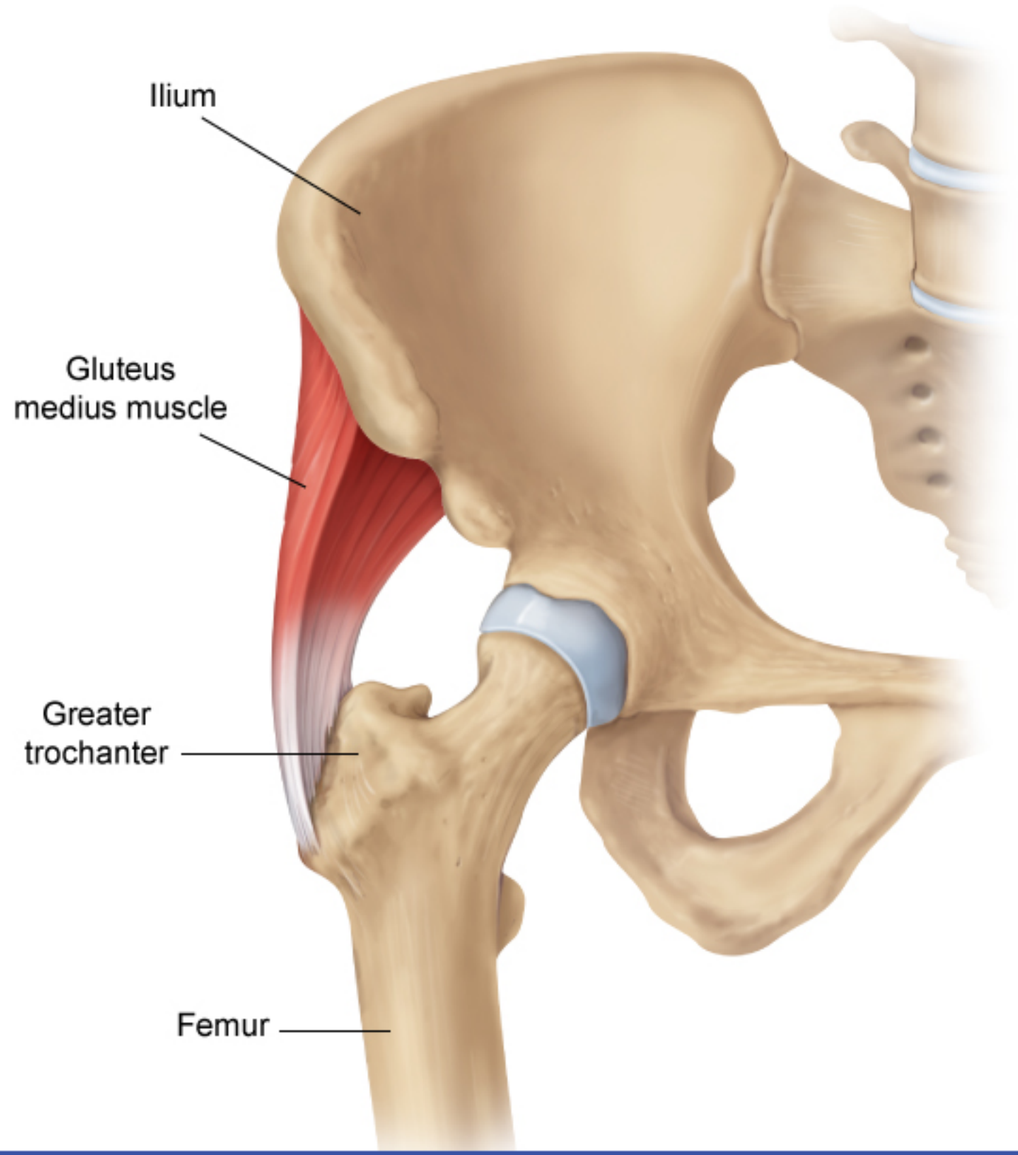

The pelvic bones and femoral trochanters provide sites of attachment for the large postural and ambulatory muscles of the hip girdle. Fractures involving these attachment sites are commonly caused by **high-velocity trauma** (eg, motor vehicle collisions, falls from height), but may occur even with ground-level falls (eg, getting out of the shower) in patients with **skeletal fragility** (eg, postmenopausal osteoporosis).

This patient's x-ray shows **avulsion** of the tip of the **greater trochanter of the femur**. The greater trochanter serves as the site of insertion for the **gluteus medius** muscle, which originates from the ilium. The main actions of the gluteus medius are **hip abduction** and stabilization of the pelvis during ambulation. Damage to the point of insertion on the greater trochanter can result in lateral hip pain with gait instability (ie, positive Trendelenburg sign) and weakness of abduction.

(Choice A) The ischiocondylar portion of the adductor magnus originates from the ischial tuberosity and inserts onto the medial condyle of the distal femur. Major functions include hip adduction and extension.

(Choice C) The iliopsoas is the union of iliacus and psoas major and inserts onto the lesser trochanter of the femur. It is the primary flexor of the hip.

(Choice D) The rectus femoris originates from the anterior inferior iliac spine, joins the other portions of the quadriceps femoris (ie, vastus lateralis, vastus medialis, and vastus intermedius) in a common quadriceps tendon, and attaches to the lower leg via the patella and patellar tendon. Because of its origin on the ilium, the rectus femoris contributes to hip flexion in addition to knee extension.

(Choice E) The sartorius originates from the anterior superior iliac spine and crosses the anterior thigh to insert with the pes anserinus (common tendon for the sartorius, gracilis, and semitendinosous muscles) onto the superomedial surface of the tibia. It aids in hip flexion, abduction, and external rotation.

Educational objective:
The greater trochanter of the femur serves as the site of insertion for the gluteus medius muscle, which is responsible for hip abduction and stabilization of the pelvis during ambulation. Fractures of the greater trochanter (eg, fragility fracture from a fall) can disrupt the integrity of the gluteus medius tendon and result in lateral hip pain with gait instability and weakness of hip abduction.

References

- Does isolated greater trochanter implication affect hip abducent strength and functions in intertrochanteric fracture?

10
11
12
13
14
15
16
17
18
19
20
21
22
23
24
25
26
27
28
29
30
31
32
33
34
35
36
37
38
39
40

Exhibit Display

The iliopsoas muscle

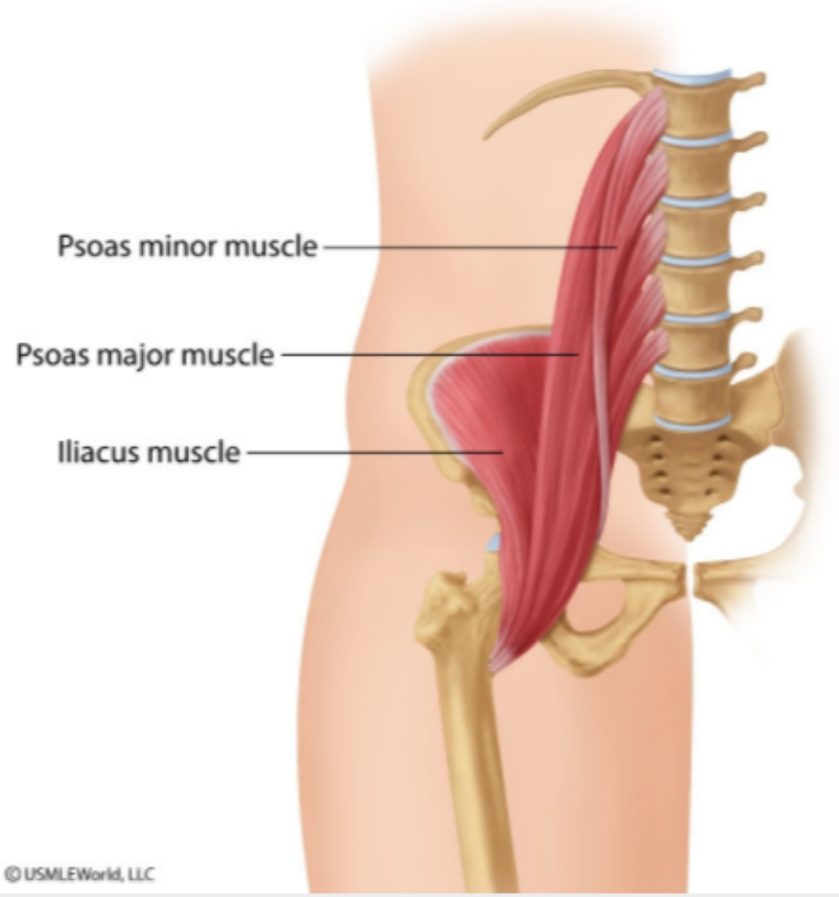

Zoom In | Zoom Out | Reset | Add To New Card | Existing Card

10
11
12
13
14
15
16
17
18
19
20
21
22
23
24
25
26
27
28
29
30
31
32
33
34
35
36
37
38
39
40

Exhibit Display

Muscles of the hip

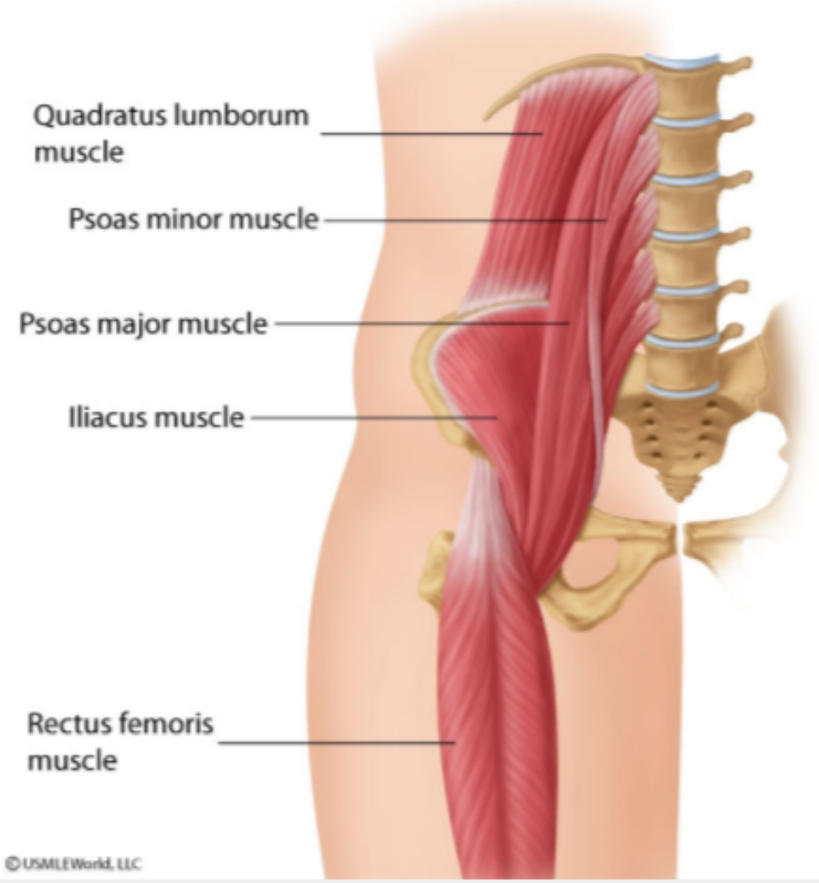

Zoom In | Zoom Out | Reset | Add To New Card | Existing Card

10
11
12
13
14
15
16
17
18
19
20
21
22
23
24
25
26
27
28
29
30
31
32
33
34
35
36
37
38
39
40

Exhibit Display

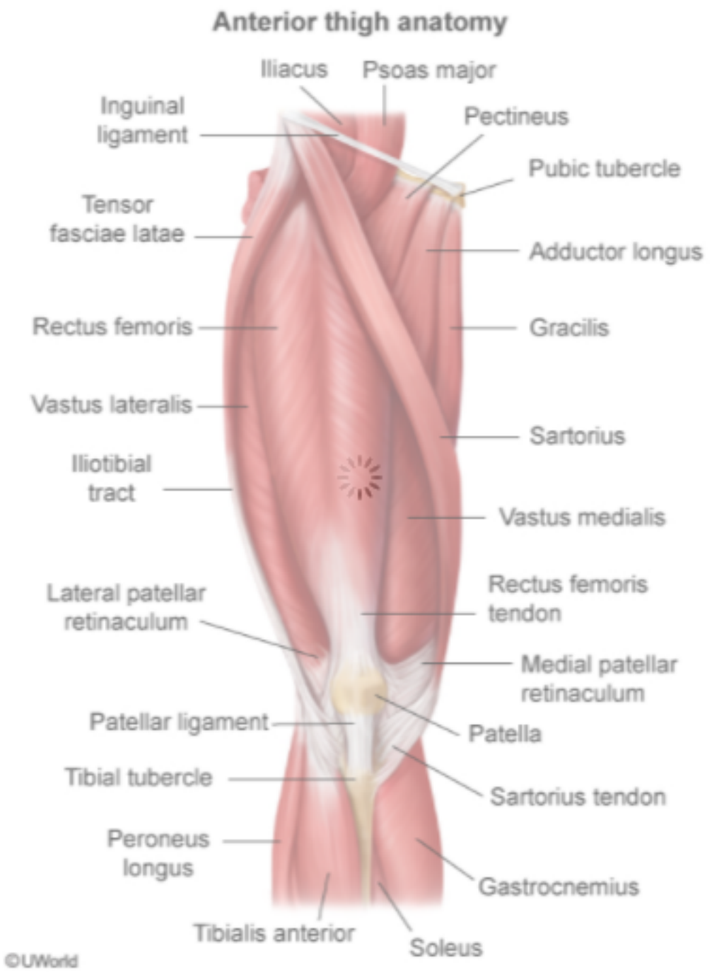

Zoom In | Zoom Out | Reset | Add To New Card | Existing Card

10
11
12
13
14
15
16
17
18
19
20
21
22
23
24
25
26
27
28
29
30
31
32
33
34
35
36
37
38
39
40

A 16-year-old high school quarterback comes to the office due to left shoulder pain. One week ago, he suffered an injury during a football game. The patient was running with the football when another player tackled him to the ground, causing him to land directly on the posterior aspect of his left shoulder. He developed severe pain immediately and did not return to the game. The patient has had persistent shoulder pain since the injury despite using ice and over-the-counter ibuprofen. He has been unable to resume playing football due to pain and weakness in his shoulder. On examination, there is diffuse bruising over the posterior aspect of the left shoulder. Abduction of the left arm is normal, but external rotation against resistance is weak and painful. Which of the following muscles is most likely injured?

A. Biceps brachii
B. Infraspinatus
C. Subscapularis
D. Supraspinatus
E. Teres major
F. Trapezius

Submit

A 16-year-old high school quarterback comes to the office due to left shoulder pain. One week ago, he suffered an injury during a football game. The patient was running with the football when another player tackled him to the ground, causing him to land directly on the posterior aspect of his left shoulder. He developed severe pain immediately and did not return to the game. The patient has had persistent shoulder pain since the injury despite using ice and over-the-counter ibuprofen. He has been unable to resume playing football due to pain and weakness in his shoulder. On examination, there is diffuse bruising over the posterior aspect of the left shoulder. Abduction of the left arm is normal, but external rotation against resistance is weak and painful. Which of the following muscles is most likely injured?

- A. Biceps brachii (1%)
- ✓ B. Infraspinatus (59%)
- C. Subscapularis (14%)
- D. Supraspinatus (9%)
- E. Teres major (11%)
- F. Trapezius (3%)

Omitted
Correct answer
B

59%
Answered correctly

02 secs
Time Spent

02/23/2020
Last Updated

Explanation

Rotator cuff muscles

10
11
12
13
14
15
16
17
18
19
20
21
22
23
24
25
26
27
28
29
30
31
32
33
34
35
36
37
38
39
40

Rotator cuff muscles

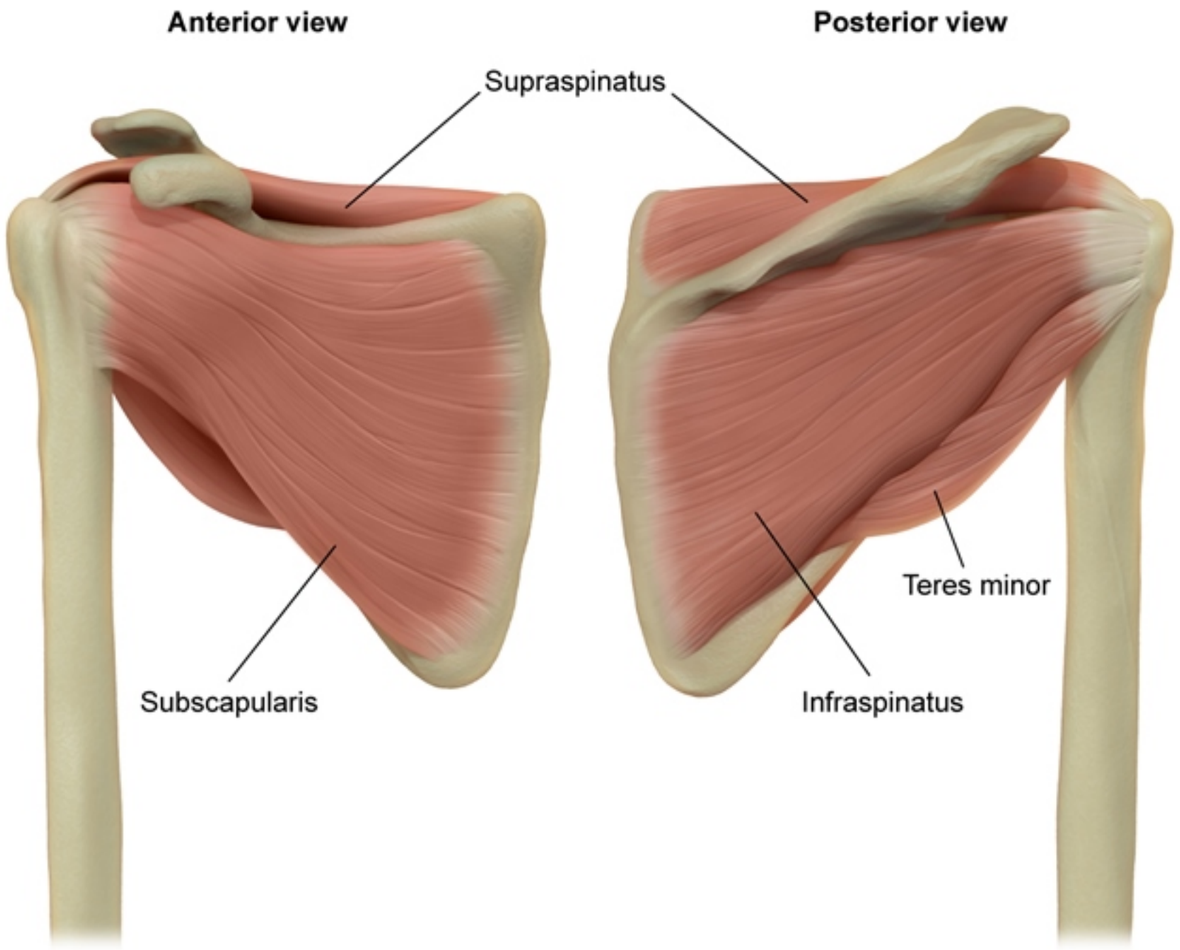

©UWorld

This patient's shoulder pain and weak, painful external rotation against resistance with preserved abduction are characteristic of an **infraspinatus injury**. The rotator cuff muscles all attach to the humeral head and stabilize the shoulder joint, in addition to moving the arm at the shoulder. A fall

This patient's shoulder pain and weak, painful external rotation against resistance with preserved abduction are characteristic of an **infraspinatus injury**. The rotator cuff muscles all attach to the humeral head and stabilize the shoulder joint, in addition to moving the arm at the shoulder. A fall onto the shoulder is a common mechanism for rotator cuff injury, resulting in acute shoulder pain and characteristic weakness depending on which muscle is involved:

- The supraspinatus inserts onto the superior aspect of the greater tubercle and abducts the arm **(Choice D)**.
- The **infraspinatus** inserts onto the posterolateral aspect of the greater tubercle and **externally rotates** the arm.
- The teres minor inserts onto the posterolateral aspect of the greater tubercle and helps with adduction and external rotation of the arm.
- The subscapularis inserts onto the lesser tubercle on the anterior aspect of the humerus and helps with adduction and internal rotation of the arm **(Choice C)**.

(Choice A) The biceps brachii is a 2-headed muscle that originates from the scapula and converges onto a single insertion point on the upper forearm. It is responsible for flexion at the elbow and forearm supination. Biceps injury can cause shoulder pain but would not affect external rotation of the arm at the shoulder.

(Choice E) Unlike the teres minor, the teres major is not a rotator cuff muscle. It arises from the inferior scapula and inserts below the humeral head onto the anterior aspect of the humerus. It assists with humeral extension (when the arm is flexed) and internal rotation of the arm at the shoulder.

(Choice F) The trapezius originates from the occipital bone and spinous processes of the cervical and thoracic vertebrae and inserts onto the scapula and clavicle. It helps move and rotate the scapula. Trapezius injury would cause difficulty with arm abduction and adduction, but would not affect external rotation of the humerus.

Educational objective:
The rotator cuff muscles (supraspinatus, infraspinatus, teres minor, and subscapularis) all insert onto the humeral head, allowing them to stabilize the shoulder joint and move the arm at the shoulder. An infraspinatus injury would result in shoulder pain and weak, painful external rotation of the arm against resistance.

References

- Rotator cuff injuries in professional and recreational athletes.

- The **infraspinatus** inserts onto the posterolateral aspect of the greater tubercle and **externally rotates** the arm.
- The teres minor inserts onto the posterolateral aspect of the greater tubercle and helps with adduction and external rotation of the arm.
- The subscapularis inserts onto the lesser tubercle on the anterior aspect of the humerus and helps with adduction and internal rotation of the arm **(Choice C)**.

(Choice A) The biceps brachii is a 2-headed muscle that originates from the scapula and converges onto a single insertion point on the upper forearm. It is responsible for flexion at the elbow and forearm supination. Biceps injury can cause shoulder pain but would not affect external rotation of the arm at the shoulder.

(Choice E) Unlike the teres minor, the teres major is not a rotator cuff muscle. It arises from the inferior scapula and inserts below the humeral head onto the anterior aspect of the humerus. It assists with humeral extension (when the arm is flexed) and internal rotation of the arm at the shoulder.

(Choice F) The trapezius originates from the occipital bone and spinous processes of the cervical and thoracic vertebrae and inserts onto the scapula and clavicle. It helps move and rotate the scapula. Trapezius injury would cause difficulty with arm abduction and adduction, but would not affect external rotation of the humerus.

Educational objective:
The rotator cuff muscles (supraspinatus, infraspinatus, teres minor, and subscapularis) all insert onto the humeral head, allowing them to stabilize the shoulder joint and move the arm at the shoulder. An infraspinatus injury would result in shoulder pain and weak, painful external rotation of the arm against resistance.

References

- Rotator cuff injuries in professional and recreational athletes.

Anatomy	Rheumatology/Orthopedics & Sports	Rotator cuff
Subject	System	Topic

Copyright © UWorld. All rights reserved.

10
11
12
13
14
15
16
17
18
19
20
21
22
23
24
25
26
27
28
29
30
31
32
33
34
35
36
37
38
39
40

©UWo

This patient's shoulder pa **tus injury**. The rotator cuff m A fall onto the shoulder is a con hich muscle is involved:

- The supraspinatus i
- The **infraspinatus i**
- The teres minor ins
- The subscapularis i f the arm **(Choice C)**

(Choice A) The biceps b forearm. It is responsible rotation of the arm at the s

(Choice E) Unlike the ter al head onto the anterior aspect of the humerus. It assists with humeral extension (when the arm is flexed) and internal rotation of the arm at the shoulder.

Exhibit Display

Rotator cuff muscles

Muscle	Origin on scapula	Attachment on humerus	Function on arm	Innervation
Supraspinatus	Supraspinous fossa	Superior aspect of greater tubercle	Abduction (primarily <15°)	Suprascapular nerve
Infraspinatus	Infraspinous fossa	Posterolateral aspect of greater tubercle	External rotation	Suprascapular nerve
Teres minor	Lateral border	Posterolateral aspect of greater tubercle	Adduction & external rotation	Axillary nerve
Subscapularis	Subscapular fossa	Lesser tubercle	Adduction & internal rotation	Upper & lower subscapular nerve

Add To New Card | Existing Card

Teres minor

Exhibit Display

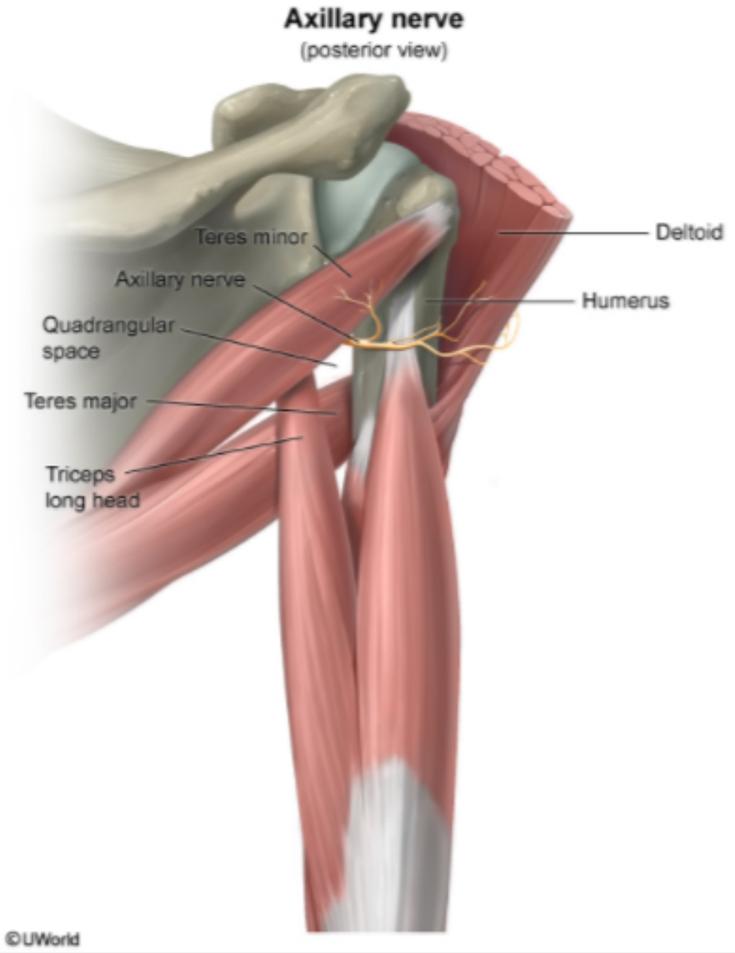

Zoom In | Zoom Out | Reset | Add To New Card | Existing Card

shoulder.

10
11
12
13
14
15
16
17
18
19
20
21
22
23
24
25
26
27
28
29
30
31
32
33
34
35
36
37
38
39
40

- The **infraspinatus** inserts onto the posterolateral aspect of the greater tubercle and **externally rotates** the arm

Exhibit Display

Superficial back muscles

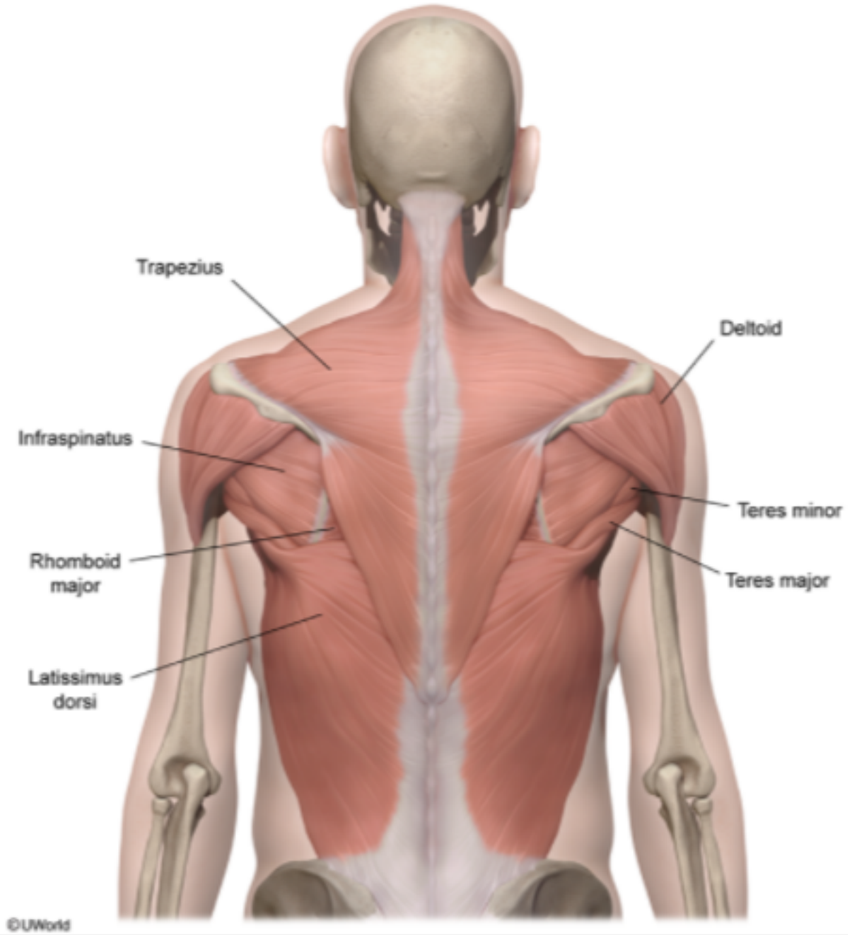

Zoom In | Zoom Out | Reset | Add To New Card | Existing Card

10
11
12
13
14
15
16
17
18
19
20
21
22
23
24
25
26
27
28
29
30
31
32
33
34
35
36
37
38
39
40

10
11
12
13
14
15
16
17
18
19
20
21
22
23
24
25
26
27
28
29
30
31
32
33
34
35
36
37
38
39
40

A 45-year-old man comes to the office due to right ankle pain for the past 2 days. The patient was running downhill on a dirt trail when he twisted his ankle inward. Since then, he has had pain and swelling at the right ankle but is able to walk unassisted. The patient has no other medical conditions and takes no chronic medications. On examination, there is bluish discoloration over the lateral aspect of the joint. He has maximal tenderness to palpation at the anterolateral aspect of the ankle joint. Forced inversion of the foot also increases the pain. Which of the following structures is most likely injured in this patient?

A. Achilles tendon

B. Deltoid ligament

C. Subtalar joint

D. Talofibular ligament

E. Tibiofibular ligament

Submit

A 45-year-old man comes to the office due to right ankle pain for the past 2 days. The patient was running downhill on a dirt trail when he twisted his ankle inward. Since then, he has had pain and swelling at the right ankle but is able to walk unassisted. The patient has no other medical conditions and takes no chronic medications. On examination, there is bluish discoloration over the lateral aspect of the joint. He has maximal tenderness to palpation at the anterolateral aspect of the ankle joint. Forced inversion of the foot also increases the pain. Which of the following structures is most likely injured in this patient?

A. Achilles tendon (1%)
B. Deltoid ligament (6%)
C. Subtalar joint (2%)
✓ D. Talofibular ligament (80%)
E. Tibiofibular ligament (8%)

Omitted
Correct answer
D

80%
Answered correctly

02 secs
Time Spent

05/30/2020
Last Updated

Explanation

10
11
12
13
14
15
16
17
18
19
20
21
22
23
24
25
26
27
28
29
30
31
32
33
34
35
36
37
38
39
40

Ankle ligaments

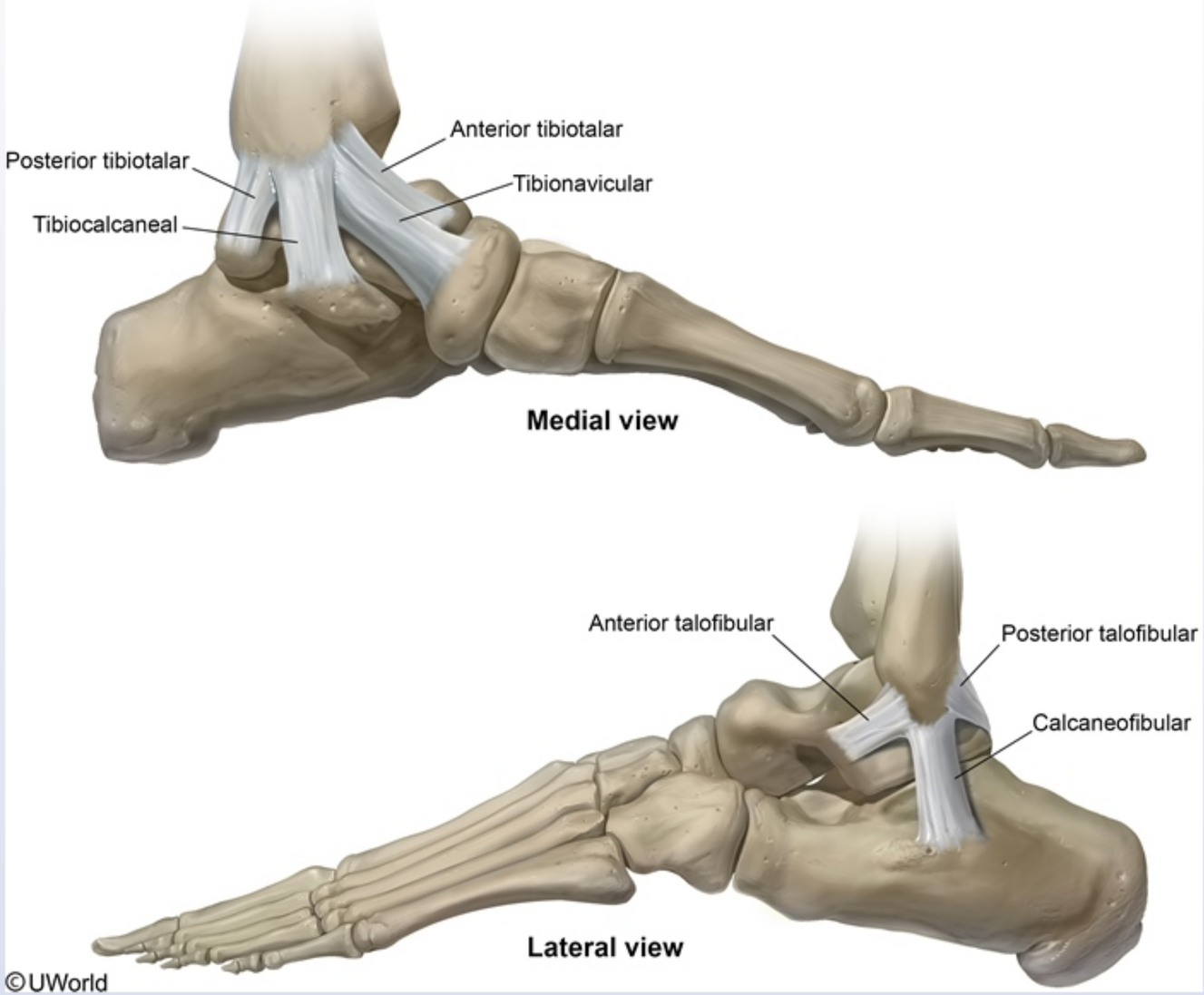

This patient has a right lateral **ankle sprain**, which is most often due to inversion of a plantar-flexed foot. The ankle is stabilized laterally by the

10
11
12
13
14
15
16
17
18
19
20
21
22
23
24
25
26
27
28
29
30
31
32
33
34
35
36
37
38
39
40

©UWorld

This patient has a right lateral **ankle sprain**, which is most often due to inversion of a plantar-flexed foot. The ankle is stabilized laterally by the anterior inferior tibiofibular, anterior talofibular, posterior talofibular, and calcaneofibular ligaments.

The lateral ankle ligaments are weaker and are injured more often than the medial ligaments. The most common ankle sprains involve only the **anterior talofibular ligament** and present with pain and ecchymosis at the **anterolateral aspect** of the ankle. However, stronger forces can injure multiple ligaments, leading to significant joint instability with possible nerve injury and joint dislocation/fracture.

(Choice A) The soleus and gastrocnemius muscles combine to form the Achilles tendon, which inserts on the posterior calcaneus and acts in ankle flexion. The tendon can be injured with sudden forces during strenuous activities (eg, sudden pivoting on a foot or rapid acceleration).

(Choice B) The medial deltoid ligament complex is stronger than the other ligaments and is not commonly injured. Forced eversion of the ankle can damage the deltoid ligament but more commonly causes an avulsion fracture of the medial malleolus.

(Choice C) The subtalar joint is at the posterior junction between the talus and the calcaneus and is reinforced by the talocalcaneal ligaments. The joint is involved with inversion, eversion, dorsiflexion, and plantar flexion of the foot, but is infrequently injured.

(Choice E) Dorsiflexion and/or eversion of the ankle can cause a high ankle sprain affecting the syndesmotic structures (interosseous membrane and anterior, posterior, and transverse tibiofibular ligaments), which connect the tibia and fibula. Injury to these structures is uncommon as they can withstand severe forces. Patients usually have an unstable ankle joint with tenderness at the distal tibiofibular joint, but no significant swelling.

Educational objective:
Lateral ankle sprain is due to inversion of a plantar-flexed foot and most commonly involves the anterior talofibular ligament. Stronger forces can cause joint instability by injuring additional ligaments.

References

- Ankle sprains and instability.

Anatomy	Rheumatology/Orthopedics & Sports	Ankle trauma
Subject	System	Topic

Copyright © UWorld. All rights reserved.

10
11
12
13
14
15
16
17
18
19
20
21
22
23
24
25
26
27
28
29
30
31
32
33
34
35
36
37
38
39
40

A 68-year-old woman is brought to the emergency department with severe right hip pain after a fall. She was walking down a hallway when she tripped on a rug and fell against a wall and then to the floor, landing on her hip. The patient has a history of depression and polymyalgia rheumatica. Current medications include sertraline and low-dose prednisone. She also has a 40-pack-year smoking history. Blood pressure is 145/85 mm Hg and pulse is 96/min. The patient appears to be in significant pain. She is unable to move the right hip, and the right leg appears shorter than the left. A pelvic x-ray is shown in the image below.

Injury involving which of the following arteries is most likely to lead to osteonecrosis in this patient?

A. Deep femoral

B. Inferior gluteal

C. Lateral circumflex

10
11
12
13
14
15
16
17
18
19
20
21
22
23
24
25
26
27
28
29
30
31
32
33
34
35
36
37
38
39
40

Injury involving which of the following arteries is most likely to lead to osteonecrosis in this patient?

- A. Deep femoral
- B. Inferior gluteal
- C. Lateral circumflex
- D. Medial circumflex
- E. Obturator

Submit

10
11
12
13
14
15
16
17
18
19
20
21
22
23
24
25
26
27
28
29
30
31
32
33
34
35
36
37
38
39
40

Injury involving which of the following arteries is most likely to lead to osteonecrosis in this patient?

A. Deep femoral (7%)

B. Inferior gluteal (2%)

C. Lateral circumflex (26%)

✓ D. Medial circumflex (57%)

E. Obturator (5%)

Omitted
Correct answer

57%
Answered correctly

07 secs
Time Spent

03/01/2020
Last Updated

10
11
12
13
14
15
16
17
18
19
20
21
22
23
24
25
26
27
28
29
30
31
32
33
34
35
36
37
38
39
40

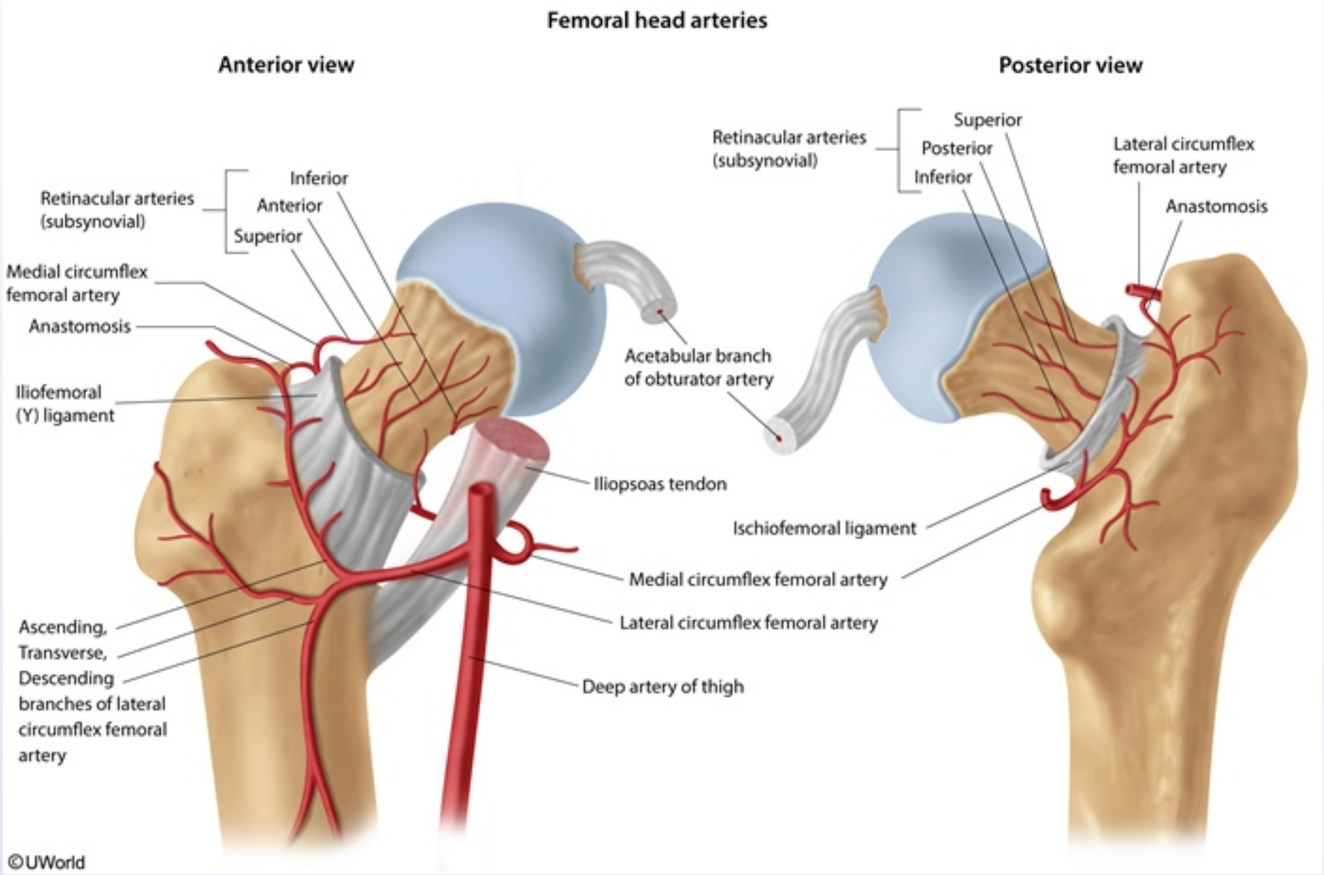

This patient's x-ray shows a right **femoral neck fracture**, which is common in elderly patients with osteoporosis who have sustained a fall. Femoral neck fractures, especially when displaced, put the femoral head at risk for **osteonecrosis** if its blood supply is disrupted. The blood supply to the femoral head derives mainly from the ascending cervical and retinacular branches of the **medial circumflex artery**. These vessels are especially vulnerable to damage from fractures of the femoral neck due to their close association with it.

(Choice A) The deep femoral artery gives rise to the medial and lateral femoral circumflex arteries. Injury to the femoral artery is less likely as it is more remote from the femoral neck.

10
11
12
13
14
15
16
17
18
19
20
21
22
23
24
25
26
27
28
29
30
31
32
33
34
35
36
37
38
39
40

This patient's x-ray shows a right **femoral neck fracture**, which is common in elderly patients with osteoporosis who have sustained a fall. Femoral neck fractures, especially when displaced, put the femoral head at risk for **osteonecrosis** if its blood supply is disrupted. The blood supply to the femoral head derives mainly from the ascending cervical and retinacular branches of the **medial circumflex artery**. These vessels are especially vulnerable to damage from fractures of the femoral neck due to their close association with it.

(Choice A) The deep femoral artery gives rise to the medial and lateral femoral circumflex arteries. Injury to the femoral artery is less likely as it is more remote from the femoral neck.

(Choices B and C) Branches of the lateral circumflex and superior and inferior gluteal arteries join with the medial circumflex artery to form the trochanteric anastomosis. However, these arteries provide only minor contributions to the blood supply of the femoral head and neck.

(Choice E) The obturator artery gives rise to the artery of the ligamentum teres, which supplies a minor portion of the femoral head. This vessel is important in children because it supplies the region of the femoral head proximal to the epiphyseal growth plate, but it is of minimal clinical significance in adults.

Educational objective:
The medial femoral circumflex artery and its branches provide the majority of the blood supply to the femoral head and neck. Injury to these vessels due to a displaced femoral neck fracture can cause osteonecrosis of the femoral head.

References

- Early prediction of femoral head avascular necrosis following neck fracture.

Anatomy	Rheumatology/Orthopedics & Sports	Lower extremity long bone fracture
Subject	System	Topic

Copyright © UWorld. All rights reserved.

10
11
12
13
14
15
16
17
18
19
20
21
22
23
24
25
26
27
28
29
30
31
32
33
34
35
36
37
38
39
40

circumflex femoral

Exhibit Display

Zoom In | Zoom Out | Reset | Add To New Card | Existing Card

A 19-year-old woman is evaluated in the clinic due to right hand clumsiness. The patient injured the right upper extremity after falling off her bicycle 6 months ago. She has since had a "pins and needles" sensation in the right hand associated with mild weakness. The patient is worried as these symptoms are interfering with her piano lessons and she has an upcoming recital in 3 weeks. Physical examination shows decreased sensation over the fifth digit and a flattened hypothenar eminence. Triceps reflexes are 2+ and symmetric bilaterally. The nerve affected in this patient is commonly injured at which of the following locations?

A. Carpal tunnel

B. Coracobrachialis muscle

C. Head of the radius

D. Hook of the hamate

E. Midshaft of the humerus

F. Surgical neck of the humerus

Submit

A 19-year-old woman is evaluated in the clinic due to right hand clumsiness. The patient injured the right upper extremity after falling off her bicycle 6 months ago. She has since had a "pins and needles" sensation in the right hand associated with mild weakness. The patient is worried as these symptoms are interfering with her piano lessons and she has an upcoming recital in 3 weeks. Physical examination shows decreased sensation over the fifth digit and a flattened hypothenar eminence. Triceps reflexes are 2+ and symmetric bilaterally. The nerve affected in this patient is commonly injured at which of the following locations?

- A. Carpal tunnel (4%)
- B. Coracobrachialis muscle (2%)
- C. Head of the radius (6%)
- ✓ D. Hook of the hamate (78%)
- E. Midshaft of the humerus (4%)
- F. Surgical neck of the humerus (2%)

Omitted
Correct answer
D

78%
Answered correctly

02 secs
Time Spent

07/08/2020
Last Updated

Explanation

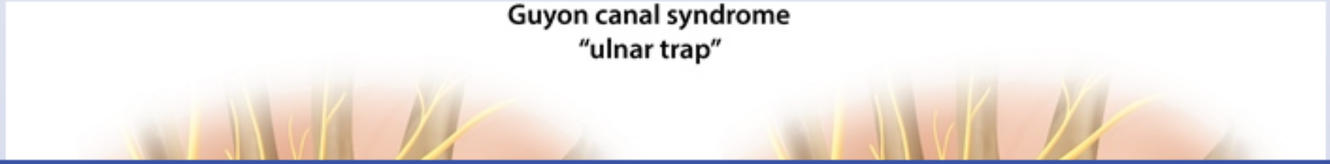

10
11
12
13
14
15
16
17
18
19
20
21
22
23
24
25
26
27
28
29
30
31
32
33
34
35
36
37
38
39
40

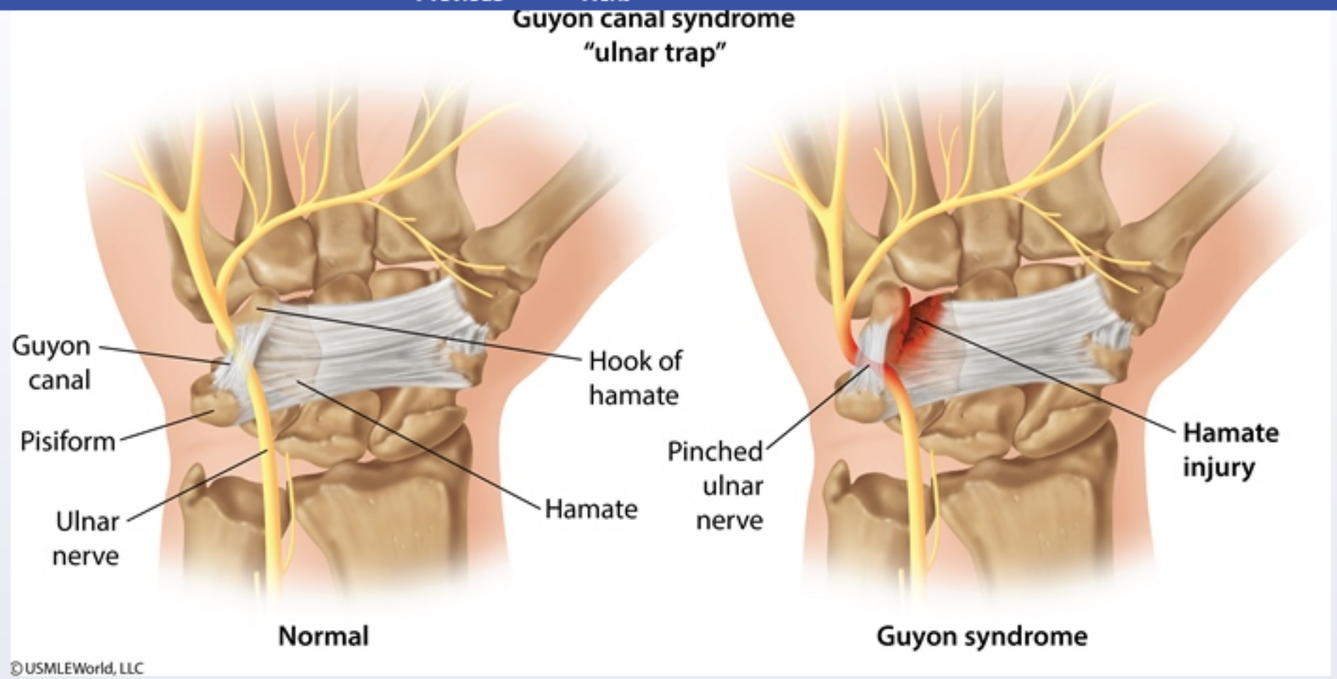

This patient's presentation is consistent with ulnar neuropathy. The ulnar nerve is a branch of the medial cord of the brachial plexus derived from the C8-T1 ventral rami. It enters the forearm after passing behind the medial epicondyle of the humerus. Within the forearm, it innervates the flexor carpi ulnaris and the medial portion of the flexor digitorum profundus. The nerve then enters the wrist between the **hook of the hamate** and the pisiform bone in a fibroosseous tunnel known as **Guyon's canal**. Here, it divides into a superficial branch that provides sensation over the **medial 1½ digits** and hypothenar eminence and a deep motor branch that supplies most of the intrinsic muscles of the hand.

The ulnar nerve is most commonly injured at the elbow ("funny bone") due to trauma or nerve compression, but it can also be injured at the wrist as it runs through Guyon's canal. Nerve damage may cause sensory loss in the ulnar distribution with weakness on wrist flexion/adduction, finger abduction/adduction, and flexion of the fourth/fifth digits. The **hypothenar eminence** can appear flattened due to denervated muscle **atrophy**. Weakness of the lumbricals in the fourth/fifth digits may also produce an "ulnar claw" deformity during finger extension.

(Choice A) Carpal tunnel syndrome can result from any condition that reduces the size of the carpal tunnel and compresses the median nerve (eg, pregnancy, hypothyroidism). Patients typically have pain/paresthesias affecting the first 3½ digits. Thenar atrophy with weakness on thumb

Normal	Guyon syndrome

© USMLEWorld, LLC

This patient's presentation is consistent with ulnar neuropathy. The ulnar nerve is a branch of the medial cord of the brachial plexus derived from the C8-T1 ventral rami. It enters the forearm after passing behind the medial epicondyle of the humerus. Within the forearm, it innervates the flexor carpi ulnaris and the medial portion of the flexor digitorum profundus. The nerve then enters the wrist between the **hook of the hamate** and the pisiform bone in a fibroosseous tunnel known as **Guyon's canal**. Here, it divides into a superficial branch that provides sensation over the **medial 1½ digits** and hypothenar eminence and a deep motor branch that supplies most of the intrinsic muscles of the hand.

The ulnar nerve is most commonly injured at the elbow ("funny bone") due to trauma or nerve compression, but it can also be injured at the wrist as it runs through Guyon's canal. Nerve damage may cause sensory loss in the ulnar distribution with weakness on wrist flexion/adduction, finger abduction/adduction, and flexion of the fourth/fifth digits. The **hypothenar eminence** can appear flattened due to denervated muscle **atrophy**. Weakness of the lumbricals in the fourth/fifth digits may also produce an "ulnar claw" deformity during finger extension.

(Choice A) Carpal tunnel syndrome can result from any condition that reduces the size of the carpal tunnel and compresses the median nerve (eg, pregnancy, hypothyroidism). Patients typically have pain/paresthesias affecting the first 3½ digits. Thenar atrophy with weakness on thumb abduction/opposition may also be seen.

(Choice B) The coracobrachialis muscle lies deep to the biceps brachii and is perforated and innervated by the musculocutaneous nerve. Nerve injury may result in decreased strength on forearm flexion and sensory loss over the lateral forearm.

(Choice C) Subluxation of the radial head can injure the deep branch of the radial nerve during its passage through the supinator canal, leading to weakness during finger and thumb extension ("finger drop").

(Choice E) Fracture of the midshaft of the humerus typically results in radial nerve injury leading to paralysis of the hand and finger extensor muscles ("wrist drop") with sensory loss over the posterior forearm and dorsolateral hand.

(Choice F) Fracture of the surgical neck of the humerus may cause axillary nerve injury leading to paralysis of the deltoid and teres minor muscles with sensory loss over the lateral upper arm.

Educational objective:
The ulnar nerve can be injured at the medial epicondyle of the humerus ("funny bone") or in Guyon's canal near the hook of the hamate and pisiform bone in the wrist. Patients often have sensory loss over the medial 1½ digits and hypothenar eminence, and weakness on wrist

Normal	Guyon syndrome

Exhibit Display

Nerves of the upper limb Important nerves in the arm

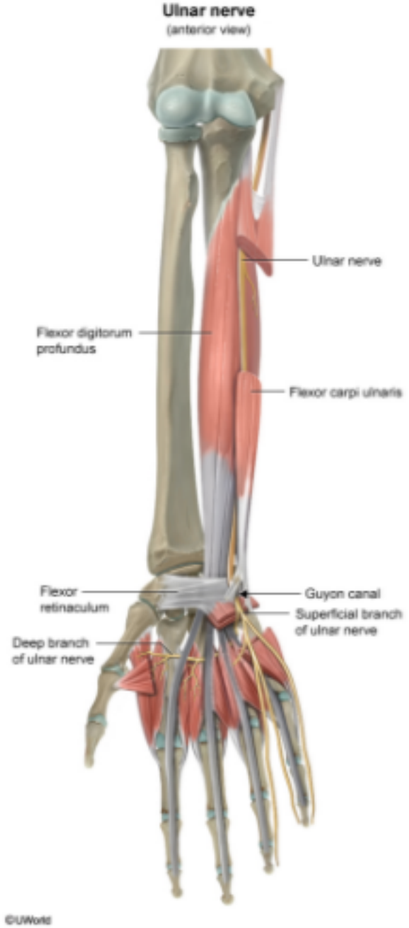

Zoom In Zoom Out Reset Add To New Card | Existing Card

pisiform bone in the wrist. Patients often have sensory loss over the medial 1½ digits and hypothenar eminence, and weakness on wrist

10
11
12
13
14
15
16
17
18
19
20
21
22
23
24
25
26
27
28
29
30
31
32
33
34
35
36
37
38
39
40

Normal | Guyon syndrome

Exhibit Display

Nerves of the upper limb Important nerves in the arm

Ulnar nerve

Motor function	Cutaneous innervation
Finger adduction & abduction other than thumb, thumb adduction, flexion of digits 4 & 5, wrist flexion & adduction	

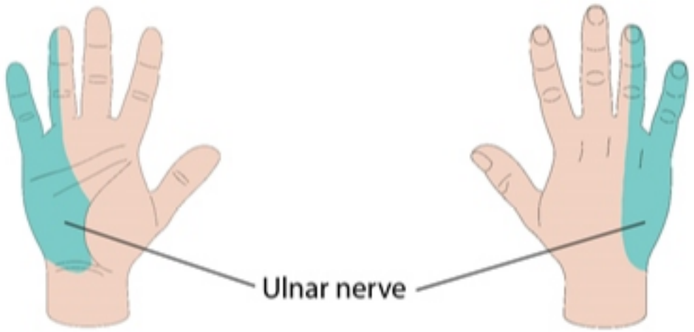

©UWorld

Zoom In | Zoom Out | Reset | Add To New Card | Existing Card

pisiform bone in the wrist. Patients often have sensory loss over the medial 1½ digits and hypothenar eminence, and weakness on wrist

Weakness of the lumbricals in the fourth/fifth digits may also produce an "ulnar claw" deformity during finger extension.

(Choice A) Carpal tunnel syndrome can result from any condition that reduces the size of the carpal tunnel and compresses the median nerve (eg, pregnancy, hypothyroidism). Patients typically have pain/paresthesias affecting the first 3½ digits. Thenar atrophy with weakness on thumb abduction/opposition may also be seen.

(Choice B) The coracobrachialis muscle lies deep to the biceps brachii and is perforated and innervated by the musculocutaneous nerve. Nerve injury may result in decreased strength on forearm flexion and sensory loss over the lateral forearm.

(Choice C) Subluxation of the radial head can injure the deep branch of the radial nerve during its passage through the supinator canal, leading to weakness during finger and thumb extension ("finger drop").

(Choice E) Fracture of the midshaft of the humerus typically results in radial nerve injury leading to paralysis of the hand and finger extensor muscles ("wrist drop") with sensory loss over the posterior forearm and dorsolateral hand.

(Choice F) Fracture of the surgical neck of the humerus may cause axillary nerve injury leading to paralysis of the deltoid and teres minor muscles with sensory loss over the lateral upper arm.

Educational objective:
The ulnar nerve can be injured at the medial epicondyle of the humerus ("funny bone") or in Guyon's canal near the hook of the hamate and pisiform bone in the wrist. Patients often have sensory loss over the medial 1½ digits and hypothenar eminence, and weakness on wrist flexion/adduction, finger abduction/adduction, and flexion of the fourth/fifth digits. The hypothenar eminence may flatten due to muscle atrophy.

References

- Ulnar neuropathy at the wrist.
- Diagnosis and Treatment of Work-Related Ulnar Neuropathy at the Elbow.

Anatomy	Rheumatology/Orthopedics & Sports	Ulnar nerve neuropathy
Subject	System	Topic

Copyright © UWorld. All rights reserved.

10
11
12
13
14
15
16
17
18
19
20
21
22
23
24
25
26
27
28
29
30
31
32
33
34
35
36
37
38
39
40

A 15-year-old boy comes to the office due to right arm numbness. He plays on his high school baseball team and has been intensively practicing his pitching for an upcoming game. For the past several weeks, the patient has had fluctuating tingling and numbness involving the right shoulder, arm, and hand. He also has recently developed dull pain in the right little finger and hand. The symptoms worsen with overhead activities and when throwing a baseball. The patient has no medical problems other than being told that he has an extra rib. On examination, there is right-sided weakness of the intrinsic hand muscles. Which of the following muscles is most likely contributing to this patient's condition?

A. Coracobrachialis muscle

B. Scalene muscles

C. Subscapularis muscle

D. Teres major muscle

E. Triceps brachii

Submit

10
11
12
13
14
15
16
17
18
19
20
21
22
23
24
25
26
27
28
29
30
31
32
33
34
35
36
37
38
39
40

A 15-year-old boy comes to the office due to right arm numbness. He plays on his high school baseball team and has been intensively practicing his pitching for an upcoming game. For the past several weeks, the patient has had fluctuating tingling and numbness involving the right shoulder, arm, and hand. He also has recently developed dull pain in the right little finger and hand. The symptoms worsen with overhead activities and when throwing a baseball. The patient has no medical problems other than being told that he has an extra rib. On examination, there is right-sided weakness of the intrinsic hand muscles. Which of the following muscles is most likely contributing to this patient's condition?

A. Coracobrachialis muscle

B. Scalene muscles

C. Subscapularis muscle

D. Teres major muscle

E. Triceps brachii

Submit

A 15-year-old boy comes to the office due to right arm numbness. He plays on his high school baseball team and has been intensively practicing his pitching for an upcoming game. For the past several weeks, the patient has had fluctuating tingling and numbness involving the right shoulder, arm, and hand. He also has recently developed dull pain in the right little finger and hand. The symptoms worsen with overhead activities and when throwing a baseball. The patient has no medical problems other than being told that he has an extra rib. On examination, there is right-sided weakness of the intrinsic hand muscles. Which of the following muscles is most likely contributing to this patient's condition?

- A. Coracobrachialis muscle (11%)
- ✓ B. Scalene muscles (59%)
- C. Subscapularis muscle (17%)
- D. Teres major muscle (4%)
- E. Triceps brachii (6%)

Omitted
Correct answer
B

59%
Answered correctly

03 secs
Time Spent

05/25/2020
Last Updated

Explanation

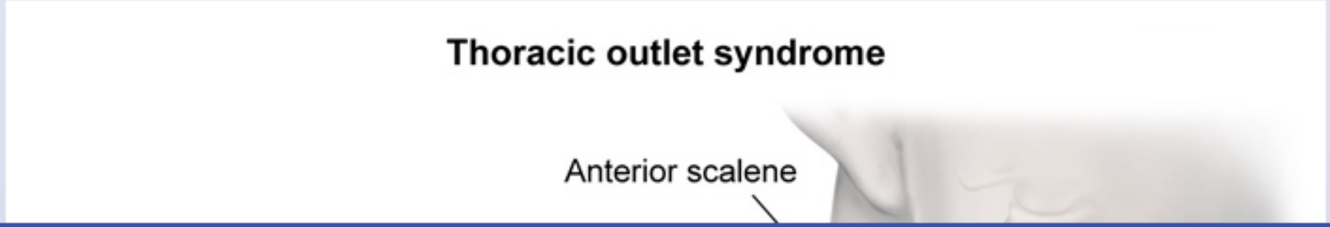

10
11
12
13
14
15
16
17
18
19
20
21
22
23
24
25
26
27
28
29
30
31
32
33
34
35
36
37
38
39
40

Thoracic outlet syndrome

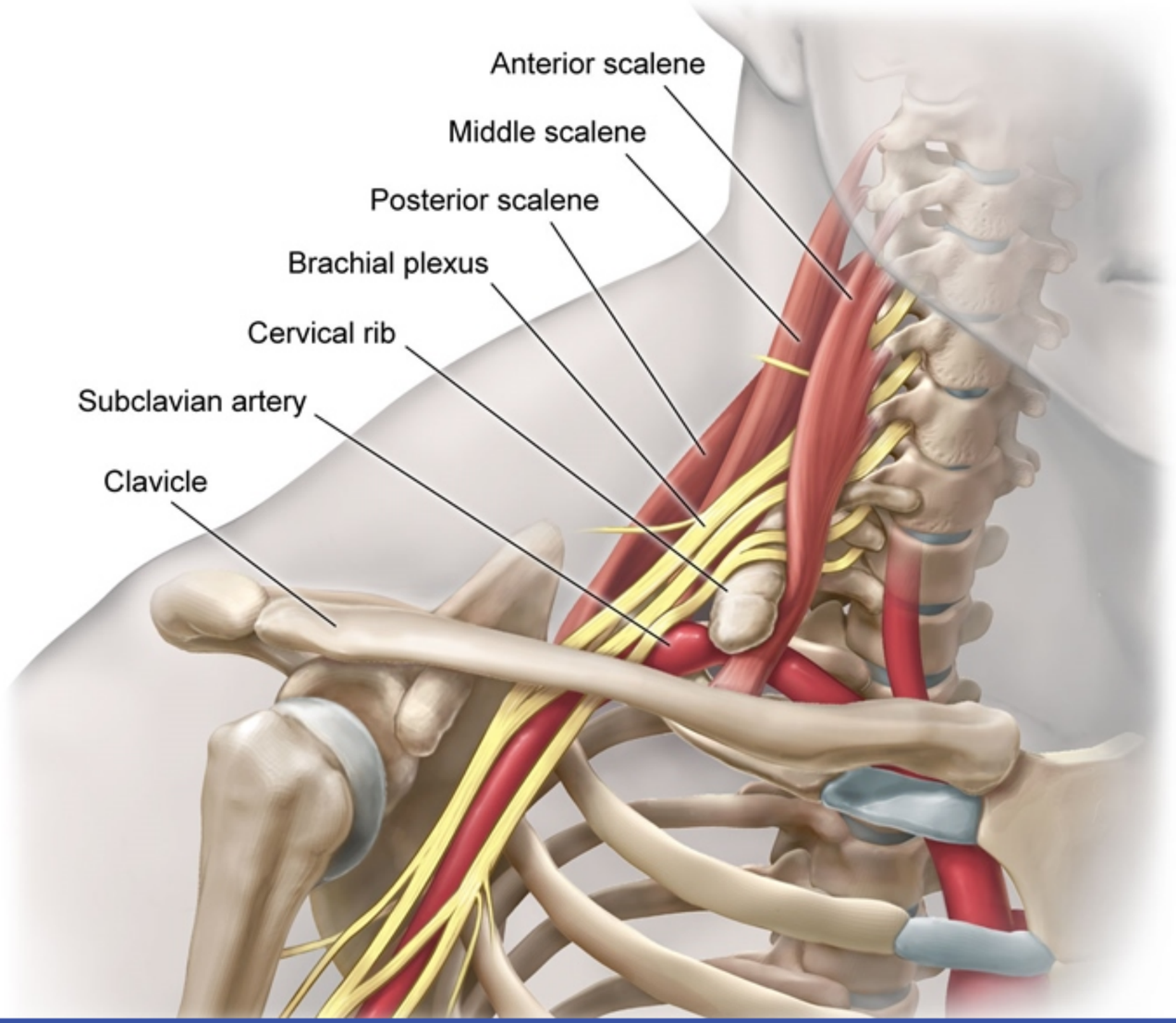

This patient's upper extremity neurologic symptoms in the setting of an extra rib are highly suggestive of **thoracic outlet syndrome** (TOS). The thoracic outlet refers to the region above the first rib and behind the clavicle that is bordered by the cervical vertebral bones and the sternum. **Compression** of the **brachial plexus** as it passes through the thoracic outlet can cause upper extremity numbness, tingling, and weakness (most often in an ulnar distribution due to compression of the lower trunk). Involvement of the **subclavian vein and artery** can also occur and lead to upper extremity swelling and exertional arm pain.

TOS most commonly occurs due to compression of the brachial plexus within the **scalene triangle**, which is formed by the anterior and middle scalene muscles and the first rib. The anterior scalene muscle originates from the C3-C6 transverse processes and attaches to the scalene tubercle of the first rib. The middle scalene originates from the C2-C7 transverse processes and inserts into the posterior portion of the first rib. The brachial plexus trunks and subclavian artery pass between the anterior and middle scalenes; the subclavian vein runs anterior to the anterior scalene.

The presence of an **anomalous cervical rib** or scalene muscular anomalies can predispose to TOS. Affected patients typically have a history of trauma or repetitive overhead arm movements (eg, swimming, stacking boxes).

(Choice A) The coracobrachialis originates from the coracoid process of the scapula and acts to flex the arm at the glenohumeral joint. The musculocutaneous nerve pierces the muscle near its insertion into the humerus; overuse of the coracobrachialis (eg, excessive bench pressing) can cause entrapment of the musculocutaneous nerve, causing impaired elbow flexion and lateral forearm sensory loss.

(Choice C) The subscapularis muscle originates in the subscapular fossa of the scapula and inserts into the lesser tubercle of the humerus. It acts to adduct and internally rotate the humerus.

(Choices D and E) The teres major muscle and long head of the triceps brachii form the inferior and medial borders of the quadrangular space through which the axillary nerve passes. Entrapment of the axillary nerve within the quadrangular space can cause sensory loss over the lateral shoulder and impair shoulder abduction.

Educational objective:
Thoracic outlet syndrome (TOS) is most often caused by compression of the brachial plexus as it passes through the scalene triangle, the space bordered by the anterior and middle scalene muscles and the first rib. Symptoms typically include upper extremity numbness, tingling, and weakness that worsen with repetitive overhead arm movements. The presence of an anomalous cervical rib is a risk factor for TOS.

References

10
11
12
13
14
15
16
17
18
19
20
21
22
23
24
25
26
27
28
29
30
31
32
33
34
35
36
37
38
39
40

scalene muscles and the first rib. The anterior scalene muscle originates from the C3-C6 transverse processes and attaches to the scalene tubercle of the first rib. The middle scalene originates from the C2-C7 transverse processes and inserts into the posterior portion of the first rib. The brachial plexus trunks and subclavian artery pass between the anterior and middle scalenes; the subclavian vein runs anterior to the anterior scalene.

The presence of an **anomalous cervical rib** or scalene muscular anomalies can predispose to TOS. Affected patients typically have a history of trauma or repetitive overhead arm movements (eg, swimming, stacking boxes).

(Choice A) The coracobrachialis originates from the coracoid process of the scapula and acts to flex the arm at the glenohumeral joint. The musculocutaneous nerve pierces the muscle near its insertion into the humerus; overuse of the coracobrachialis (eg, excessive bench pressing) can cause entrapment of the musculocutaneous nerve, causing impaired elbow flexion and lateral forearm sensory loss.

(Choice C) The subscapularis muscle originates in the subscapular fossa of the scapula and inserts into the lesser tubercle of the humerus. It acts to adduct and internally rotate the humerus.

(Choices D and E) The teres major muscle and long head of the triceps brachii form the inferior and medial borders of the quadrangular space through which the axillary nerve passes. Entrapment of the axillary nerve within the quadrangular space can cause sensory loss over the lateral shoulder and impair shoulder abduction.

Educational objective:
Thoracic outlet syndrome (TOS) is most often caused by compression of the brachial plexus as it passes through the scalene triangle, the space bordered by the anterior and middle scalene muscles and the first rib. Symptoms typically include upper extremity numbness, tingling, and weakness that worsen with repetitive overhead arm movements. The presence of an anomalous cervical rib is a risk factor for TOS.

References

- Understanding thoracic outlet syndrome.

Anatomy	Rheumatology/Orthopedics & Sports	Thoracic outlet syndrome
Subject	System	Topic

Copyright © UWorld. All rights reserved.

scalene muscles and the first rib. The anterior scalene muscle originates from the C3-C6 transverse processes and attaches to the scalene

Exhibit Display

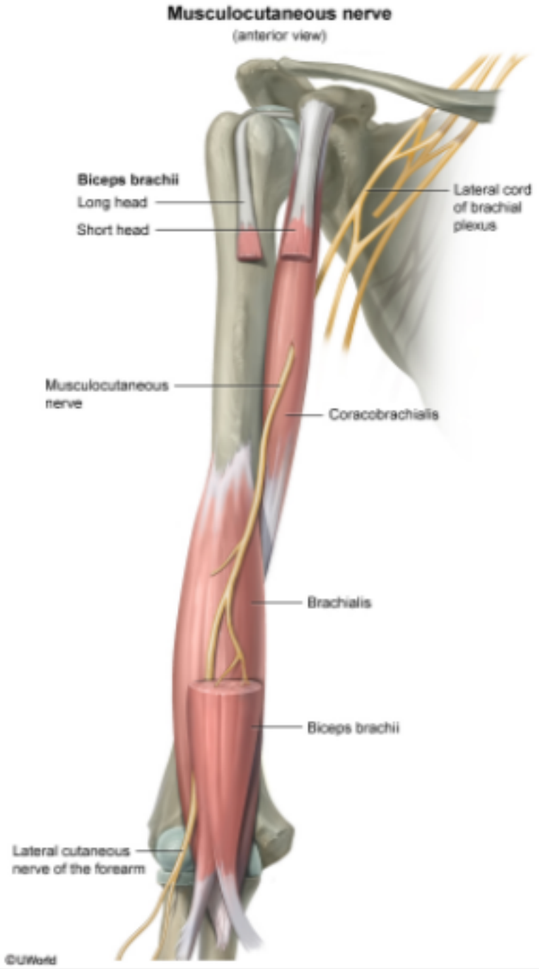

Zoom In | Zoom Out | Reset | Add To New Card | Existing Card

scalene muscles and the first rib. The anterior scalene muscle originates from the C3-C6 transverse processes and attaches to the scalene

Exhibit Display

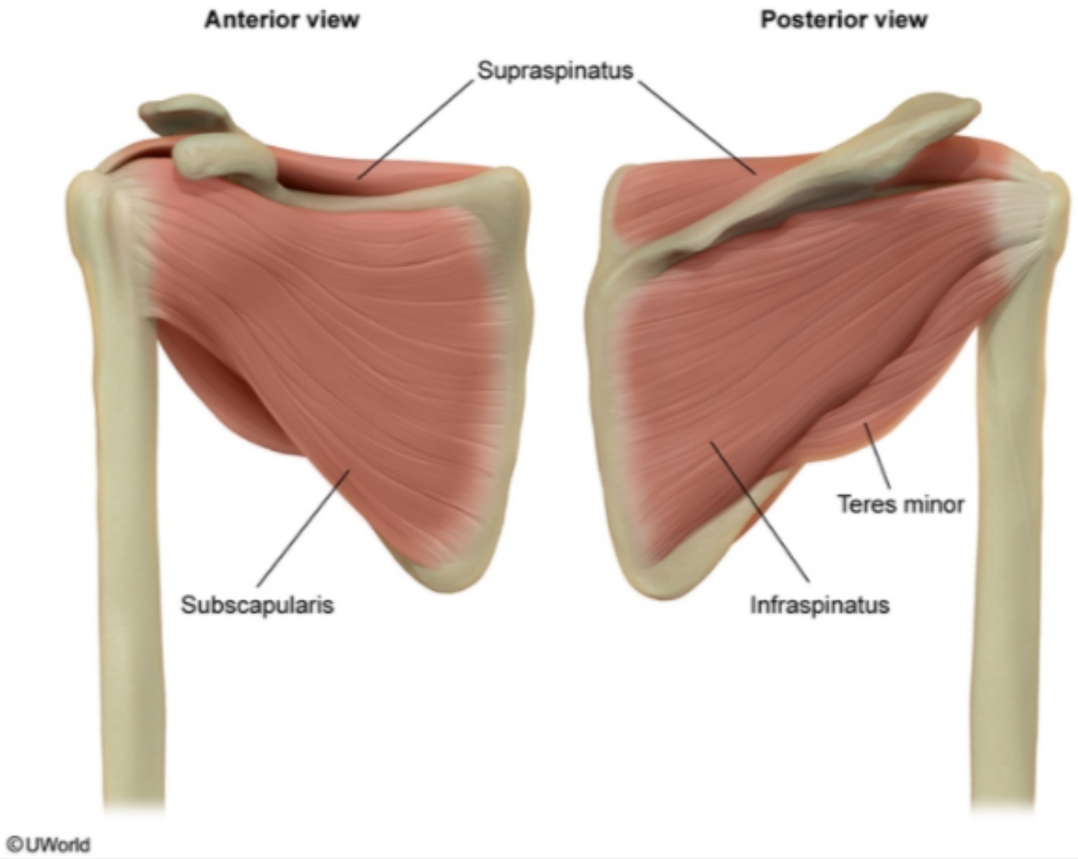

Zoom In | Zoom Out | Reset | Add To New Card | Existing Card

10
11
12
13
14
15
16
17
18
19
20
21
22
23
24
25
26
27
28
29
30
31
32
33
34
35
36
37
38
39
40

scalene muscles and the first rib. The anterior scalene muscle originates from the C3-C6 transverse processes and attaches to the scalene

Exhibit Display

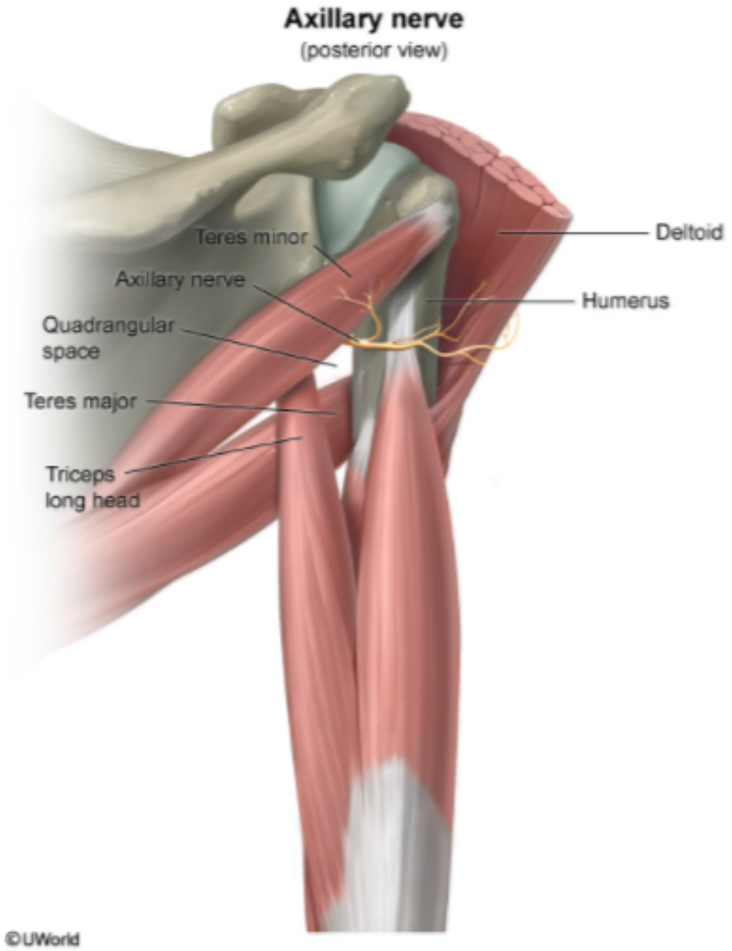

Zoom In | Zoom Out | Reset | Add To New Card | Existing Card

10
11
12
13
14
15
16
17
18
19
20
21
22
23
24
25
26
27
28
29
30
31
32
33
34
35
36
37
38
39
40

scalene muscles and the first rib. The anterior scalene muscle originates from the C3-C6 transverse processes and attaches to the scalene

Exhibit Display

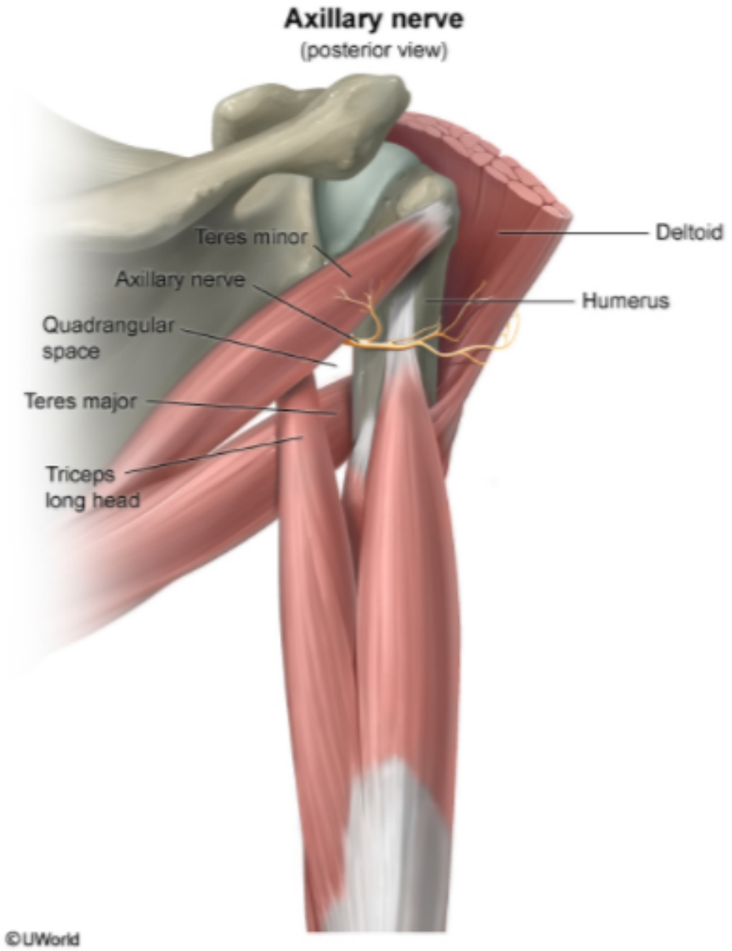

Zoom In | Zoom Out | Reset | Add To New Card | Existing Card

10
11
12
13
14
15
16
17
18
19
20
21
22
23
24
25
26
27
28
29
30
31
32
33
34
35
36
37
38
39
40

10
11
12
13
14
15
16
17
18
19
20
21
22
23
24
25
26
27
28
29
30
31
32
33
34
35
36
37
38
39
40

A 37-year-old woman is brought to the emergency department following a motor vehicle collision. She lost control of her car while going around a corner and struck a brick wall head on. The patient has severe pain at the right hip with any movement. Examination shows that the right lower extremity is adducted and internally rotated and appears shorter than the contralateral leg. Range of motion testing at the hip is limited in all directions due to severe pain. X-ray of the hip is shown in the exhibit. Which of the following structures is most vulnerable to involvement from this patient's injury?

A. Femoral artery

B. Femoral nerve

C. Lateral femoral cutaneous nerve

D. Sciatic nerve

E. Superior gluteal artery

Submit

10
11
12
13
14
15
16
17
18
19
20
21
22
23
24
25
26
27
28
29
30
31
32
33
34
35
36
37
38
39
40

Exhibit Display

Zoom In
Zoom Out
Reset
Add To Flash Card

A 37-year-old woman is brought to the emergency department following a motor vehicle collision. She lost control of her car while going around a corner and struck a brick wall head on. The patient has severe pain at the right hip with any movement. Examination shows that the right lower extremity is adducted and internally rotated and appears shorter than the contralateral leg. Range of motion testing at the hip is limited in all directions due to severe pain. X-ray of the hip is shown in the exhibit. Which of the following structures is most vulnerable to involvement from this patient's injury?

A. Femoral artery (20%)

B. Femoral nerve (16%)

C. Lateral femoral cutaneous nerve (14%)

✓ D. Sciatic nerve (35%)

E. Superior gluteal artery (14%)

Omitted
Correct answer
D

35%
Answered correctly

08 secs
Time Spent

05/08/2020
Last Updated

Explanation

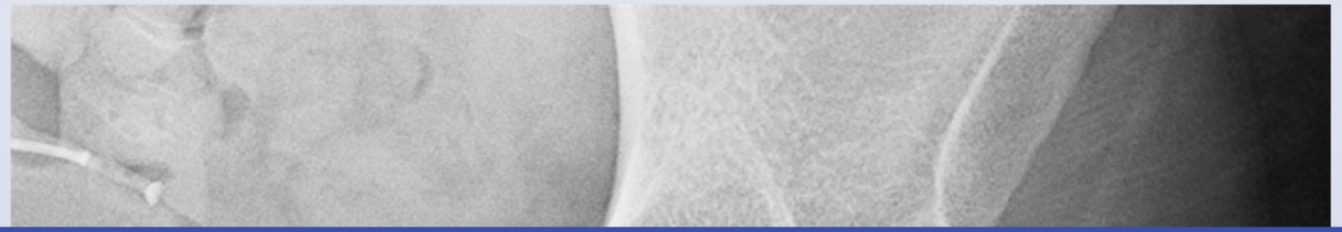

10
11
12
13
14
15
16
17
18
19
20
21
22
23
24
25
26
27
28
29
30
31
32
33
34
35
36
37
38
39
40

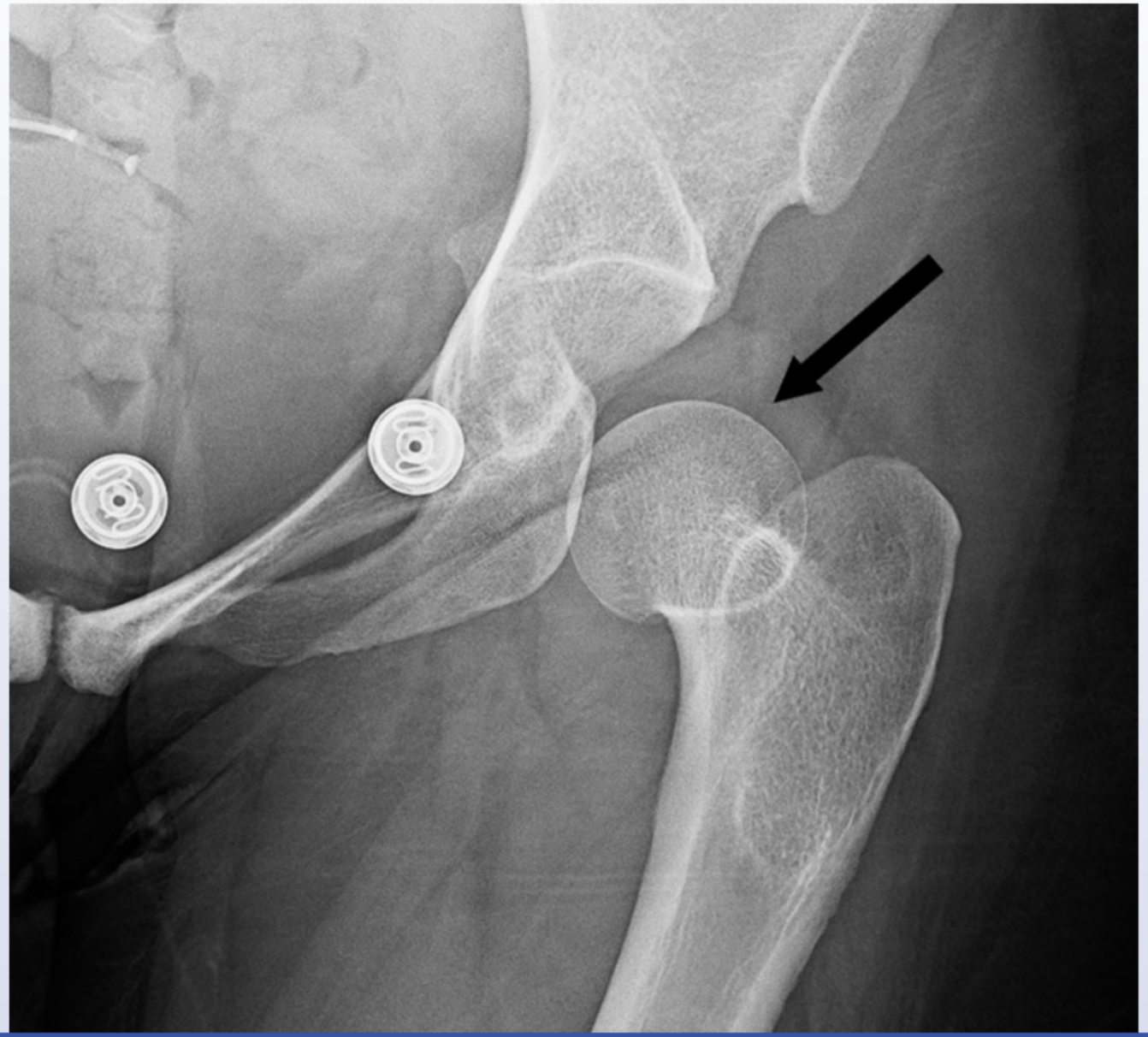

10
11
12
13
14
15
16
17
18
19
20
21
22
23
24
25
26
27
28
29
30
31
32
33
34
35
36
37
38
39
40

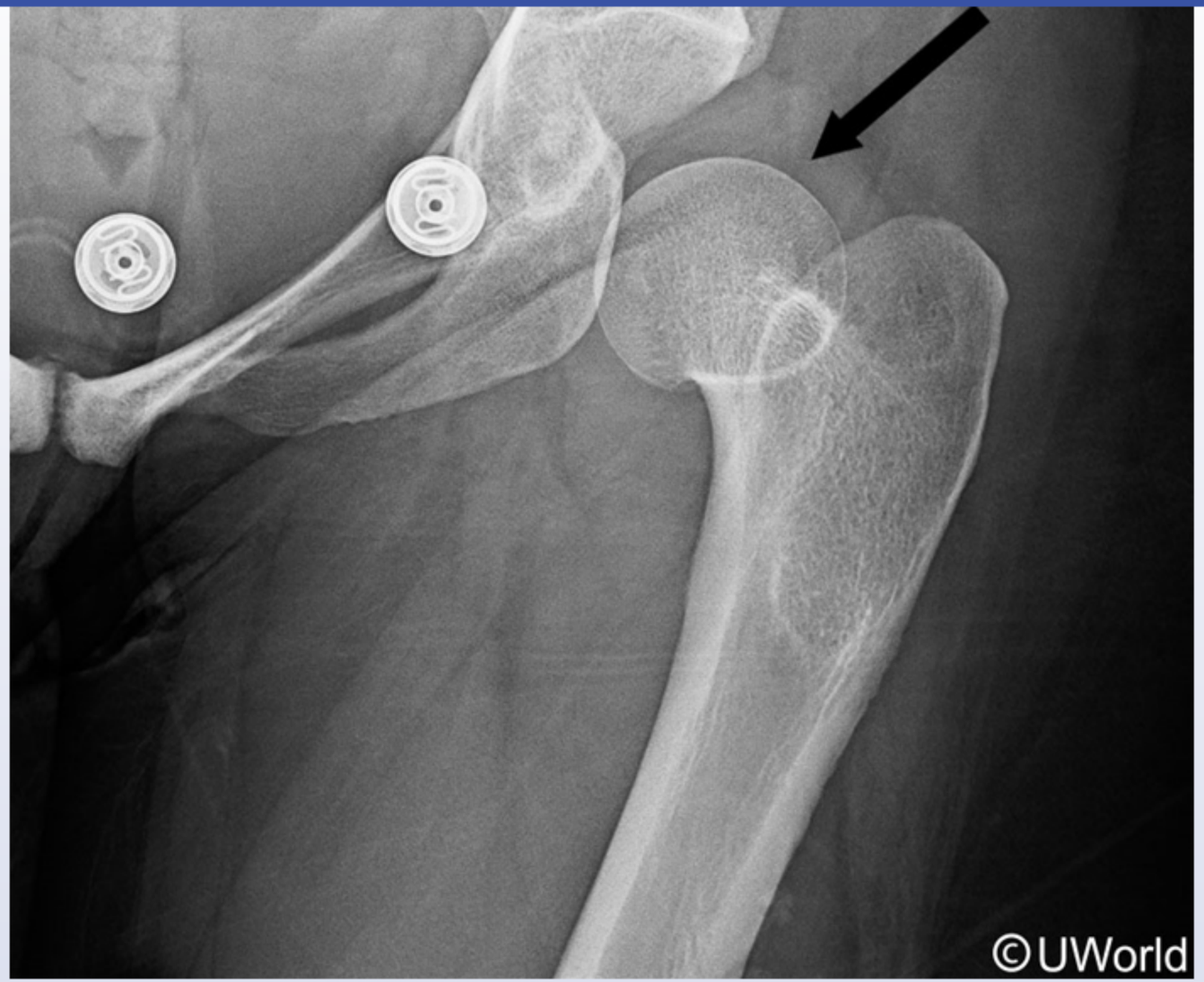

This patient has a **posterior hip dislocation** (ie, femoral head displaced posteriorly from the acetabulum), which commonly occurs in head-on motor vehicle collisions in which the knee strikes the dashboard or from a fall in frail, elderly patients. The risk is increased with prosthetic joints.

10
11
12
13
14
15
16
17
18
19
20
21
22
23
24
25
26
27
28
29
30
31
32
33
34
35
36
37
38
39
40

This patient has a **posterior hip dislocation** (ie, femoral head displaced posteriorly from the acetabulum), which commonly occurs in head-on motor vehicle collisions in which the knee strikes the dashboard or from a fall in frail, elderly patients. The risk is increased with prosthetic joints.

On examination, the leg with a posterior hip dislocation appears **shortened** and **internally rotated**, with the hip held in **flexion and adduction**. Range of motion is limited and painful. Posterior dislocation can be mistaken for intertrochanteric hip fracture, which can also present with leg shortening; however, the leg is typically rotated externally with intertrochanteric fracture due to contraction of the psoas and iliacus without the normal acetabular counterforce.

The sciatic nerve runs **posterior to the hip joint** and is vulnerable to injury with posterior hip dislocation. Findings of sciatic injury include **weakness of ankle dorsiflexion**, decreased ankle reflex, and decreased sensation in the distribution of the nerve.

(Choices A and B) The femoral artery runs anterior to the hip and can be injured in anterior (not posterior) dislocation, which is rare and typically occurs in association with additional traumatic injuries (eg, hip fracture); examination shows abduction and external rotation of the thigh. The femoral nerve also runs anterior to the hip joint; it is occasionally injured in hip arthroplasty but is not at risk in posterior dislocation.

(Choice C) The lateral femoral cutaneous nerve passes under the inguinal ligament into the lateral thigh; it is vulnerable to external compression but is not at risk in hip dislocation.

(Choice E) The superior gluteal artery arises from the internal iliac artery in the posterior pelvis and can be injured in pelvic fracture. It does not approximate the hip joint and is not vulnerable in posterior dislocation.

Educational objective:
Posterior hip dislocation (ie, femoral head displaced posteriorly from the acetabulum) can occur in motor vehicle collisions in which the knee strikes the dashboard or from falls in elderly patients. On examination, the leg appears shortened and internally rotated, with the hip held in flexion and adduction. The sciatic nerve is vulnerable to injury in posterior hip dislocation.

Anatomy	Rheumatology/Orthopedics & Sports	Hip fracture
Subject	System	Topic

Copyright © UWorld. All rights reserved.

10
11
12
13
14
15
16
17
18
19
20
21
22
23
24
25
26
27
28
29
30
31
32
33
34
35
36
37
38
39
40

Exhibit Display

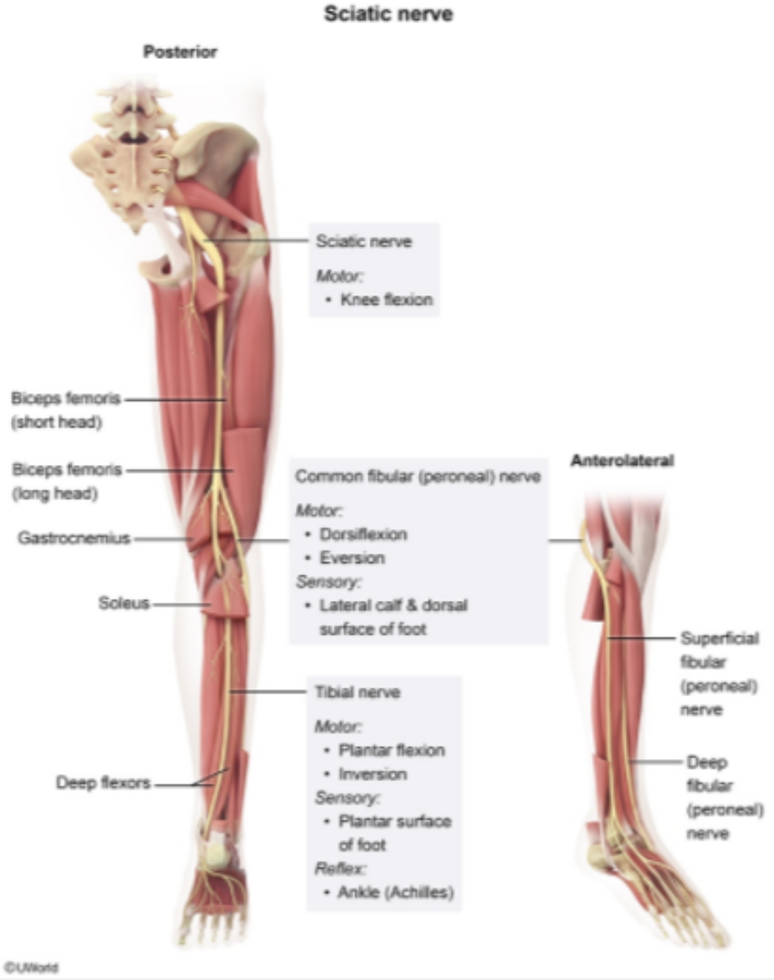

Zoom In Zoom Out Reset Add To Flash Card

10
11
12
13
14
15
16
17
18
19
20
21
22
23
24
25
26
27
28
29
30
31
32
33
34
35
36
37
38
39
40

Exhibit Display

Sciatic nerve

Motor function	Cutaneous innervation
Leg flexion at the knee (see also tibial & peroneal nerves)	

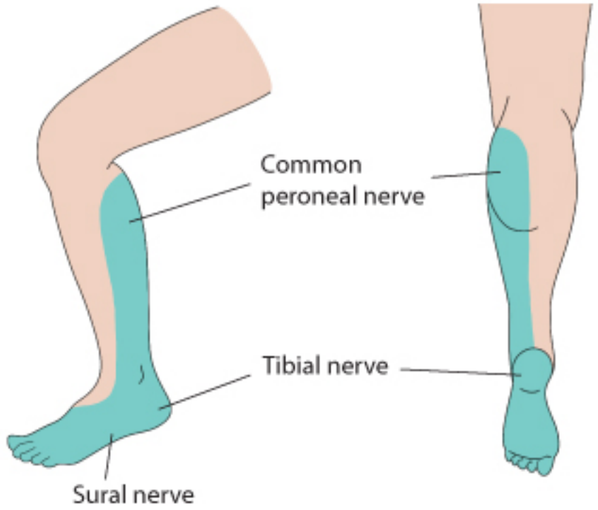

©UWorld

Zoom In Zoom Out Reset Add To Flash Card

10
11
12
13
14
15
16
17
18
19
20
21
22
23
24
25
26
27
28
29
30
31
32
33
34
35
36
37
38
39
40

Exhibit Display

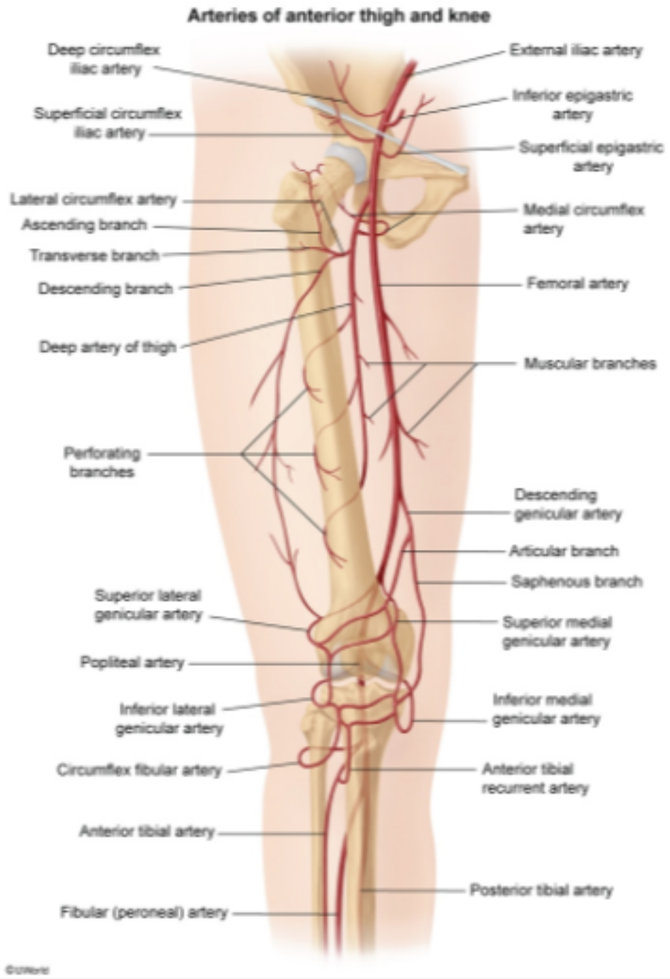

Zoom In Zoom Out Reset Add To Flash Card

10
11
12
13
14
15
16
17
18
19
20
21
22
23
24
25
26
27
28
29
30
31
32
33
34
35
36
37
38
39
40

Exhibit Display

Femoral triangle

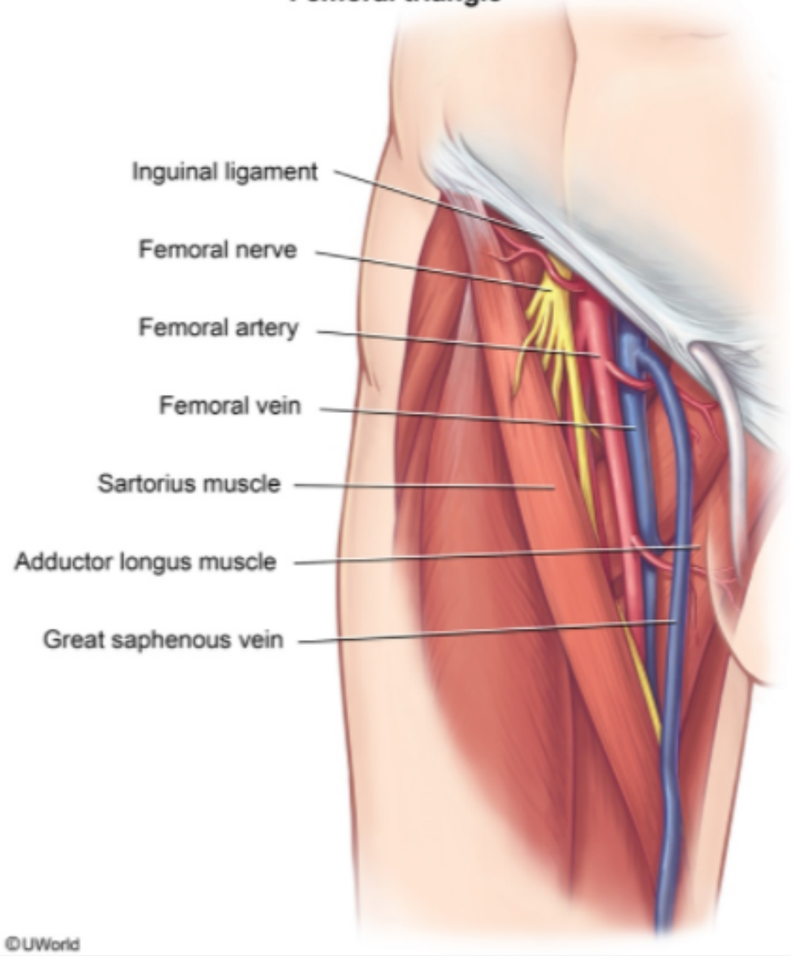

Zoom In
Zoom Out
Reset
Add To Flash Card

10
11
12
13
14
15
16
17
18
19
20
21
22
23
24
25
26
27
28
29
30
31
32
33
34
35
36
37
38
39
40

Exhibit Display

Lateral femoral cutaneous nerve & meralgia paresthetica

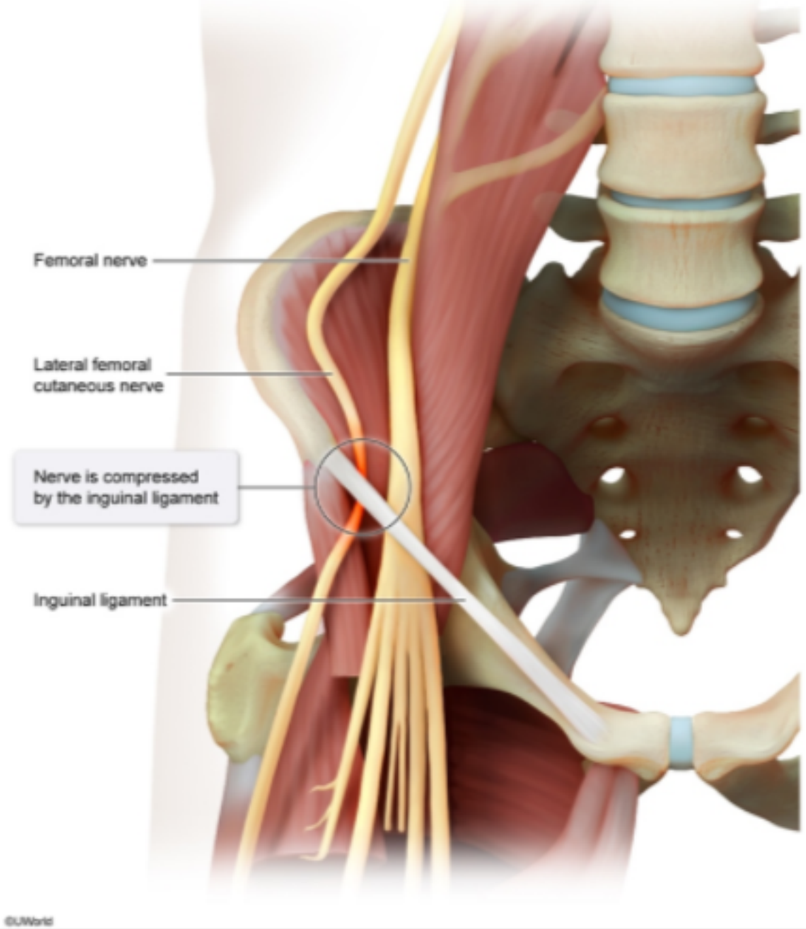

Zoom In
Zoom Out
Reset
Add To Flash Card

10
11
12
13
14
15
16
17
18
19
20
21
22
23
24
25
26
27
28
29
30
31
32
33
34
35
36
37
38
39
40

Exhibit Display

Branches of common iliac artery

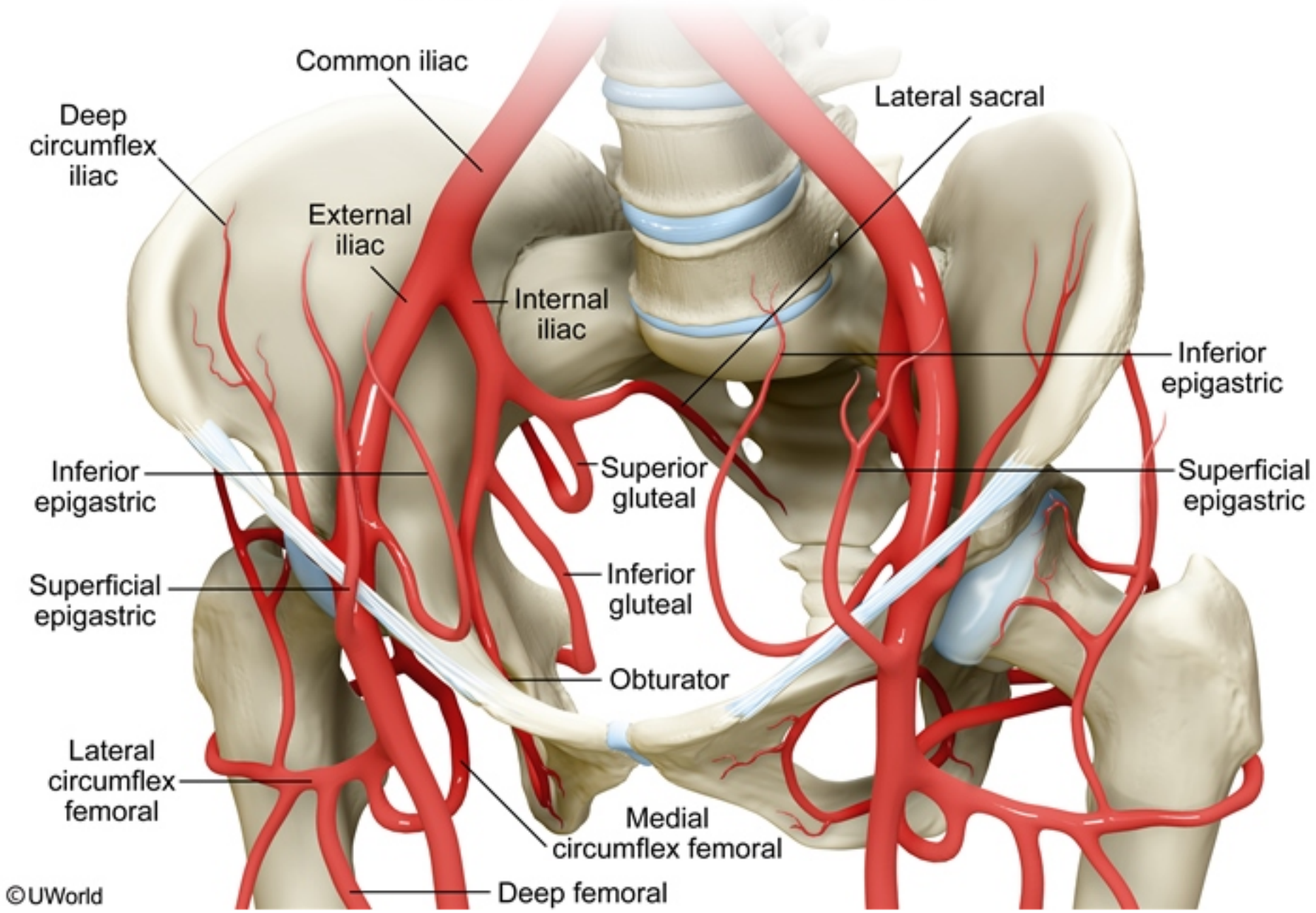

Zoom In Zoom Out Reset Add To Flash Card

10
11
12
13
14
15
16
17
18
19
20
21
22
23
24
25
26
27
28
29
30
31
32
33
34
35
36
37
38
39
40

A 3-year-old boy is brought to the emergency department for refusal to move his right arm. This afternoon, he tripped while holding hands with his sister, who pulled up on his arm to prevent him from falling. The patient immediately began to cry and has since refused to move the arm. On physical examination, he holds the right arm against his abdomen with the elbow flexed and forearm pronated. The patient cries with any attempted manipulation of the right elbow. There is no visible swelling or deformity. Which of the following structures is most likely affected in this patient's condition?

A. Annular ligament

B. Biceps tendon

C. Interosseous membrane

D. Radial collateral ligament

E. Ulnar collateral ligament

Submit

A 3-year-old boy is brought to the emergency department for refusal to move his right arm. This afternoon, he tripped while holding hands with his sister, who pulled up on his arm to prevent him from falling. The patient immediately began to cry and has since refused to move the arm. On physical examination, he holds the right arm against his abdomen with the elbow flexed and forearm pronated. The patient cries with any attempted manipulation of the right elbow. There is no visible swelling or deformity. Which of the following structures is most likely affected in this patient's condition?

- ✓ A. Annular ligament (62%)
- B. Biceps tendon (8%)
- C. Interosseous membrane (2%)
- D. Radial collateral ligament (17%)
- E. Ulnar collateral ligament (8%)

Omitted
Correct answer
A

62%
Answered correctly

02 secs
Time Spent

03/03/2020
Last Updated

Explanation

Radial head subluxation (nursemaid's elbow)

Normal → **Traction** → **Annular ligament displacement**

10
11
12
13
14
15
16
17
18
19
20
21
22
23
24
25
26
27
28
29
30
31
32
33
34
35
36
37
38
39
40

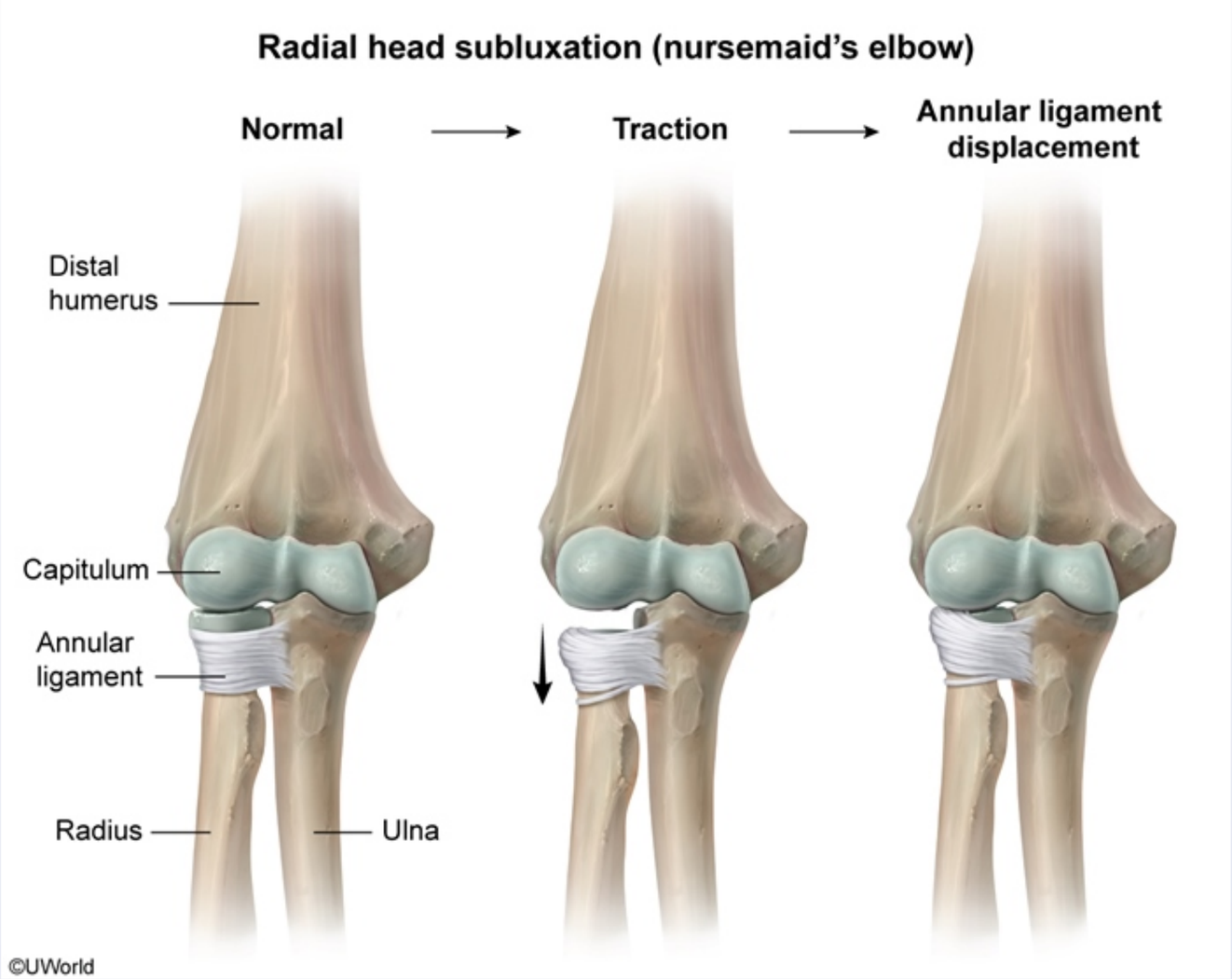

This patient's mechanism of injury (eg, sudden pulling up on the arm) and presentation (eg, holding the arm flexed and pronated, pain with movement) are consistent with **radial head subluxation** (ie, nursemaid's elbow).

The radial head is anchored to the ulna by the **annular ligament**, which encircles the proximal radius. In children age <5, this tissue is relatively

This patient's mechanism of injury (eg, sudden pulling up on the arm) and presentation (eg, holding the arm flexed and pronated, pain with movement) are consistent with **radial head subluxation** (ie, nursemaid's elbow).

The radial head is anchored to the ulna by the **annular ligament**, which encircles the proximal radius. In children age <5, this tissue is relatively thin compared to older children and adults. Sudden **axial traction** (eg, pulling up on the arm by the hand) or twisting can cause the annular ligament to slip over the radial head and become **entrapped** in the radiohumeral joint.

Patients classically hold the affected arm close to the body with the **elbow flexed** and the **forearm pronated**. There is significant pain with movement or manipulation of the joint but typically no obvious swelling or deformity. Reduction can usually be accomplished either by hyperpronation of the forearm or supination of the forearm with flexion of the elbow.

(Choice B) A distal biceps tendon rupture characteristically occurs in older patients after forceful extension of the elbow while the biceps muscle is contracted, resulting in a visible mass in the mid-upper arm (ie, "Popeye" deformity).

(Choice C) The interosseous membrane is a broad sheet of connective tissue between the radius and ulna that provides forearm stability and a point of attachment for the forearm muscles. Injury to the membrane is associated with fracture of the radius or ulna after a fall onto an outstretched hand.

(Choice D) Injury to the radial (lateral) collateral ligament of the elbow can occur with acute varus stress during a fall onto an outstretched hand and is often associated with fracture or dislocation of the elbow.

(Choice E) The ulnar (medial) collateral ligament is typically injured by intense, repetitive overuse involving a valgus stress at the elbow (eg, pitching a baseball), resulting in medial elbow pain that increases during throwing motions.

Educational objective:
Radial head subluxation (ie, nursemaid's elbow) is the displacement of the annular ligament into the radiohumeral joint, classically resulting from sudden axial traction (eg, pulling) on the arm of a child age <5. Although most patients do not have any obvious swelling or deformity, they avoid moving the arm due to pain and hold it with the elbow flexed and forearm pronated.

References

- Common paediatric elbow injuries.

ligament to slip over the radial head and become **entrapped** in the radiohumeral joint.

Patients classically hold the affected arm close to the body with the **elbow flexed** and the **forearm pronated**. There is significant pain with movement or manipulation of the joint but typically no obvious swelling or deformity. Reduction can usually be accomplished either by hyperpronation of the forearm or supination of the forearm with flexion of the elbow.

(Choice B) A distal biceps tendon rupture characteristically occurs in older patients after forceful extension of the elbow while the biceps muscle is contracted, resulting in a visible mass in the mid-upper arm (ie, "Popeye" deformity).

(Choice C) The interosseous membrane is a broad sheet of connective tissue between the radius and ulna that provides forearm stability and a point of attachment for the forearm muscles. Injury to the membrane is associated with fracture of the radius or ulna after a fall onto an outstretched hand.

(Choice D) Injury to the radial (lateral) collateral ligament of the elbow can occur with acute varus stress during a fall onto an outstretched hand and is often associated with fracture or dislocation of the elbow.

(Choice E) The ulnar (medial) collateral ligament is typically injured by intense, repetitive overuse involving a valgus stress at the elbow (eg, pitching a baseball), resulting in medial elbow pain that increases during throwing motions.

Educational objective:
Radial head subluxation (ie, nursemaid's elbow) is the displacement of the annular ligament into the radiohumeral joint, classically resulting from sudden axial traction (eg, pulling) on the arm of a child age <5. Although most patients do not have any obvious swelling or deformity, they avoid moving the arm due to pain and hold it with the elbow flexed and forearm pronated.

References

- Common paediatric elbow injuries.

Anatomy	Rheumatology/Orthopedics & Sports	Radial head subluxation
Subject	System	Topic

Copyright © UWorld. All rights reserved.

10
11
12
13
14
15
16
17
18
19
20
21
22
23
24
25
26
27
28
29
30
31
32
33
34
35
36
37
38
39
40

Exhibit Display

Nursemaid's elbow reduction maneuvers Nursemaid's elbow reduction maneuvers

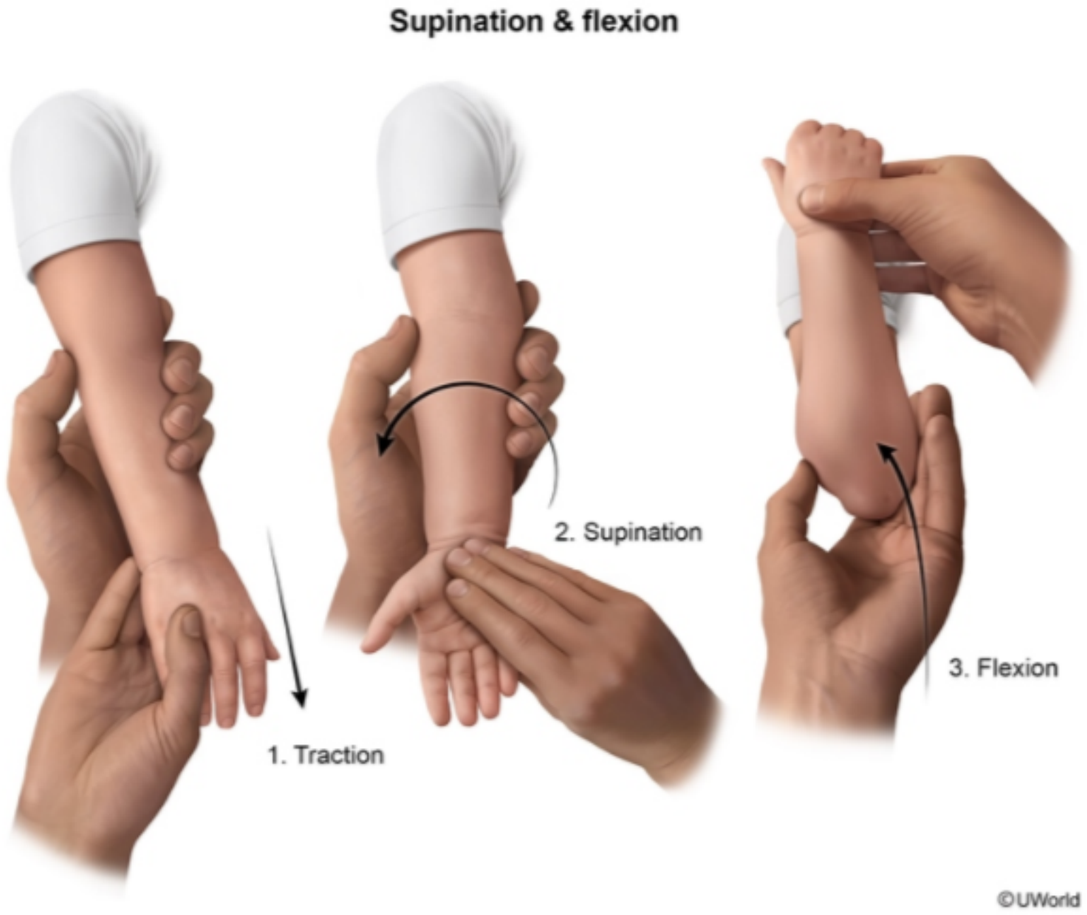

Zoom In Zoom Out Reset Add To New Card | Existing Card

Radial head subluxation (ie, nursemaid's elbow) is the displacement of the annular ligament into the radiohumeral joint, classically resulting from

10
11
12
13
14
15
16
17
18
19
20
21
22
23
24
25
26
27
28
29
30
31
32
33
34
35
36
37
38
39
40

Exhibit Display

Nursemaid's elbow reduction maneuvers Nursemaid's elbow reduction maneuvers

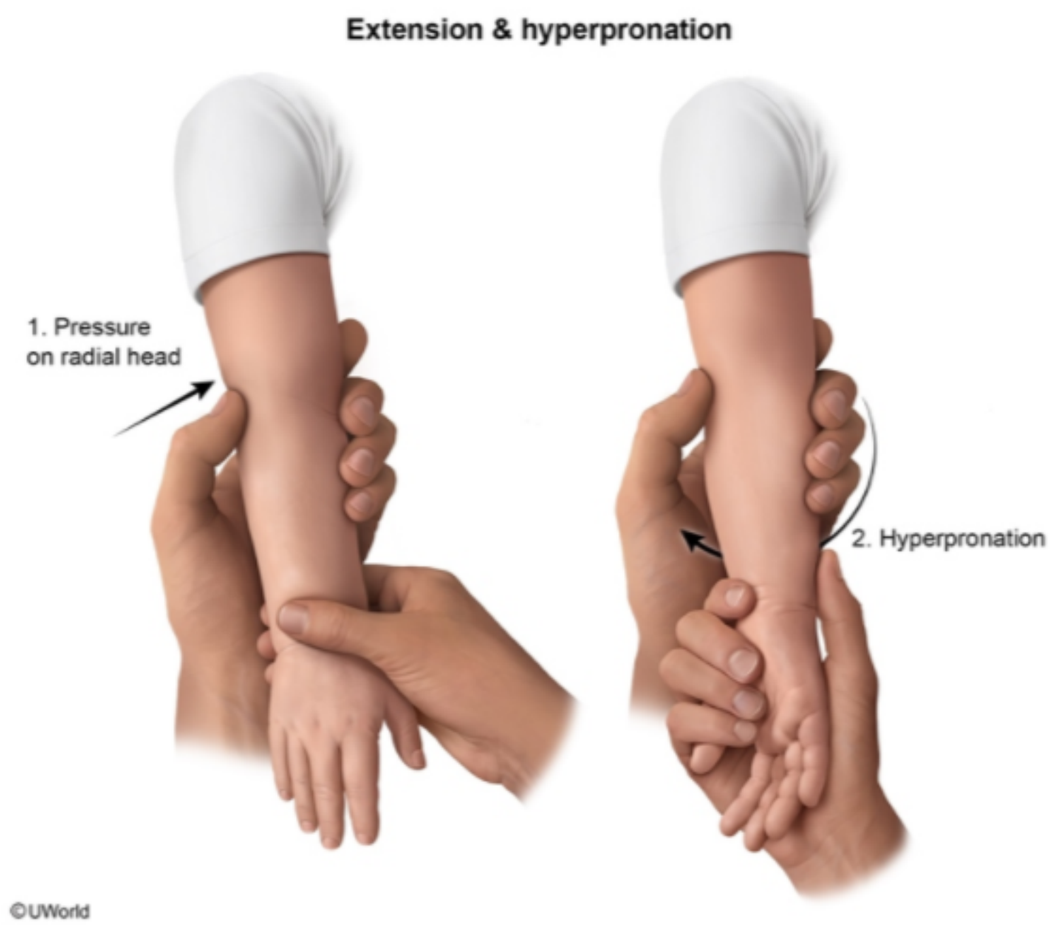

Zoom In Zoom Out Reset Add To New Card | Existing Card

Radial head subluxation (ie, nursemaid's elbow) is the displacement of the annular ligament into the radiohumeral joint, classically resulting from

10
11
12
13
14
15
16
17
18
19
20
21
22
23
24
25
26
27
28
29
30
31
32
33
34
35
36
37
38
39
40

A 20-year-old man comes to the hospital with knee pain after he tripped and landed on his right knee during a soccer game. The anterior portion of his tibia impacted directly against the ground, and he has been unable to bear weight since the injury. On physical examination, the patient's knee appears swollen, and there is excessive posterior displacement of the tibia when pressure is applied to his anterior tibia with the knee in the flexed position. An axial MRI cross section of the right knee at the level of the tibial plateau is shown below. Which of the following structures is most likely injured in this patient?

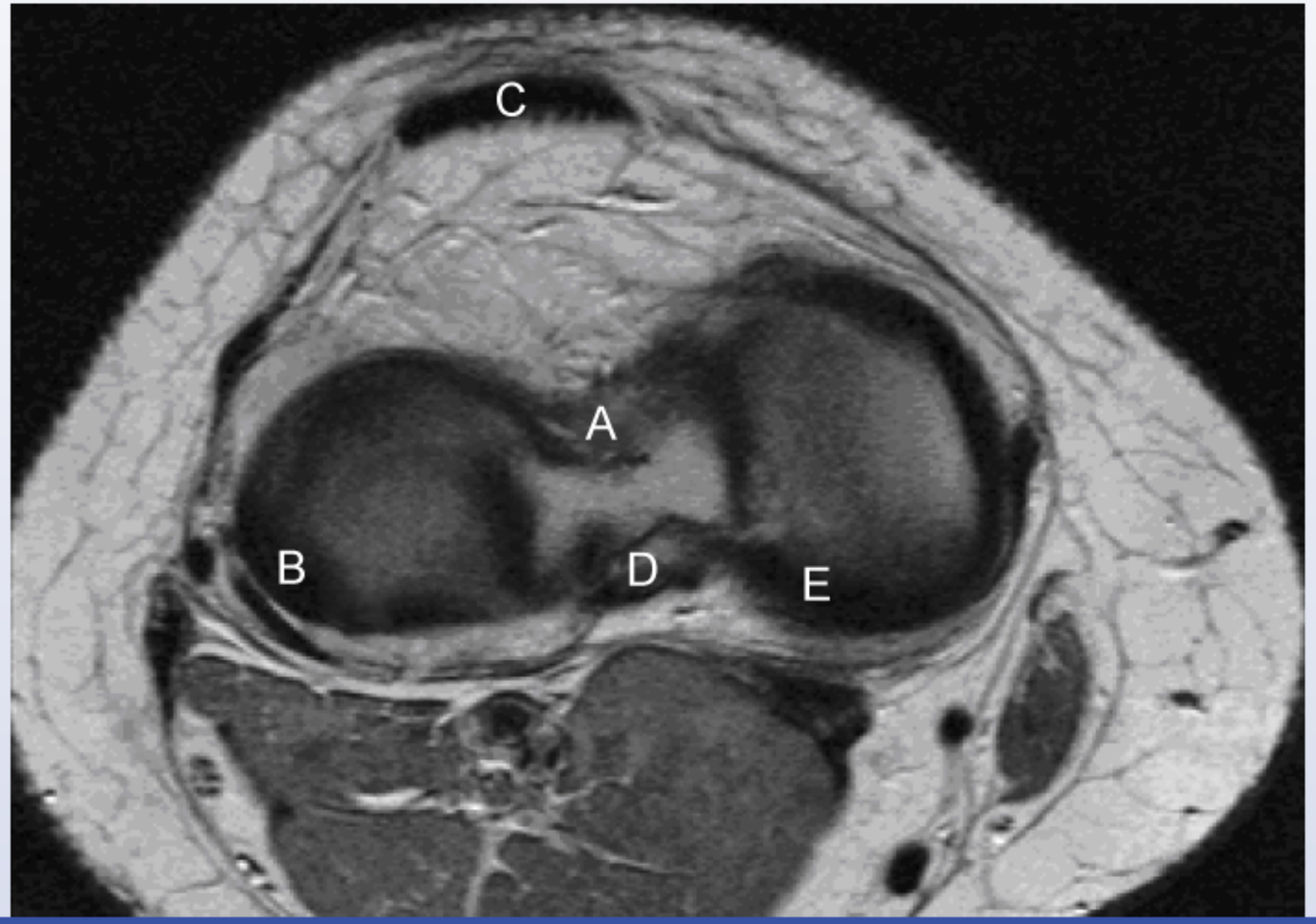

10
11
12
13
14
15
16
17
18
19
20
21
22
23
24
25
26
27
28
29
30
31
32
33
34
35
36
37
38
39
40

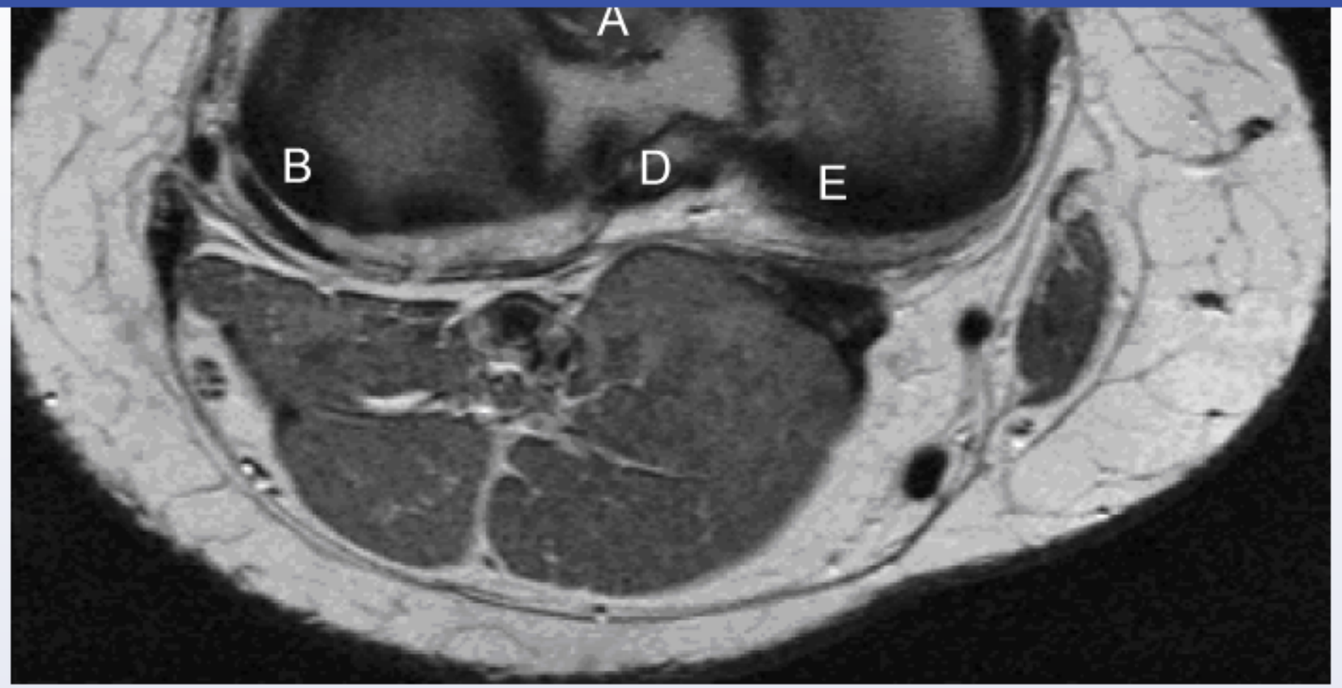

A. A

B. B

C. C

D. D

E. E

Submit

10
11
12
13
14
15
16
17
18
19
20
21
22
23
24
25
26
27
28
29
30
31
32
33
34
35
36
37
38
39
40

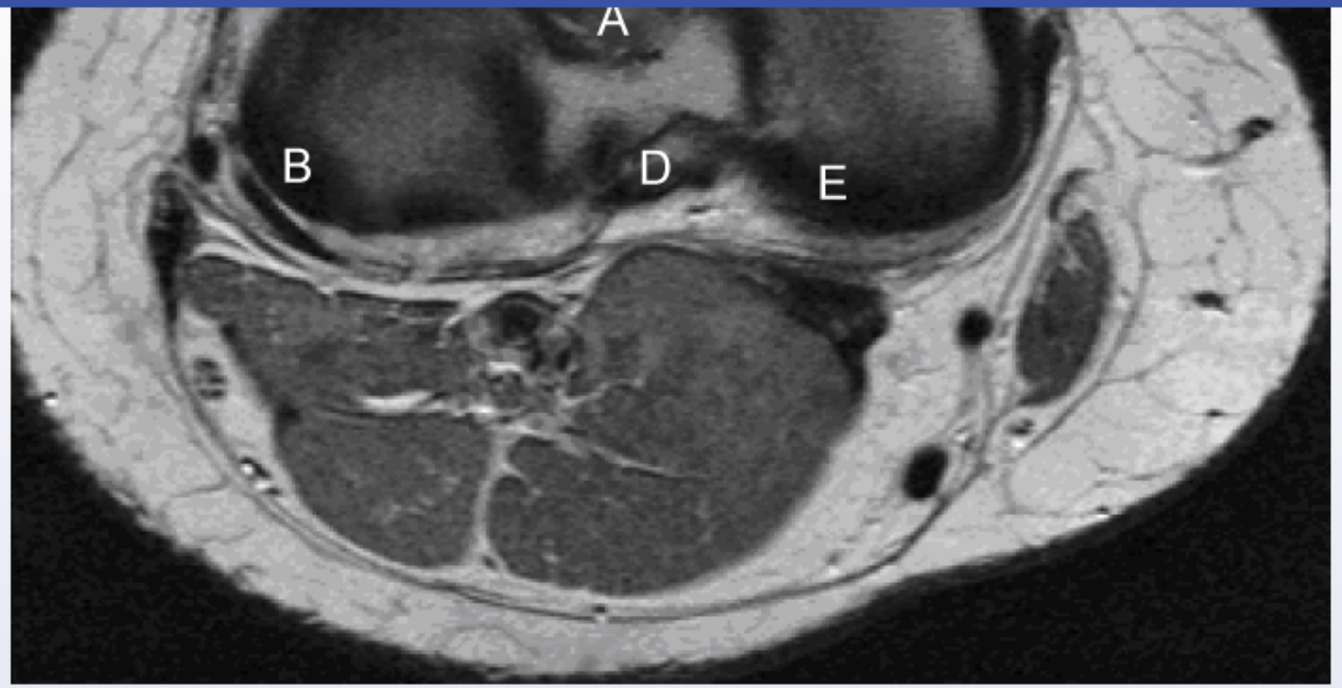

A. A (16%)

B. B (1%)

C. C (1%)

✓ D. D (77%)

E. E (2%)

Omitted
Correct answer

77%
Answered correctly

05 secs
Time Spent

02/06/2020
Last Updated

10
11
12
13
14
15
16
17
18
19
20
21
22
23
24
25
26
27
28
29
30
31
32
33
34
35
36
37
38
39
40

Knee MRI

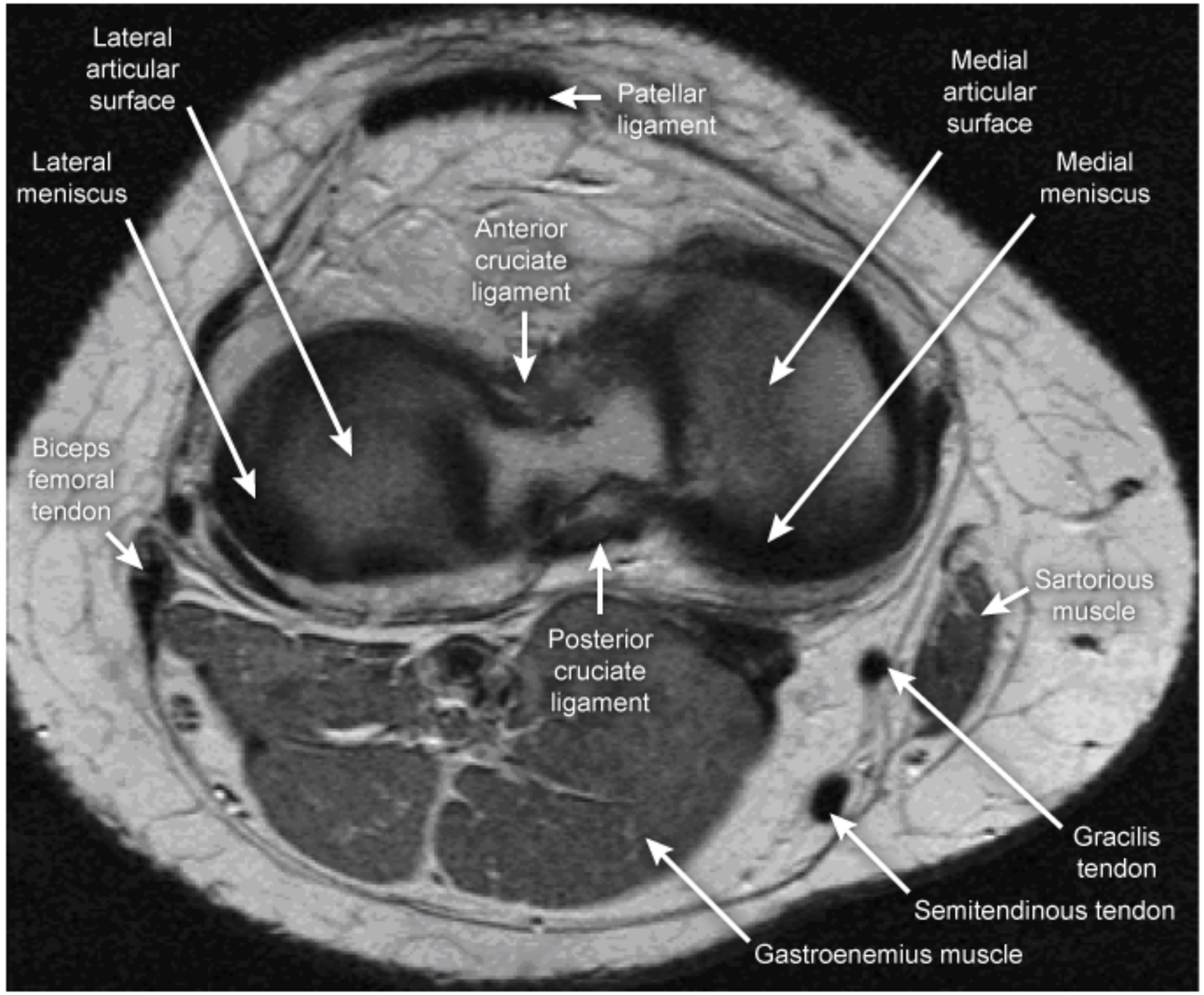

©UWorld

10
11
12
13
14
15
16
17
18
19
20
21
22
23
24
25
26
27
28
29
30
31
32
33
34
35
36
37
38
39
40

©UWorld

The **anterior cruciate ligament** (ACL) and the **posterior cruciate ligament** (PCL) are found within the articular capsule of the knee joint and cross one another as they span from the femur to the tibia. The PCL originates from the anterolateral surface of the medial femoral condyle and inserts into the posterior intercondylar area of the tibia. At the level of the tibial plateau (as seen on the axial MRI above), the ACL is anterior, and the PCL is posterior. The ACL functions to resist anterior displacement of the tibia relative to the femur **(Choice A)**.

The PCL prevents **posterior displacement** of the tibia relative to the femur, and its integrity can be tested by using the **posterior drawer test** (posterior force applied to the tibia while the knee is flexed). PCL tears most commonly occur following a direct blow to the anterior proximal tibia during sporting activities or motor vehicle collisions.

(Choices B and E) The medial and lateral menisci are crescent-shaped bands of cartilaginous tissue that line the periphery of the knee joint. Meniscal tears are associated with twisting of a flexed knee while the corresponding foot is planted. Meniscal damage can be detected on physical examination by joint-line tenderness during provocative maneuvers (eg, McMurray test).

(Choice C) The patellar ligament (ie, patellar tendon) connects the inferior portion of the patella to the tibial tuberosity. Patellar ligament rupture is associated with underlying ligamentous damage (eg, autoimmune disease, overuse injury) and usually occurs following forceful contraction of the quadriceps muscles while the knee is flexed (eg, landing after a jump). A complete patellar ligament tear would result in swelling and a high-riding patella on physical examination.

Educational objective:
The posterior cruciate ligament prevents posterior displacement of the tibia relative to the femur. It originates from the anterolateral surface of the medial femoral condyle and inserts into the posterior intercondylar area of the tibia. Its integrity can be tested in the clinical setting by using the posterior drawer test.

Anatomy	Rheumatology/Orthopedics & Sports	Knee trauma
Subject	System	Topic

Copyright © UWorld. All rights reserved.

Gastroenemius muscle

Exhibit Display

Anterior cruciate ligament

Posterior cruciate ligament

©UWorld

Zoom In | Zoom Out | Reset | Add To New Card | Existing Card

Gastroenemius muscle

Exhibit Display

Axial CT/MRI orientation

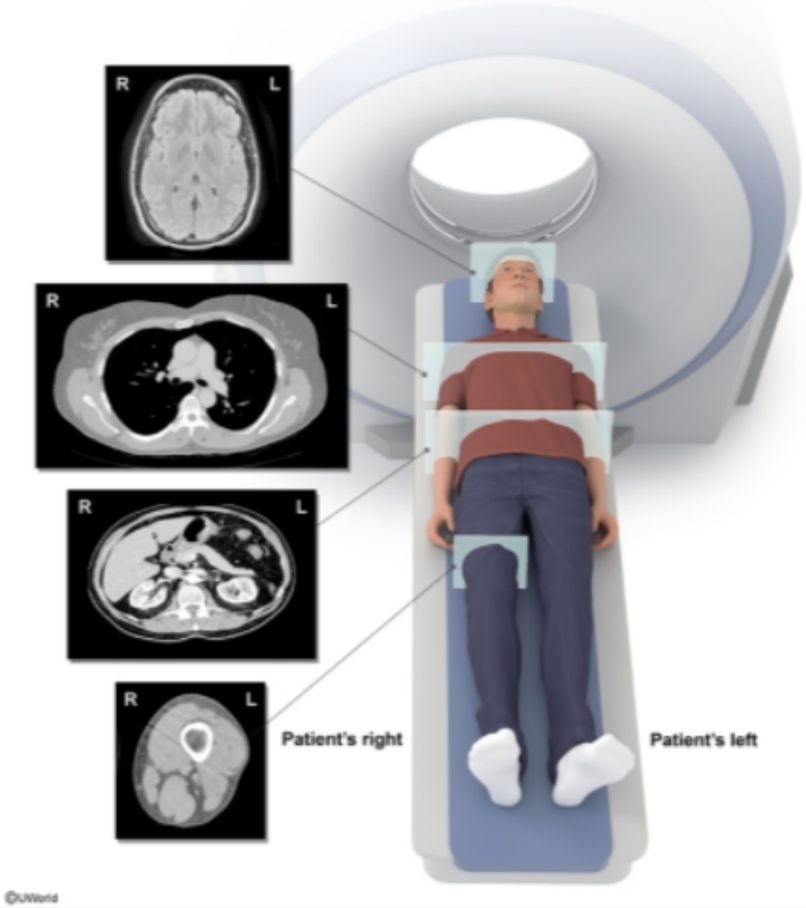

Zoom In | Zoom Out | Reset | Add To New Card | Existing Card

Gastroenemius muscle

Exhibit Display

Axial CT/MRI orientation

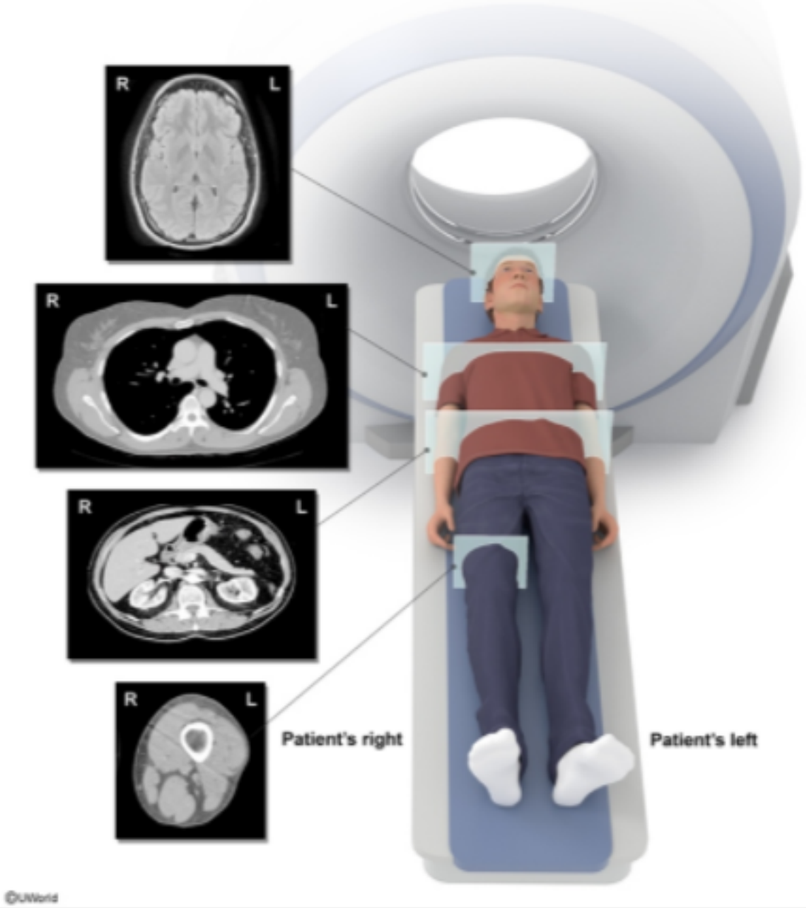

Zoom In | Zoom Out | Reset | Add To New Card | Existing Card

Gastroenemius muscle

Exhibit Display

Posterior cruciate ligament tear

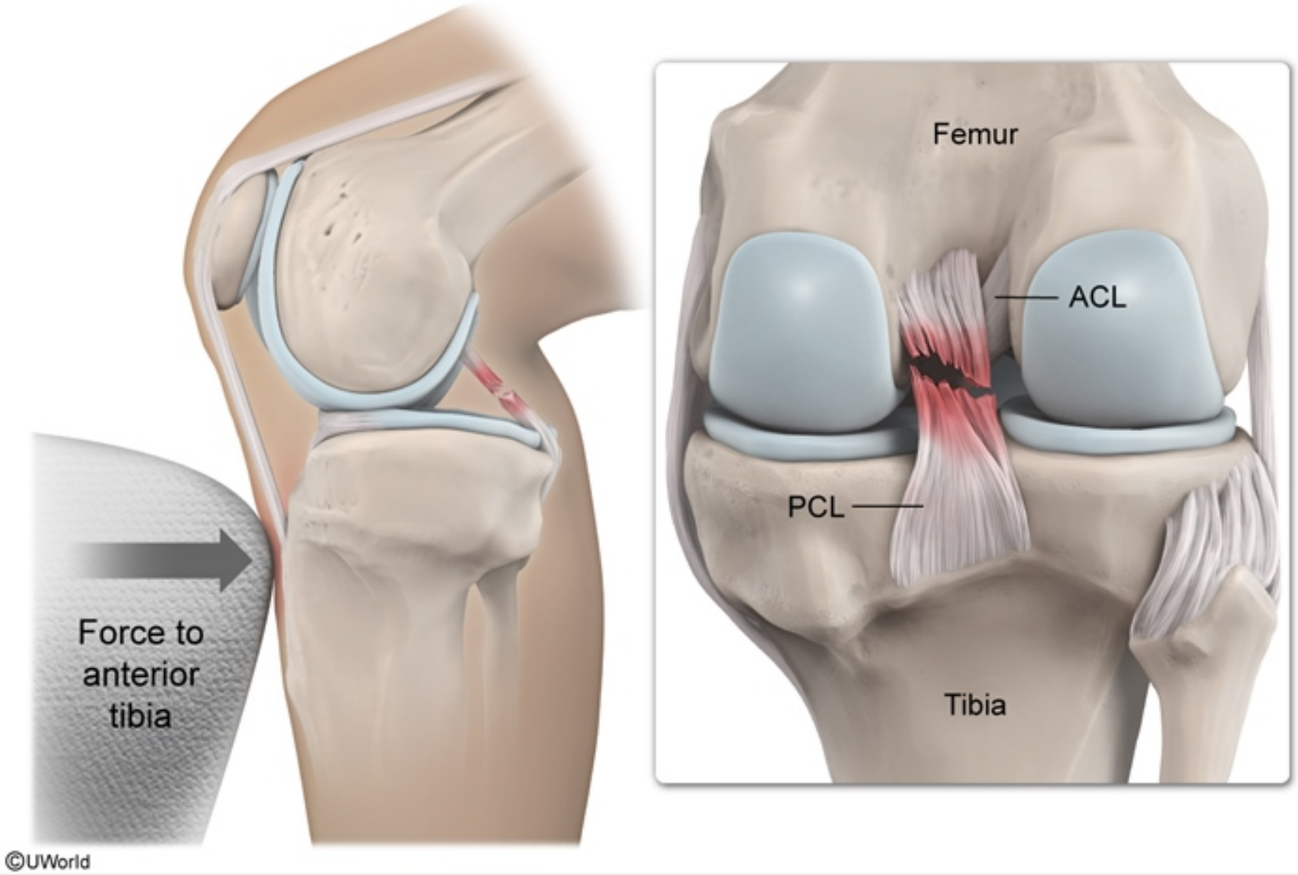

Zoom In | Zoom Out | Reset | Add To New Card | Existing Card

10
11
12
13
14
15
16
17
18
19
20
21
22
23
24
25
26
27
28
29
30
31
32
33
34
35
36
37
38
39
40

Gastroenemius muscle

Exhibit Display

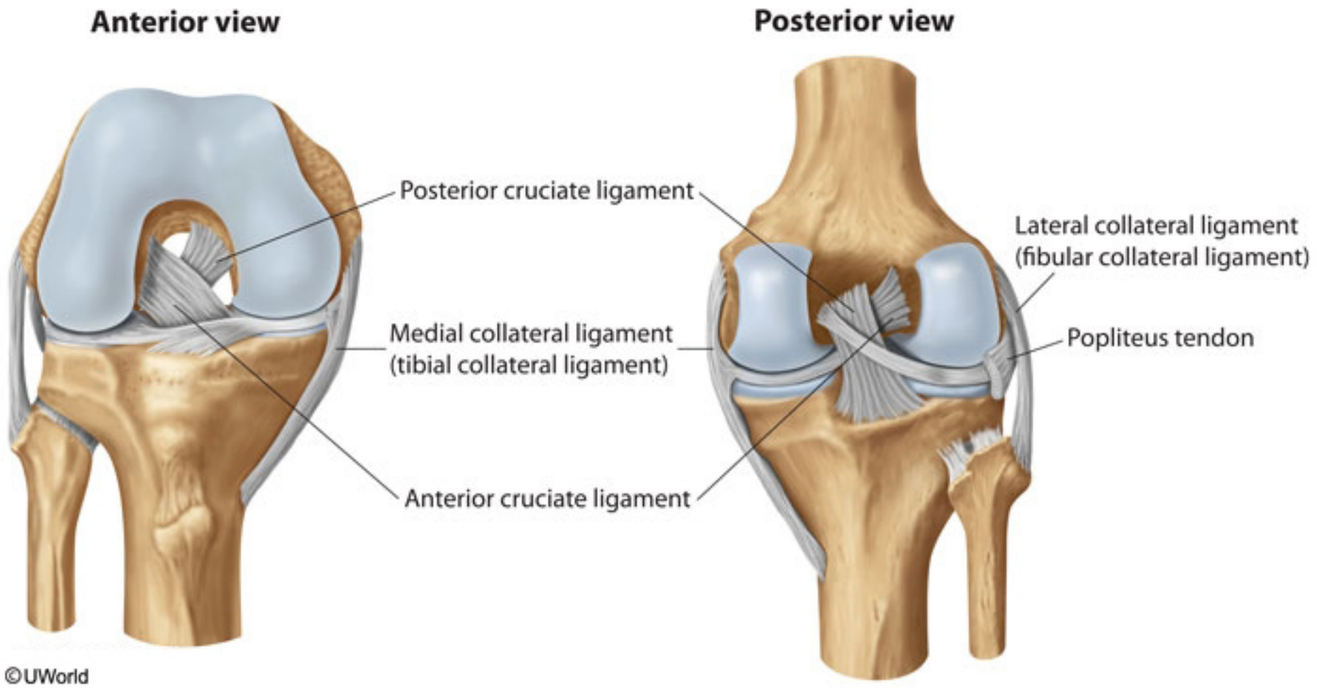

Zoom In | Zoom Out | Reset | Add To New Card | Existing Card

Gastroenemius muscle

Exhibit Display

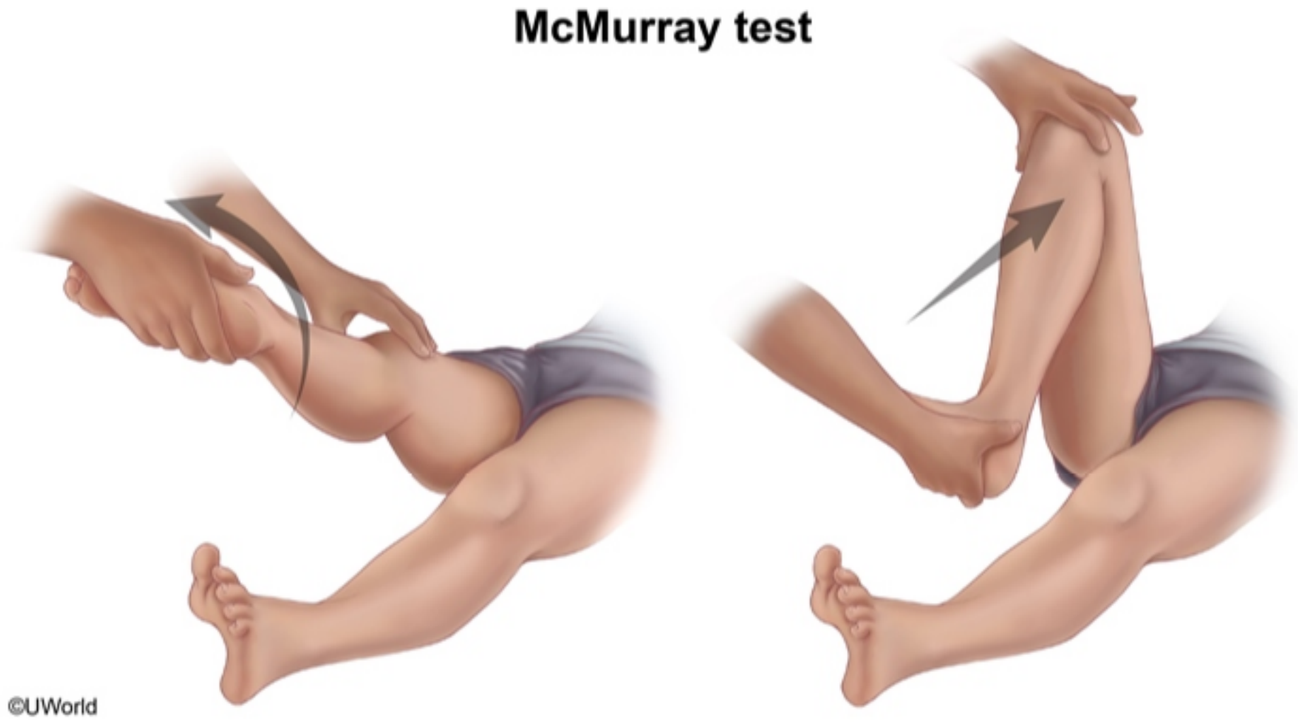

Zoom In | Zoom Out | Reset | Add To New Card | Existing Card

10
11
12
13
14
15
16
17
18
19
20
21
22
23
24
25
26
27
28
29
30
31
32
33
34
35
36
37
38
39
40

A 36-year-old construction worker comes to the emergency department after falling 3 meters (~10 ft) from a ladder. The patient braced his fall with outstretched hands and experienced severe pain in the left wrist immediately on impacting the ground. On examination, the left wrist is swollen, with no lacerations. A strong radial pulse is present, and the fingers are well perfused. There is a palpable mass just proximal to the left palm. X-ray of the left wrist reveals a lunate dislocation without evidence of a distal radius fracture, as seen in the exhibit. The patient is at greatest risk for impairment of which of the following hand functions?

A. Finger abduction

B. Finger interphalangeal joint flexion

C. Thumb abduction

D. Thumb adduction

E. Thumb extension

Submit

A 36-year-old construction worker comes to the emergency department after falling 3 meters (~10 ft) from a ladder. The patient braced his fall with outstretched hands and experienced severe pain in the left wrist immediately on impacting the ground. On examination, the left wrist is swollen, with no lacerations. A strong radial pulse is present, and the fingers are well perfused. There is a palpable mass just proximal to the left palm. X-ray of the left wrist reveals a lunate dislocation without evidence of a distal radius fracture, as seen in the exhibit. The patient is at greatest risk for impairment of which of the following hand functions?

- A. Finger abduction (9%)
- B. Finger interphalangeal joint flexion (17%)
- ✓ C. Thumb abduction (41%)
- D. Thumb adduction (23%)
- E. Thumb extension (8%)

Omitted
Correct answer
C

41%
Answered correctly

02 secs
Time Spent

03/27/2020
Last Updated

Explanation

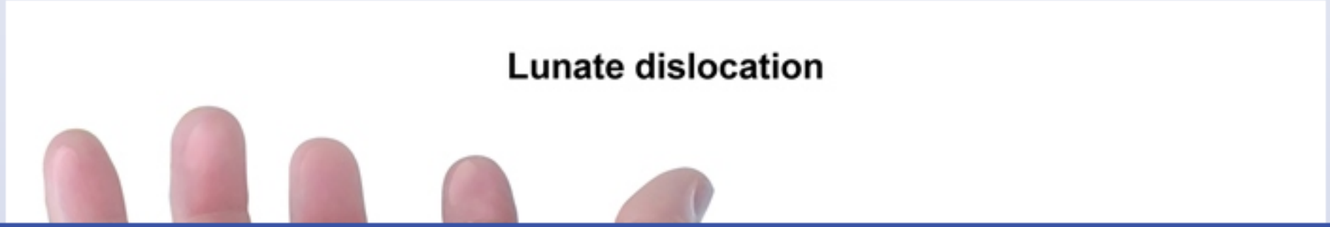

Explanation

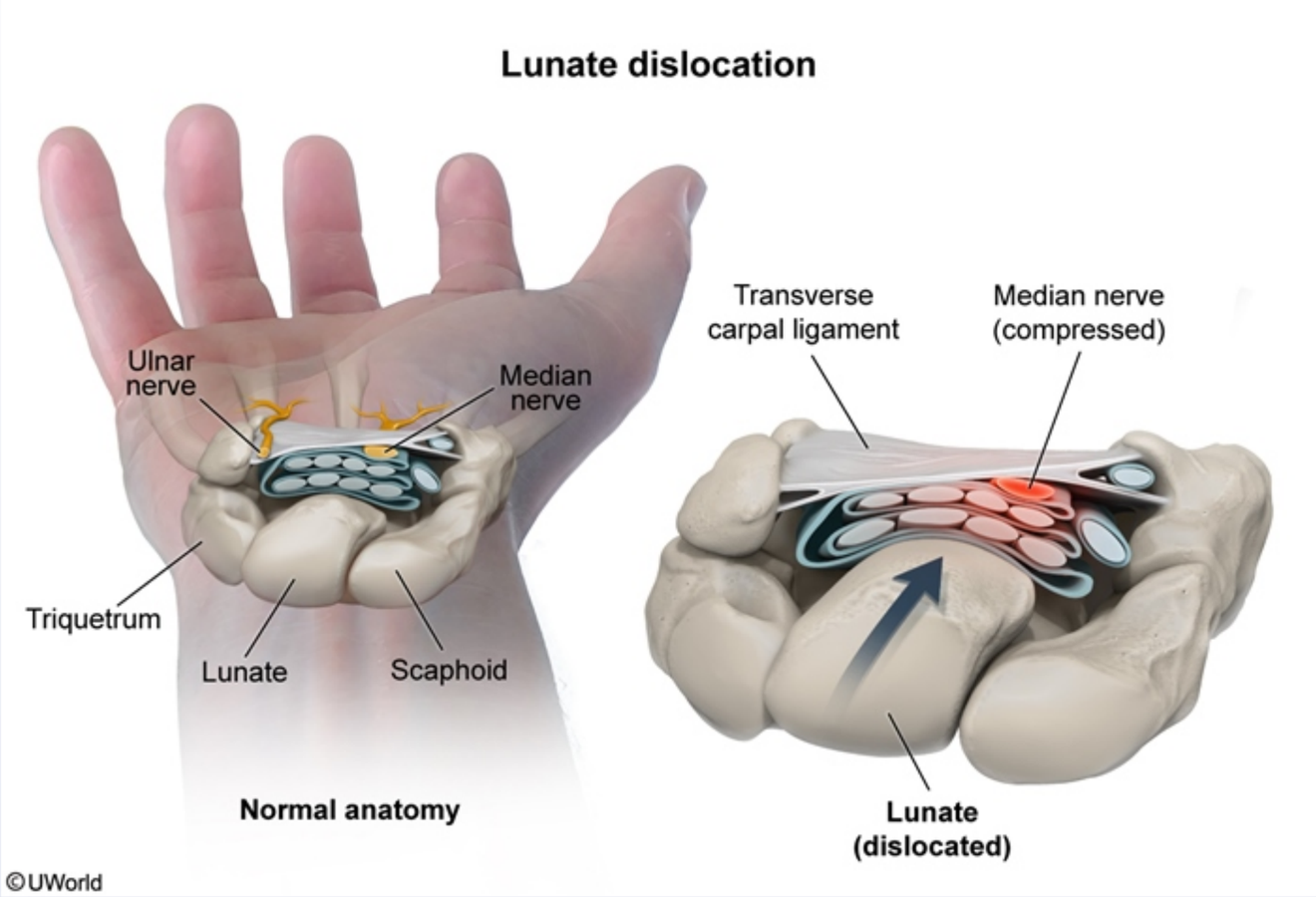

This patient who experienced a high-energy fall onto an outstretched hand now has a **volar lunate dislocation**, with the displaced lunate now palpable in the patient's proximal palm and visualized on lateral x-ray of the wrist ("spilled teacup" sign).

Lunate dislocation requires a high-energy force to disrupt the numerous ligaments (eg, scapholunate, capitolunate, lunotriquetral) that typically stabilize the lunate. When severe ligamentous injury occurs, the lunate can dislocate volarly from its normal position within the floor of the carpal

This patient who experienced a high-energy fall onto an outstretched hand now has a **volar lunate dislocation**, with the displaced lunate now palpable in the patient's proximal palm and visualized on lateral x-ray of the wrist ("spilled teacup" sign).

Lunate dislocation requires a high-energy force to disrupt the numerous ligaments (eg, scapholunate, capitolunate, lunotriquetral) that typically stabilize the lunate. When severe ligamentous injury occurs, the lunate can dislocate volarly from its normal position within the floor of the carpal tunnel and **compress** and/or injure the **median nerve**.

Median nerve injury at the level of the carpal tunnel may result in both sensory and **motor deficits** in the distribution of the median nerve's distal branches:

- Palmar digital branches: numbness, pain, and/or paresthesia in the palmar surface of the first 3½ digits; weakness of the first and second lumbrical muscles (interphalangeal joint extension)
- Recurrent branch of the median nerve to the **thenar muscles**: **weakness** of the abductor pollicis brevis (**thumb abduction**), flexor pollicis brevis (thumb flexion), and opponens pollicis (thumb opposition)

Prompt reduction of the dislocated lunate is required to prevent permanent damage to the median nerve.

(Choices A and D) The deep motor branch of the ulnar nerve is responsible for both finger abduction due to innervation of the dorsal and volar interossei and thumb adduction due to innervation of the adductor pollicis. The ulnar nerve is susceptible to acute compression at the wrist (ie, Guyon canal syndrome) when the hook of the hamate is fractured.

(Choice B) Branches of the median and ulnar nerves in the forearm innervate the flexor digitorum superficialis and profundus muscles that control finger interphalangeal joint flexion. These branches arise and innervate their respective muscles prior to the carpal tunnel and Guyon canal and would not be affected by wrist trauma.

(Choice E) The radial nerve innervates the extensor pollicis longus and brevis, which control thumb extension. All radial nerve–innervated muscles are located proximal to the wrist and therefore would not be affected by lunate dislocation.

Educational objective:
Volar dislocation of the lunate from its normal position within the floor of the carpal tunnel can cause median nerve compression and/or injury. Median nerve injury at the level of the carpal tunnel may result in weakness of thumb abduction, flexion, and opposition.

References

10
11
12
13
14
15
16
17
18
19
20
21
22
23
24
25
26
27
28
29
30
31
32
33
34
35
36
37
38
39
40

This patient who experienced a high energy fall onto an outstretched hand now has a **volar lunate dislocation**, with the displaced lunate now

Exhibit Display

Volar lunate dislocation

©UWorld

Zoom In
Zoom Out
Reset
Add To Flash Card

References

This patient who experienced a high energy fall onto an outstretched hand now has a **volar lunate dislocation**, with the displaced lunate now

Exhibit Display

Carpal tunnel, palmar view

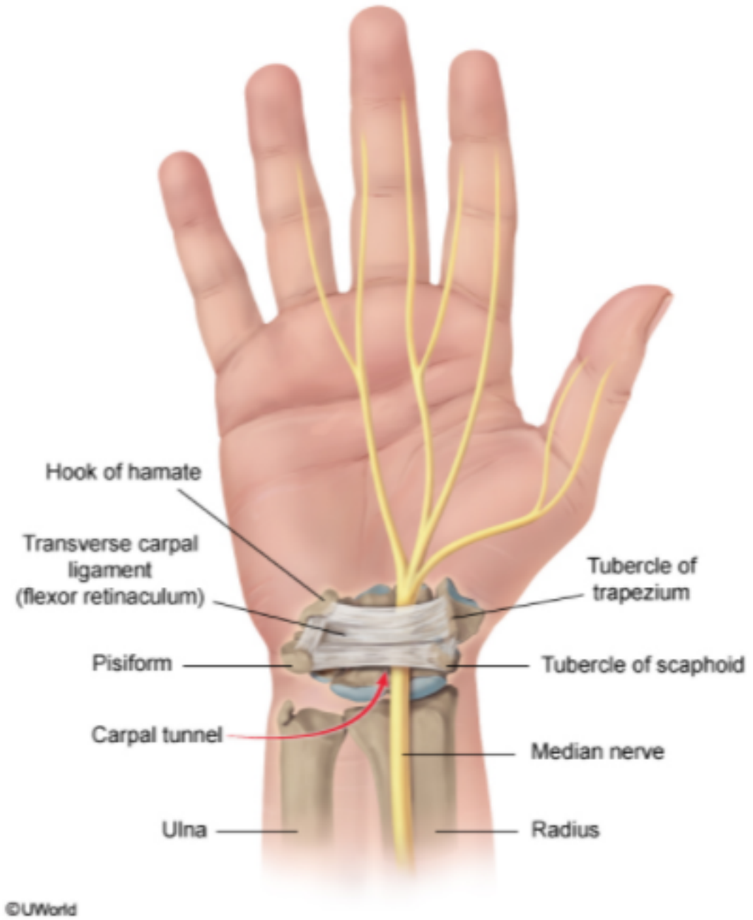

Zoom In Zoom Out Reset Add To Flash Card

References

10
11
12
13
14
15
16
17
18
19
20
21
22
23
24
25
26
27
28
29
30
31
32
33
34
35
36
37
38
39
40

This patient who experienced a high energy fall onto an outstretched hand now has a **volar lunate dislocation**, with the displaced lunate now

Exhibit Display

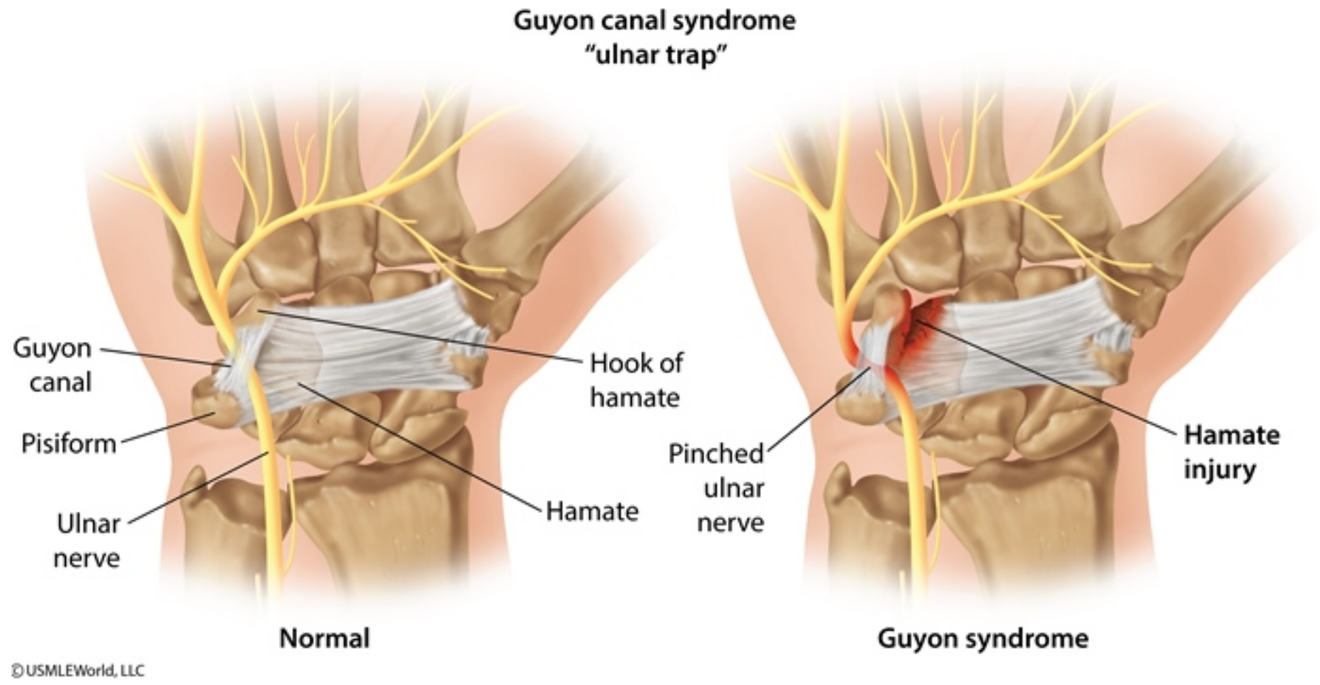

Zoom In Zoom Out Reset Add To Flash Card

References

10
11
12
13
14
15
16
17
18
19
20
21
22
23
24
25
26
27
28
29
30
31
32
33
34
35
36
37
38
39
40

- Palmar digital branches: numbness, pain, and/or paresthesia in the palmar surface of the first 3½ digits; weakness of the first and second lumbrical muscles (interphalangeal joint extension)
- Recurrent branch of the median nerve to the **thenar muscles**: **weakness** of the abductor pollicis brevis (**thumb abduction**), flexor pollicis brevis (thumb flexion), and opponens pollicis (thumb opposition)

Prompt reduction of the dislocated lunate is required to prevent permanent damage to the median nerve.

(Choices A and D) The deep motor branch of the ulnar nerve is responsible for both finger abduction due to innervation of the dorsal and volar interossei and thumb adduction due to innervation of the adductor pollicis. The ulnar nerve is susceptible to acute compression at the wrist (ie, Guyon canal syndrome) when the hook of the hamate is fractured.

(Choice B) Branches of the median and ulnar nerves in the forearm innervate the flexor digitorum superficialis and profundus muscles that control finger interphalangeal joint flexion. These branches arise and innervate their respective muscles prior to the carpal tunnel and Guyon canal and would not be affected by wrist trauma.

(Choice E) The radial nerve innervates the extensor pollicis longus and brevis, which control thumb extension. All radial nerve–innervated muscles are located proximal to the wrist and therefore would not be affected by lunate dislocation.

Educational objective:
Volar dislocation of the lunate from its normal position within the floor of the carpal tunnel can cause median nerve compression and/or injury. Median nerve injury at the level of the carpal tunnel may result in weakness of thumb abduction, flexion, and opposition.

References

- Lunate dislocation causing median nerve entrapment.
- Evaluation, management, and outcomes of lunate and perilunate dislocations.

Anatomy	Rheumatology/Orthopedics & Sports	Wrist injury
Subject	System	Topic

Copyright © UWorld. All rights reserved.